

Anchorless Labral Repair for Recurrent Shoulder Instability in the Skeletally Immature



Christopher E. Clinker, B.S., Peter N. Chalmers, M.D., and Anthony Romeo, M.D.

Abstract: The optimal treatment of recurrent shoulder instability in skeletally immature athletes remains controversial, especially if there is significant growth remaining. Some investigators advocate conservative treatment until patients are close to skeletal maturity, whereas others push for earlier surgery to avoid further damage. The objective of this technical note is to describe a technique for labral repair using an anchorless approach to avoid potential damage to the glenoid physis.

Shoulder instability is rare in skeletally immature patients but is becoming more common as more adolescent patients engage in organized sports at a younger age.^{1,2} Shoulder instability can be caused by an acute traumatic event or by chronic repetitive trauma.² Patients with such injuries can be divided into those who are skeletally immature and those who are skeletally mature. Although shoulder instability is becoming more common in young skeletally immature patients, there is still debate on the optimal treatment. Conventionally, conservative management has been recommended, with the rationale being that retraining and strengthening of the dynamic shoulder-stabilizing muscles can prevent instability recurrence.^{3,4} However, once instability is recurrent, there is very little evidence supporting this treatment.^{5,6} In younger patients, recurrence rates can be in excess of 70%. Recurrence further damages the shoulder, and thus, many investigators now advocate early surgery in at-risk populations.^{1,7-10}

Few data are available on shoulder instability in patients younger than 13 years.¹¹ The vast majority of studies have looked at either adult populations or adolescent populations that are skeletally mature or nearly skeletally immature.^{4,6,12,13} Treatment in these cases thus remains controversial because of concerns that common fixation methods used to repair the damaged glenohumeral joint, such as anchor fixation to bone, may disturb the normal growth and development of the glenoid. Thus, we present a technique to repair the labrum in skeletally immature patients without the use of anchors. Typically, arthroscopic labral repairs are performed using anchors placed into the bony rim of the glenoid. The glenoid physis may be damaged by drill preparation for anchor insertion, as well as anchor placement, potentially arresting glenoid growth. We present a technique to avoid damaging the growth plate by avoiding anchor use. This technique and concept can also be applied to the repair of symptomatic tears in the capsule or at the capsulolabral junction in skeletally immature patients.

From the University of Utah School of Medicine, Salt Lake City, Utah, U.S.A. (C.E.C., P.N.C.); and Duly Health and Care, Elmhurst, Illinois, U.S.A. (A.R.).

The authors report no conflicts of interest in the authorship and publication of this article. Full ICMJE author disclosure forms are available for this article online, as [supplementary material](#).

Received June 7, 2022; accepted August 2, 2022.

Address correspondence to Christopher E. Clinker, B.S., University of Utah Orthopaedic Center, 590 Wakara Way, Salt Lake City, UT 84108, U.S.A. E-mail: christopher.clinker@hsc.utah.edu

© 2022 THE AUTHORS. Published by Elsevier on behalf of the Arthroscopy Association of North America. This is an open access article under the CC BY-NC-ND license (<http://creativecommons.org/licenses/by-nc-nd/4.0/>).

2212-6287/22751

<https://doi.org/10.1016/j.eats.2022.08.005>

Patient Evaluation, Imaging, and Indications

In patients being evaluated for a possible labral tear, a detailed patient history should be obtained and a complete physical examination should be performed, including provocative instability testing. Additionally, magnetic resonance imaging should be conducted to evaluate for capsulolabral lesions and to identify other possible relevant pathologies.¹⁴ In the case of a confirmed labral tear in an adolescent patient with many years of growth left, an anchorless repair may be indicated. Diagnostic arthroscopy should be used to assess the quality of the glenoid rim and remaining

labrum as too little cartilage on the glenoid can lead to inadequate fixation of the labrum. During diagnostic arthroscopy, the capsule should also be assessed because splits within the capsule and at the capsulolabral junction can occur and should be repaired concomitantly.

Technique

The procedure is performed with the patient in the lateral decubitus position under general anesthesia (Video 1, Fig 1). Both gentle axial traction and abduction traction are used to suspend the arm and create separation between the humeral head and glenoid articular surfaces. Abduction traction is critical to fully visualize the inferior glenoid and inferior capsule, but the shoulder should be well padded to avoid brachial plexus injury.

First, a posterior portal is established 1 cm below the scapular spine in line with the glenohumeral joint, and the joint is insufflated with lactated Ringer solution at 50 mm of Hg. A diagnostic arthroscopy is performed, with full assessment of the chondral surfaces, labrum, capsule, biceps, and articular cuff attachments. An anterosuperior portal is then established by an outside-in approach just posterior to the biceps, at the superior aspect of the rotator interval, sufficiently medially so that the spinal needle placed for portal localization can reach the inferior glenoid. An anteroinferior portal is then established just superior to the subscapularis at the inferior aspect of the rotator interval via an outside-in approach, again in line with the joint such that the spinal needle can reach the posterior glenoid. The camera is placed in the anterosuperior cannula for the procedure. Finally, a 7-o'clock portal is placed 2 fingerbreadths posterolateral to the posterolateral corner of the acromion on a line from the Neviasser point to the

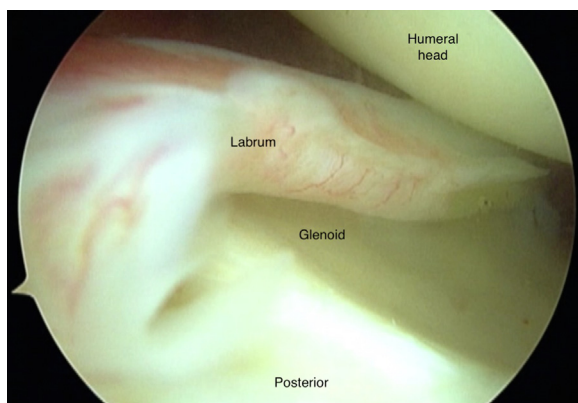


Fig 1. With the patient in the lateral decubitus position, viewing the left shoulder from the posterior portal, an inferior labral tear in a bucket-handle fashion is observed, with displacement into the joint.

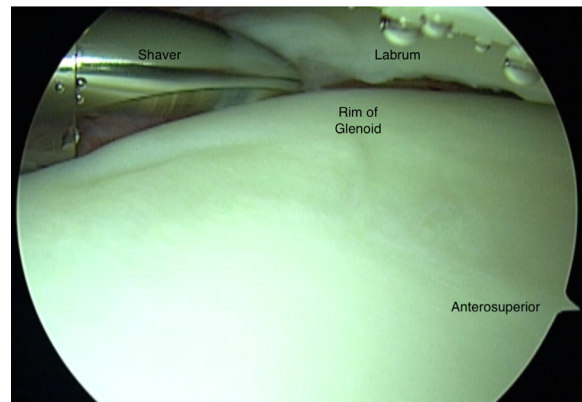


Fig 2. With the patient in the lateral decubitus position, viewing the left shoulder from the anterosuperior portal, preparation of the rim of the glenoid is performed with an arthroscopic shaver.

posterolateral acromion. Four 7-mm \times 7-cm cannulas (Arthrex, Naples, FL) are placed, one for each portal.

The labrum and capsule are then elevated, with the elevator placed in the anteroinferior cannula, with care taken not to create any splits within the labrum or capsule. This continues until the labrum and capsule can be easily reduced to the rim of the glenoid. The rim of the glenoid is conservatively abraded with a shaver and rasp to encourage healing (Figs 2 and 3). Starting posteriorly and working anteriorly, the surgeon should use a 45° curved suture hook (Spectrum; ConMed Linvatec, Utica, NY) to perform retrograde passage of a No. 2 braided absorbable suture through the capsule and the cartilaginous rim of the glenoid (Figs 4 and 5). Each pass through the cartilaginous rim should be sufficiently deep to avoid cutout as this is the “anchor” for the soft-tissue repair. This technique requires the use of simple sutures instead of mattress sutures to avoid cutout. Each suture is tied after passage, with the

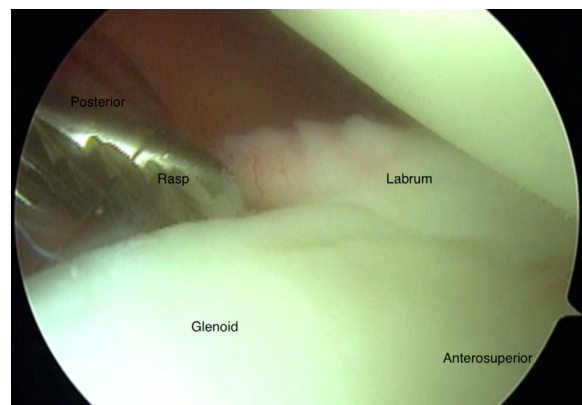


Fig 3. With the patient in the lateral decubitus position, viewing the left shoulder from the anterosuperior portal, preparation of the rim of the glenoid is performed with an arthroscopic rasp.

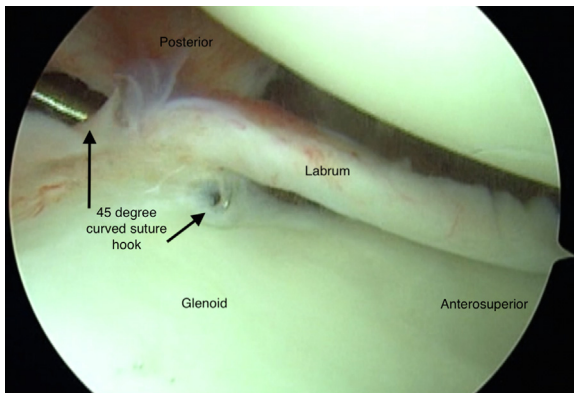


Fig 4. With the patient in the lateral decubitus position, viewing the left shoulder from the anterosuperior portal, a 45° curved suture hook is used for passage through the capsule and through the cartilaginous rim of the glenoid and around the labrum.

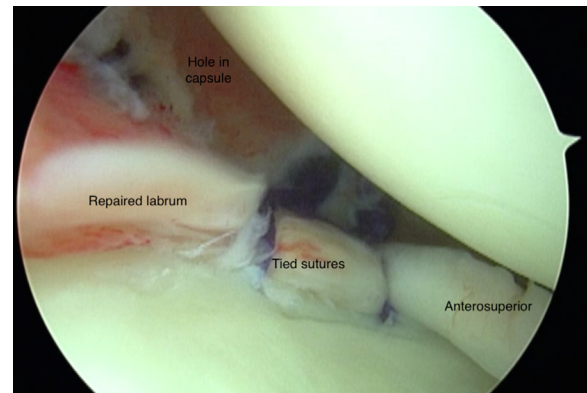


Fig 6. With the patient in the lateral decubitus position, viewing the left shoulder from the anterosuperior portal, the repaired posterior labrum can be appreciated.

labrum and capsule tensioned anteriorly, while the suture is tied to hold the reduction (Figs 6 and 7). As the repair progresses, the capsule is reassessed, and if the capsule is torn from the labrum and scarred medially along the neck, it should be elevated and incorporated into the labral repair to properly re-tension the glenohumeral ligaments and stabilize the shoulder (Fig 8). As the repair progresses anteriorly, the reverse suture hook direction can be used from the anteroinferior cannula to optimize the surgeon's ability to obtain the best bite of capsule and glenoid rim. For this technique, we typically place a minimum of 7 simple absorbable sutures. For instance, in Video 1, sutures are placed at the 8-, 7-, 6-, 5-, 4-, 3-, and 2-o'clock positions, re-establishing labral position, labral height, and capsular tension (Fig 9). Finally, to restore the normal anatomy of the capsule, the capsular holes made by the cannulas

are repaired using a "crescent" suture hook and a penetrating grasper.

Rehabilitation

The patient wears a sling for the first 4 weeks postoperatively. Range-of-motion exercises within a tension-free motion arc are permitted immediately postoperatively under the care of a physical therapist. Movement exercises can start with passive assisted range of motion for the first 4 weeks, followed by a transition to active-assisted motion and, finally, active range of motion. There are no range-of-motion restrictions, but rotation in abduction or flexion should be avoided until 3 months postoperatively. Strengthening can begin at 6 weeks postoperatively, progressing slowly from isometrics to bands to weights, with a focus on the rotator cuff, deltoid, and scapular stabilizers. Restoration of scapular rhythm and tracking should be prioritized. Eccentric, plyometric, proprioceptive, and sport-specific exercises can be initiated at 3 months.

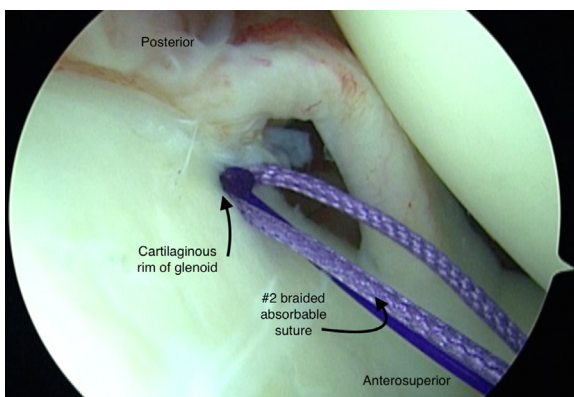


Fig 5. With the patient in the lateral decubitus position, viewing the left shoulder from the anterosuperior portal, retrograde passage of a No. 2 braided absorbable suture is performed through the capsule and through the cartilaginous rim of the glenoid in the left shoulder.

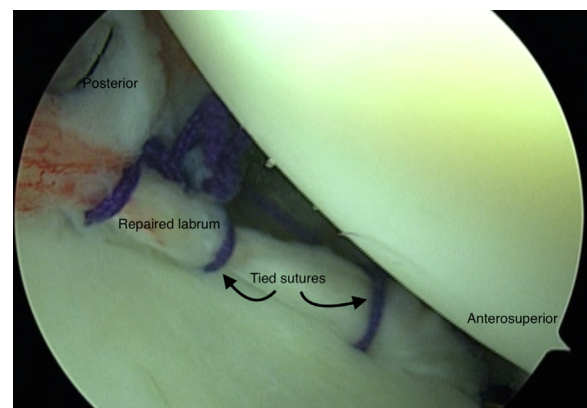


Fig 7. With the patient in the lateral decubitus position, viewing the left shoulder from the anterosuperior portal, the completed inferior labral repair can be appreciated.

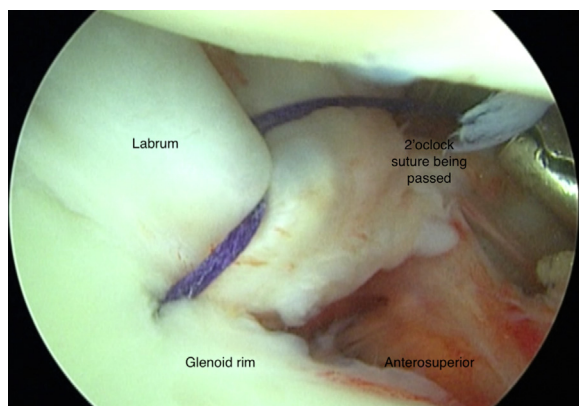


Fig 8. With the patient in the lateral decubitus position, viewing the left shoulder from the anterosuperior portal, repair of the superior aspect of the anterior labrum at the 2-o'clock position can be visualized.

Postoperative Course

Six months after the surgical procedure, the patient should recover full range of motion and strength and be able to return to all activities without pain or recurrence of instability symptoms. Advantages and disadvantages of our technique are presented in [Table 1](#), and pearls and pitfalls are listed in [Table 2](#).

Discussion

In this technical note, we describe an arthroscopic technique for repairing an inferior labral bucket-handle tear in a skeletally immature patient without the use of anchors. If surgical treatment is indicated because of recurrent episodes of instability in a skeletally immature patient, consideration could be given to using this technique.

In skeletally immature patients, damaging the physis may lead to skeletal deformity. Although anchors are commonly used in arthroscopic glenolabral repair, the

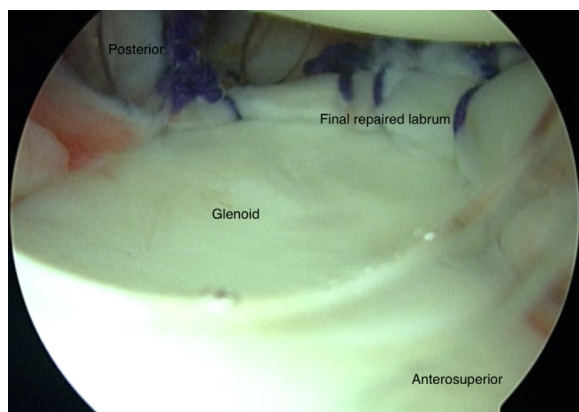


Fig 9. With the patient in the lateral decubitus position, viewing the left shoulder from the anterosuperior portal, the completed labral repair in the left shoulder can be appreciated.

Table 1. Advantages and Disadvantages

Advantages	
No drilling across physis	
No anchors, thus reducing cost, case complexity, and possibility of future anchor-related issues	
Ability to address capsular and labral pathology sequentially and separately	
Disadvantages	
Less secure glenoid fixation	
More time-intensive	
Requires piercing of chondral surface	
Repair limited to simple sutures	

angle of insertion of these anchors crosses the glenoid physis. However, the glenoid rim is more cartilaginous in younger individuals, which can provide the opportunity to use this tissue to anchor the torn labrum and capsule. By passing sutures through the capsule, labrum, and cartilage, a structurally solid repair without bone anchors can be performed in this age group.

Few studies have looked at labral repairs in skeletally immature patients. Most studies that have looked at labral repairs in younger patients have focused on adolescents in the 14- to 18-year-old range, in whom skeletal maturity has been achieved.^{4,11,13} However, in patients who are younger than 10 years—and thus have many years of skeletal growth remaining—and are significantly affected by recurrent episodes of instability, waiting to undergo operative treatment until skeletal maturity would subject them to years of shoulder dysfunction, instability, and potentially irreversible damage to the bone, cartilage, and labrum of the glenohumeral joint. Our technique allows repair

Table 2. Pearls and Pitfalls

Pearls	
Having a variety of suture-passing hooks available allows the surgeon to best address each area of the labrum with the optimal angle of passage.	
A 7-o'clock portal, or posteroinferior portal, offers the optimal approach for addressing posteroinferior labral pathology.	
A No. 2 braided absorbable suture provides the highest tensile strength among the available absorbable sutures and is tied with the lowest-profile knot stack.	
In adolescent patients, during diagnostic arthroscopy, the surgeon should assess the capsule thoroughly because splits within the capsule and at the capsulolabral junction can occur.	
Pitfalls	
The surgeon should avoid excessive preparation with the shaver on the labral side because this can reduce the amount of tissue available for repair.	
Missing a capsular tear can lead to inadequate capsular tensioning or incomplete repair of the capsulolabral-ligamentous junction.	
Capturing too little cartilage on the glenoid side can lead to inadequate fixation.	
Too few portals can lead to an inability to access the entire labrum and capsule or an inability to visualize the entirety of the pathology.	
Poor patient positioning can lead to poor visualization.	

and successful resolution of instability while mitigating the risk of damage to the physis and therefore should be considered in skeletally immature patients with recurrent shoulder instability.

References

1. Castagna A, Delle Rose G, Borroni M, et al. Arthroscopic stabilization of the shoulder in adolescent athletes participating in overhead or contact sports. *Arthroscopy* 2012;28:309-315.
2. Zacchilli MA, Owens BD. Epidemiology of shoulder dislocations presenting to emergency departments in the United States. *J Bone Joint Surg Am* 2010;92:542-549.
3. Li Xinning, Ma R, Nielsen NM, Gulotta LV, Dines JS, Owens BD. Management of shoulder instability in the skeletally immature patient. *J Am Acad Orthop Surg* 2013;21:529-537.
4. Lin KM, James EW, Spitzer E, Fabricant PD. Pediatric and adolescent anterior shoulder instability: Clinical management of first-time dislocators. *Curr Opin Pediatr* 2018;30:49-56.
5. Longo UG, Rizzello G, Loppini M, et al. Multidirectional instability of the shoulder: A systematic review. *Arthroscopy* 2015;31:2431-2443.
6. Warby SA, Pizzari T, Ford JJ, Hahne AJ, Watson L. Exercise-based management versus surgery for multidirectional instability of the glenohumeral joint: A systematic review. *Br J Sports Med* 2016;50:1115-1123.
7. DeFroda S, McGlone P, Levins J, O'Donnell R, Cruz AI, Kriz PK. Shoulder and elbow injuries in the adolescent throwing athlete. *R I Med J (2013)* 2020;103:21-29.
8. Franklin CC, Weiss JM. The natural history of pediatric and adolescent shoulder dislocation. *J Pediatr Orthop* 2019;39:S50-S52.
9. Roberts SB, Beattie N, McNiven ND, Robinson CM. The natural history of primary anterior dislocation of the glenohumeral joint in adolescence. *Bone Joint J* 2015;97-B:520-526.
10. Gigis I, Heikenfeld R, Kapinas A, Listringhaus R, Godolias G. Arthroscopic versus conservative treatment of first anterior dislocation of the shoulder in adolescents. *J Pediatr Orthop* 2014;34:421-425.
11. Jones KJ, Wiesel B, Ganley TJ, Wells L. Functional outcomes of early arthroscopic Bankart repair in adolescents aged 11 to 18 years. *J Pediatr Orthop* 2007;27:209-213.
12. Watson L, Balster S, Lenssen R, Hoy G, Pizzari T. The effects of a conservative rehabilitation program for multidirectional instability of the shoulder. *J Shoulder Elbow Surg* 2018;27:104-111.
13. Kramer J, Gajudo G, Pandya NK. Risk of recurrent instability after arthroscopic stabilization for shoulder instability in adolescent patients. *Orthop J Sports Med* 2019;7:2325967119868995.
14. Simon MJK, Regan WD. Utilization of MRI in surgical decision making in the shoulder. *BMC Musculoskelet Disord* 2022;23:588.