

Migrating Lobar Atelectasis of the Right Lung: Radiologic Findings in Six Patients

Tae Sung Kim, MD
Kyung Soo Lee, MD
Jung Hwa Hwang, MD
In Wook Choo, MD
Jae Hoon Lim, MD

Index words:
Lung, collapse
Lung, diseases
Lung, radiography

Korean J Radiol 2000; 1: 33-37
Received October 19, 1999; accepted
after revision February 9, 2000.

All authors: Department of Radiology,
Samsung Medical Center, Sungkyunkwan
University School of Medicine.

Address reprint requests to:
Kyung Soo Lee, MD, Department of
Radiology, Samsung Medical Center,
Sungkyunkwan University School of
Medicine, 50, Ilwon-Dong, Kangnam-Gu,
Seoul 135-710, Korea.
Telephone: (822) 3410-2511, 2518
Fax: (822) 3410-2559
e-mail: kslee@smc.samsung.co.kr

Objective: To describe the radiologic findings of migrating lobar atelectasis of the right lung.

Materials and Methods: Chest radiographs (n = 6) and CT scans (n = 5) of six patients with migrating lobar atelectasis of the right lung were analyzed retrospectively. The underlying diseases associated with lobar atelectasis were bronchogenic carcinoma (n = 4), bronchial tuberculosis (n = 1), and tracheobronchial amyloidosis (n = 1).

Results: Atelectasis involved the right upper lobe (RUL) (n = 3) and both the RUL and right middle lobe (RML) (n = 3). On supine anteroposterior radiographs (n = 5) and on an erect posteroanterior radiograph (n = 1), the atelectatic lobe(s) occupied the right upper lung zone, with a wedge shape abutting onto the right mediastinal border. On erect posteroanterior radiographs (n = 6), the heavy atelectatic lobe(s) migrated downward, forming a peri- or infra hilar area of increased opacity and obscuring the right cardiac margin. Erect lateral radiographs (n = 4) showed inferior shift of the anterosuperiorly located atelectatic lobe(s) to the anteroinferior portion of the hemithorax.

Conclusion: Atelectatic lobe(s) can move within the hemithorax according to changes in a patient's position. This process involves the RUL or both the RUL and RML.

Heitzman (1) suggested that very heavy lobes, when filled with fluid, pneumonic consolidation, or tumor, might migrate within the hemithorax with changes in the body position, adopting a dependent position. Since Heitzman's suggestion, a few cases of migration of a heavy atelectatic lobe have been reported (2, 3). Lobar migration is a shifting process within a hemithorax. The appearance of migration of an atelectatic lobe may mimic that of lung torsion (4-11), although the differential radiologic findings have not been described. Nor is it clear from the literature whether migration of an atelectatic lobe has been considered synonymous with lobar torsion (4-6).

Between 1987 and 1996 we encountered six cases of migrating lobar atelectasis of the right lung without clinical or radiologic evidence of lobar torsion. The aim of this study is to describe the radiological findings of migrating lobar atelectasis of the right lung.

MATERIALS AND METHODS

In six cases of migrating lobar atelectasis of the right lung, the radiologic findings were analyzed. The patients were two men and four women aged between 29 and 87

(mean, 59) years. Underlying diseases were bronchogenic carcinoma (n = 4), the fibrotic stage of bronchial tuberculosis (n = 1), and tracheobronchial amyloidosis (n = 1), and were confirmed by bronchoscopic biopsy (n = 5) and cytologic examination of the pleural fluid (n = 1). In two patients, open thoracotomy was performed for surgical resection of bronchogenic carcinoma. During surgery, no evidence of lobar torsion was found, and the right major and minor fissures were complete.

For these six patients, erect posteroanterior (PA) (n = 7), supine anteroposterior (AP) (n = 5), erect lateral (n = 4), supine cross-table lateral (n = 2) chest radiographs, and chest CT scans (n = 5) were available. In one patient, migrating atelectasis was seen on a follow-up erect PA chest radiograph obtained two days after the initial erect PA radiograph; migration was observed in the erect position. In one other, in order to confirm migration, fluoroscopic examination of the thorax was performed just after obtaining the chest radiographs. In all six patients, chest radiographs were obtained with the patients in different position (same position in one) within three days of initial radiography. Chest radiographs and CT scans were obtained within ten days.

Chest radiographs and CT scans were retrospectively analyzed by two chest radiologists, who reached a consensus. On radiographs, position of the atelectatic lobes, orientation of the interlobar fissures, hilar size, branching pattern of the hilar vessels, and bronchial changes were analyzed. Additional findings, if any, were also recorded. CT scans

were examined for possible causes of atelectasis, and the presence or absence of hilar or mediastinal adenopathy were confirmed.

RESULTS

The right upper lobe (RUL) (n = 3) and both the RUL and right middle lobe (RML) (n = 3) were atelectatic.

On supine AP radiographs (n = 5) and on an erect posteroanterior radiograph (n = 1), the atelectatic lobe(s) occupied the right upper lung zone with an inverted wedge shape abutting onto the right mediastinal border and the apex of the hemithorax (Figs. 1, 2). On erect PA radiographs (n = 6), the heavy lobe(s) were seen to have migrated downward, forming a peri- or infrahilar area of increased opacity and obscuring the right cardiac margin (Figs. 1, 2). Migration was observed in one patient on a follow-up erect radiograph, which had not previously been noted on a radiograph of this same type.

On supine cross-table lateral radiographs (n = 2), the atelectatic lobe(s) were seen in the anterosuperior portion of the thorax. Erect lateral radiographs (n = 4) showed inferior shift of the anterosuperiorly located atelectatic lobe(s) to the anteroinferior portion of the hemithorax.

In all patients, small right hilar size and displacement or splaying of the right hilar vessels were seen on both erect PA radiographs and/or supine AP radiographs. Fluoroscopic examination, performed in one patient, showed that the position of the atelectatic lobe had changed (Fig. 3). In

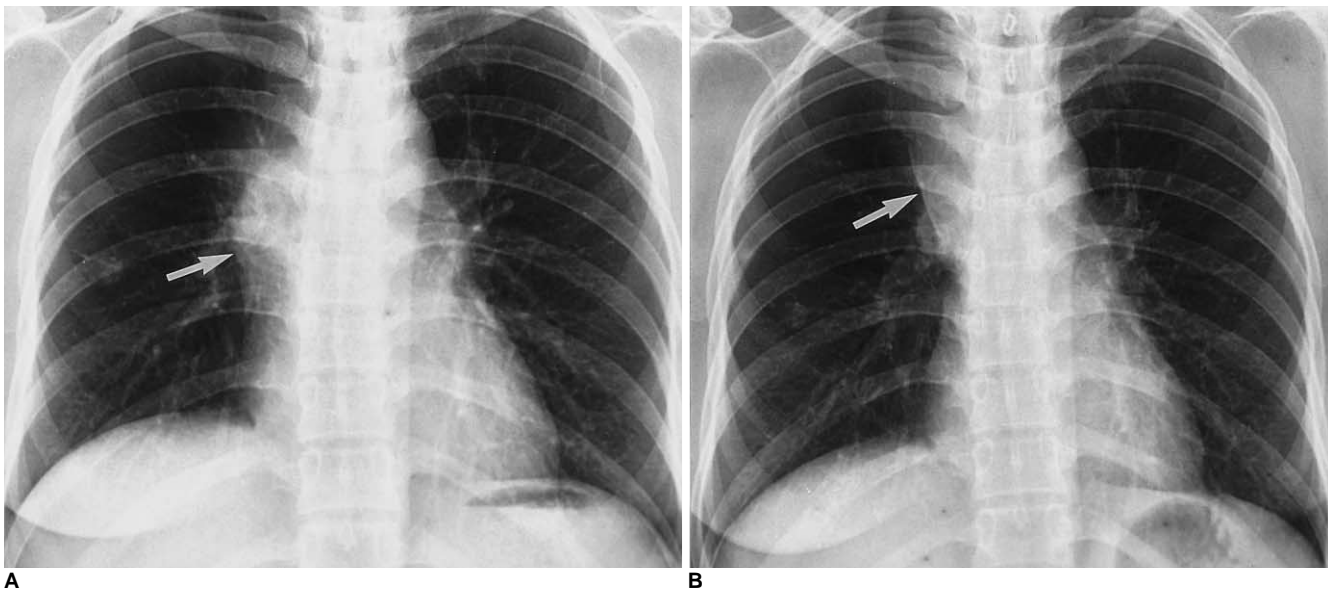


Fig. 1. Migrating right upper lobar atelectasis caused by tuberculous bronchostenosis in a 29-year-old female.

A. Erect posteroanterior chest radiograph obtained on admission shows increased opacity in the right hilar area obscuring the right cardiac margin (arrow).

B. Erect posteroanterior radiograph obtained two days later shows migration of the opacity to upper lung zone, with a wedge shape (arrow).

Migrating Lobar Atelectasis of Right Lung

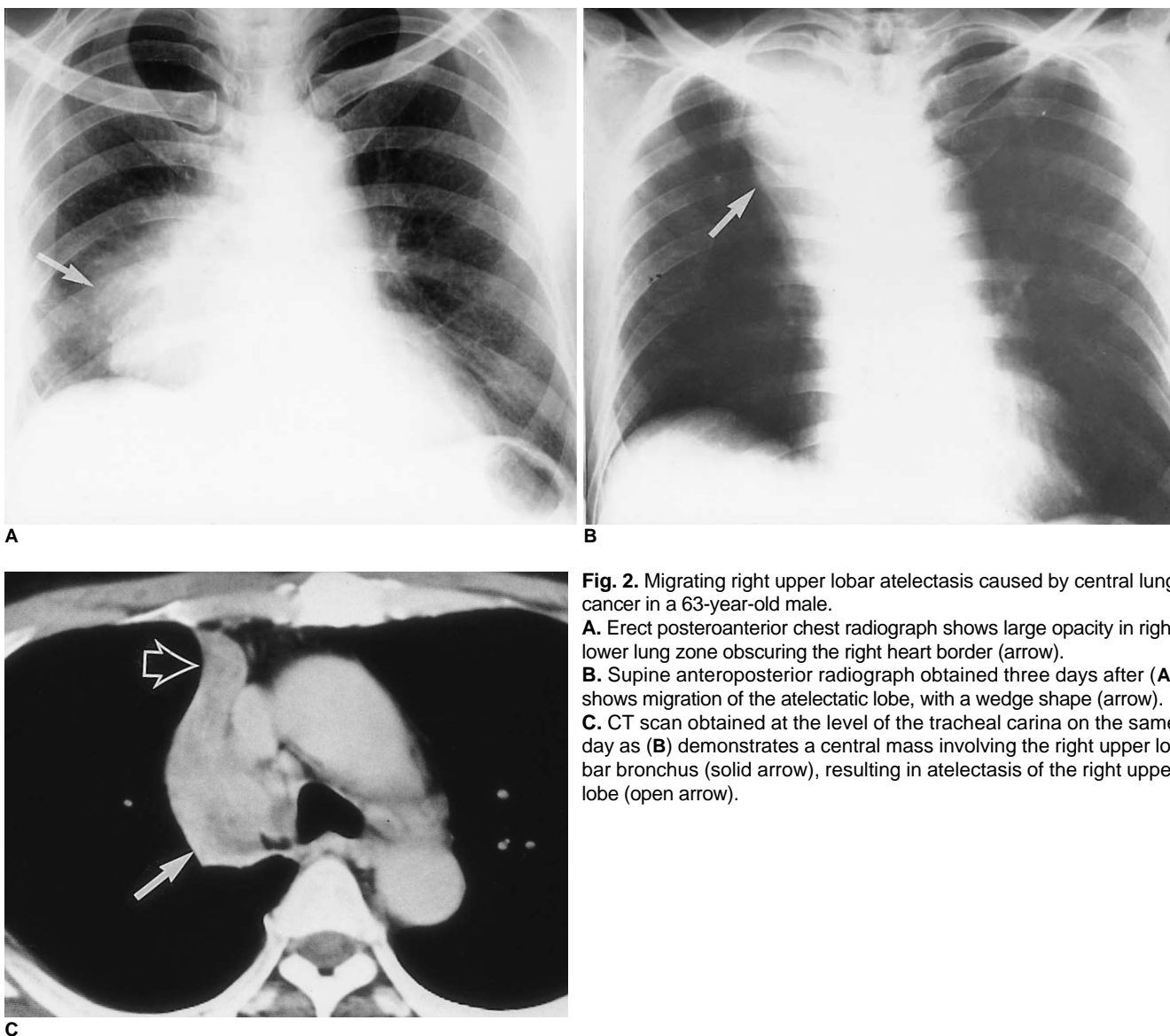


Fig. 2. Migrating right upper lobar atelectasis caused by central lung cancer in a 63-year-old male.

A. Erect posteroanterior chest radiograph shows large opacity in right lower lung zone obscuring the right heart border (arrow).

B. Supine anteroposterior radiograph obtained three days after (A) shows migration of the atelectatic lobe, with a wedge shape (arrow).

C. CT scan obtained at the level of the tracheal carina on the same day as (B) demonstrates a central mass involving the right upper lobar bronchus (solid arrow), resulting in atelectasis of the right upper lobe (open arrow).

two patients, right pleural effusion was seen.

Because all CT scans were obtained with patients in the supine position, dynamic changes in lobar migration could not be demonstrated on CT as they could on chest radiographs obtained in different positions. In all patients, CT scans ($n = 5$) demonstrated findings related to the causes of atelectasis as well as the atelectatic lobe(s) per se.

DISCUSSION

Findings of migrating RUL (right upper lobe) or combined RUL and RML (right middle lobe) atelectasis in our six patients were as follows: (1) on supine anterosuperior radiographs the atelectatic lobe(s) occupied the right upper lung zone, and a wedge shape abutting onto the right mediastinal border. This is a usual manifestation of RUL or

combined RUL and RML atelectasis; (2) in an erect position, the heavy lobe(s) migrated downward, forming a peri- or infrahilar area of increased opacity obscuring the right cardiac margin and sometimes mimicking a RML lesion or an anterior mediastinal mass; (3) an erect lateral radiograph showed inferior shift of the RUL or both RUL and RML to the anteroinferior portion of the hemithorax, which had been located anterosuperiorly on a supine cross-table lateral radiograph.

Migrating lobar atelectasis per se may have no radiologic significance. When a lobe or lobes are migrating and occupying a dependent position on erect posteroanterior and lateral radiographs, however, the atelectatic lobe(s) can mimic a lesion in the RML or a hilar or mediastinal mass. In this condition, if lobar atelectasis is to be diagnosed, secondary findings such as a small displaced hilum, splaying of

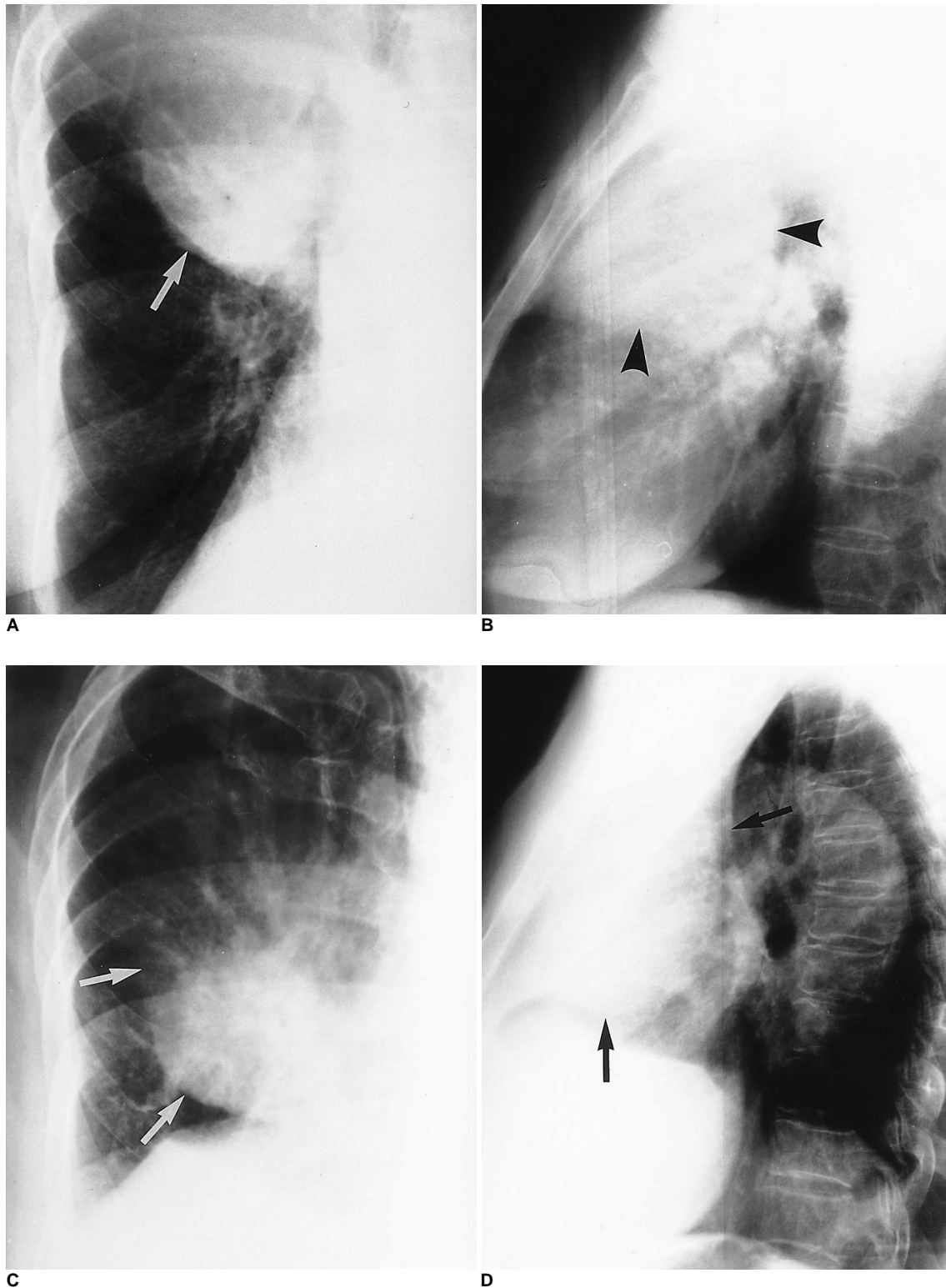


Fig. 3. Migration of combined right upper and middle lobes atelectasis caused by central lung cancer in an 87-year-old female.
A. Spot radiograph obtained in supine position during fluoroscopy shows opacity in right upper and middle lung zone obliterating the right cardiac margin (arrow), suggestive of combined atelectasis of the right upper and middle lobes.
B. Supine cross-table lateral radiograph shows a large opacity occupying the anterosuperior portion (arrowheads).
C. Spot radiograph obtained in erect position during fluoroscopy just after (A) shows the descent of heavy atelectatic lobes to the right lower lung zone (arrows).
D. Subsequent erect lateral radiograph shows that the opacity has changed its position, now occupying the anteroinferior portion of the right hemithorax (arrows).

Migrating Lobar Atelectasis of Right Lung

the pulmonary vasculature, and oligemia of the ipsilateral lung should be sought.

Lobar migration is a shifting process within the hemithorax, while lobar torsion is a rotatory or twisting process around its pedicle (bronchovascular bundle). It has been suggested, however, that lobar migration indicates torsion (4-6). As far as lobar torsion is concerned, the most commonly related conditions are previous surgery and trauma (8). In post-traumatic and postoperative torsion, clinical signs are often attributable to torsion and ensuing lobar infarction. Air leak, shock, sepsis, and deterioration of the patient may appear abruptly and progress rapidly (4). Despite migration in our cases, none of the six patients had symptoms suggestive of lobar torsion. Because spontaneous torsion itself is, in fact, seldom symptomatic (12), it may, however, be dangerous to differentiate simple migration from torsion merely on the basis of symptoms and signs.

In summary, migrating lobar atelectasis of the right lung usually involves the RUL or both the RUL and RML. On supine AP radiographs, the right upper lung zone is occupied by the atelectatic lobe(s), which form a wedge shape. On erect PA radiographs, the heavy lobe(s) are seen to migrate downward to form a peri- or infrahilar area of increased opacity obscuring the right cardiac margin. Recognition of the presence of simple migrating lobar atelectasis without torsion should preclude unnecessary emergency surgery.

References

1. Heitzman ER. *The lung: Radiologic-pathologic correlation*. 2nd ed. St. Louis: Mosby-Year Book, 1984:457-501
2. Lee KS, Logan PM, Primack SL, Müller NL. Combined lobar atelectasis of the right lung: imaging findings. *AJR* 1994;163:43-47
3. Lee KS, Ahn JM, Im J-G, Müller NL. Lobar atelectasis: typical and atypical radiographic and CT findings. *Postgrad Radiol* 1995;15:203-217
4. Felson B. Lung torsion: radiographic findings in nine cases. *Radiology* 1987;162:631-638
5. Graham RJ, Heyd RL, Raval VA, Barrett TF. Lung torsion after percutaneous needle biopsy of lung. *AJR* 1992;159:35-37
6. Meisell R. Case of the spring season: right upper lobe collapse with lobar torsion. *Semin Roentgenol* 1980;15:115-116
7. Huang T-Y, Cho S-R. Torsion of the lung without trauma. *Radiology* 1979;132:25-26
8. Moser Jr. ES, Proto AV. Lung torsion: case report and literature review. *Radiology* 1987;162:639-643
9. Berkmen YM, Yankelevitz D, Davis SD, Zanzonico P. Torsion of the upper lobe in pneumothorax. *Radiology* 1989;173:447-449
10. Pinstein ML, Winer-Muram H, Eastridge C, Scott R. Middle lobe torsion following right upper lobectomy. *Radiology* 1985;155:580
11. Munk PL, Vellet AD, Zwirewich C. Torsion of the upper lobe of the lung after surgery: findings on pulmonary angiography. *AJR* 1991;157:471-472
12. Ransdell HT Jr., Ellison RG. Volvulus of a lobe of the lung as a complication of diaphragmatic hernia: a case report. *J Thorac Surg* 1953;25:341-345