

# Double Spiral Dupuytren's Disease: Case of Ulnar and Radial Spiral Cords in Shared Digit

Jamie Kator, BA\*  
 Rohan Gopinath, MD\*†  
 Nathan Miller, MD\*†  
 Raymond Pency, MD\*†

**Summary:** Dupuytren's disease is a benign fibroproliferative disorder resulting in progressive contraction of palmar and digital fascia. Diseased fascia of the hand condenses into tensile cords, manifesting in various anatomical combinations. The spiral cord variant is especially troublesome, as the cord travels under the digital neurovascular bundle and places it at risk during surgical resection. In severe cases, limited fasciectomy is required to release contracture and restore finger extension. Here, we present the case of a 79-year-old right-handed man with a history of severe Dupuytren's disease of both hands, who was found to have *ulnar* and *radial* spiral cords in his right ring finger. Diseased tissue was removed en bloc, restoring extension and function. To our knowledge, this is the first case of a digit with two spiral cords affecting both neurovascular bundles. It is important to be aware of the anatomical variations possible in Dupuytren's disease to avoid iatrogenic injury. (*Plast Reconstr Surg Glob Open* 2020;8:e3212; doi: [10.1097/GOX.0000000000003212](https://doi.org/10.1097/GOX.0000000000003212); Published online 28 October 2020.)

## INTRODUCTION

Dupuytren's disease is a relatively common fibroproliferative disorder resulting in significant disability. The incidence in the United States alone is estimated at 3 per 10,000 per year, with higher incidences reported in Europe and in other populations.<sup>1</sup> Dupuytren's disease is characterized by benign proliferation of fibrous tissue in the palmar and digital fascial structures. Fibrosis of these structures leads to progressive joint and skin contracture, resulting in digital flexion contracture, loss of grip strength, and limitations with activities of daily living. Although there appears to be a genetic component to the disease, as it is especially common in white males of northern European descent, the exact etiology remains unknown. Treatment of contractures may involve fasciotomy or fasciectomy of diseased tissue to relieve joint stress and restore extension. In cases with extreme joint contracture of the proximal interphalangeal joint (PIP), a two-stage approach is often utilized with preoperative application of a dynamic joint fixator (Digit Widget, Hand Biomechanics Lab, Inc., Sacramento, Calif.). The Digit

Widget applies external torque to the contracted joint, progressively relieving flexion contracture to optimize operative access to the diseased fascia.<sup>2</sup>

The fascial anatomy of Dupuytren's disease is complex, with many structures susceptible to cord formation. In 1974, McFarlane described the multitude of patterns of pathologic fascial involvement seen in Dupuytren's, and their relation to the digital neurovascular bundle.<sup>3</sup> One pattern of fascial involvement, the spiral cord, is especially troublesome to patients and surgeons. The spiral cord is composed of fibrous thickening of the spiral band, Grayson's ligament, and the lateral digital sheet, with the pretendinous band as a proximal anchor. This cord of fibrotic fascia causes contracture of the metacarpophalangeal and proximal interphalangeal joints. As the cord tightens with progression of the disease, the neurovascular bundle of the digit becomes entrapped and is pulled toward the midline of the digit, spiraling around the thickened cord. Given the aberrant location of the neurovascular bundles, surgeons must be mindful not to injure these critical structures during limited fasciectomy. Additionally, the tension on the neurovascular bundle may result in a digital sensory neuropathy of the affected digit.<sup>4</sup> Typically, cords occur in isolation within a digit, compromising the radial or ulnar neurovascular bundle, but not both. However, in this report, we present the case of a patient with severe Dupuytren's contracture found to have two spiral cords in 1 digit: jeopardizing both the ulnar and radial neurovascular bundle.

From the \*Department of Orthopaedic Surgery, University of Maryland School of Medicine, Baltimore, Md.; and †R Adams Cowley Shock Trauma Center, Department of Orthopaedics, Baltimore, Md.

Received for publication August 9, 2020; accepted September 1, 2020.

Copyright © 2020 The Authors. Published by Wolters Kluwer Health, Inc. on behalf of The American Society of Plastic Surgeons. This is an open-access article distributed under the terms of the [Creative Commons Attribution-Non Commercial-No Derivatives License 4.0 \(CCBY-NC-ND\)](https://creativecommons.org/licenses/by-nc-nd/4.0/), where it is permissible to download and share the work provided it is properly cited. The work cannot be changed in any way or used commercially without permission from the journal.

DOI: [10.1097/GOX.0000000000003212](https://doi.org/10.1097/GOX.0000000000003212)

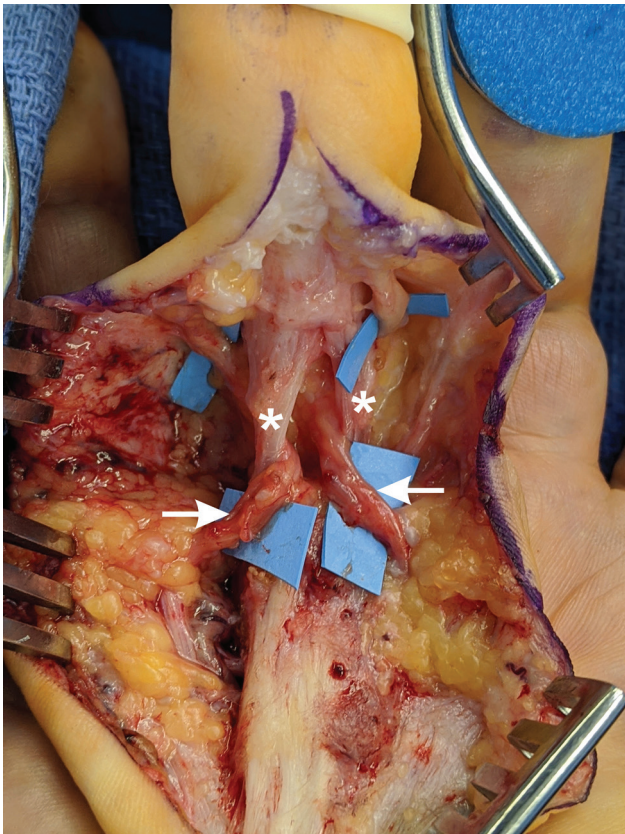
**Disclosure:** The authors have no conflicts of interest or funding to disclose. This research received no specific grant from any funding agency in the public, commercial, or not-for-profit sectors.

### CASE REPORT

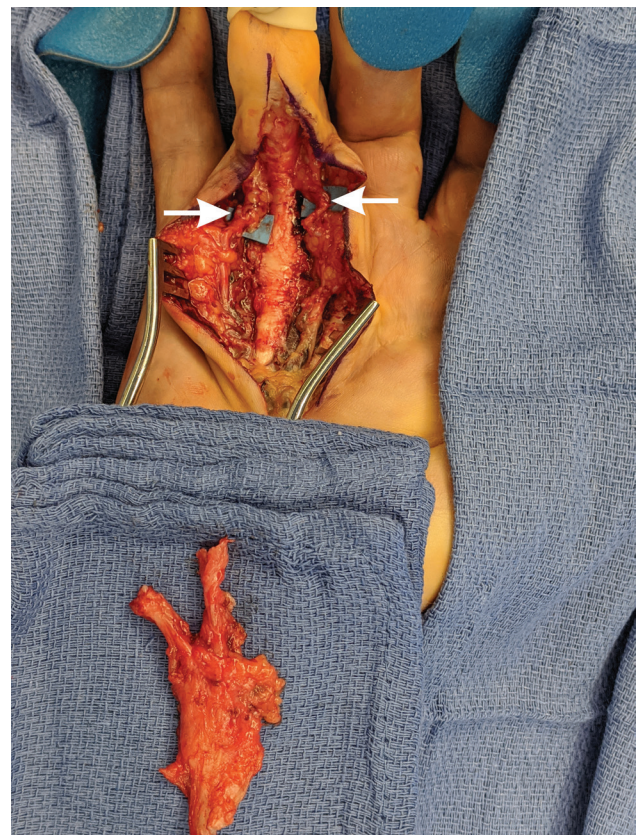
A 79-year-old right-handed man of Northern European descent with a history of HTN, BPH, and bilateral Dupuytren's disease presented to our practice for treatment options. His prior treatments included limited fasciectomy approximately 3 years ago of the left ring finger at an outside hospital. Additionally, he underwent needle aponeurotomy of the right small finger. Most recently he underwent Xiaflex injections into the right ring finger; however, he had recurrence of deformity, which prompted him to seek care at our practice. His chief complaint was inability to shake hands, given the severity of right ring finger contracture, which measured over 110 degrees at the time. A staged approach was planned with the application of a dynamic joint fixator (Digit Widget, Hand Biomechanics Lab, Inc., Sacramento, Calif.) to the right ring finger 10 weeks before surgery. Despite strict adherence and steady increases in the resistance provided by the Digit Widget, the PIP contracture was improved only by 20 degrees to 90 degrees at the time of fasciectomy.

The patient was taken to the operating room for limited fasciectomy and surgical release of Dupuytren's cord of the right ring finger. A linear incision was used along the longitudinal axis of the ring finger. Full thickness skin flaps were elevated off the diseased fascial tissues. The

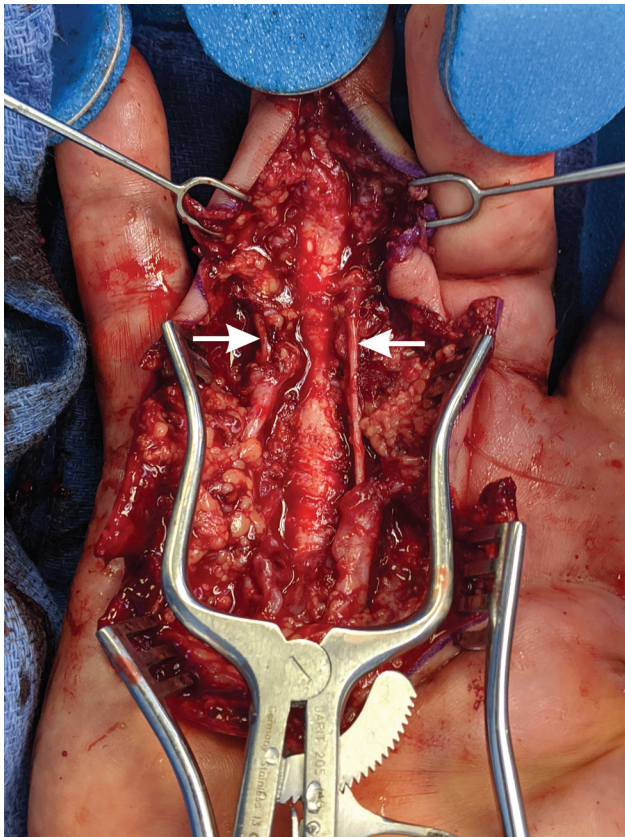
pretendinous cord was identified in the palm, as were the common digital arteries and nerves of the fourth and third web spaces. The ulnar neurovascular bundle was traced distally, revealing a discrete and dense ulnar cord encompassing the typical pretendinous band, spiral band, lateral digital sheath, and Grayson's ligament. This created a spiral cord about the ulnar neurovascular bundle of the ring finger. With careful dissection, the ulnar neurovascular bundle was isolated proximal to the fourth webspace and distally to the level of the distal interphalangeal joint. Having isolated this spiral cord and its associated neurovascular bundle, the radial neurovascular bundle was next identified. Similarly, it was involved in a spiral cord. This discrete and separate spiral cord had formed along the radial ring finger, although less hypertrophic than the ulnar cord. This cord was similarly isolated without injury to the neurovascular bundle on the radial side of the digit (Fig. 1). Both spiral cords and the shared pretendinous cord were then excised in their entirety without any violation of the pulley sheath of the ring finger (Figs. 2,3). Z-plasties at the PIP, MP, and distal palmar crease were performed to achieve full extension of the PIP and MP. After z-plasties were performed, the tourniquet was deflated, hemostasis achieved, and the finger was noted to have good capillary refill distally. The Z-plasties were transposed and secured with interrupted sutures. A sterile surgical dressing was applied, and the hand splinted with the ring and small fingers in full extension.



**Fig. 1.** Palmar aspect of the right hand shown with digits oriented ulnar to radial. The ulnar and radial neurovascular bundles (arrows) have been isolated and are shown entangled in two distinct spiral cords (asterisks).



**Fig. 2.** Excised tissue removed en bloc, with preservation of neurovascular bundles (arrows).



**Fig. 3.** Post-excision anatomy after release of tourniquet demonstrating preservation of the flexor mechanism and non-diseased structures of the digit, including both neurovascular bundles (arrows).

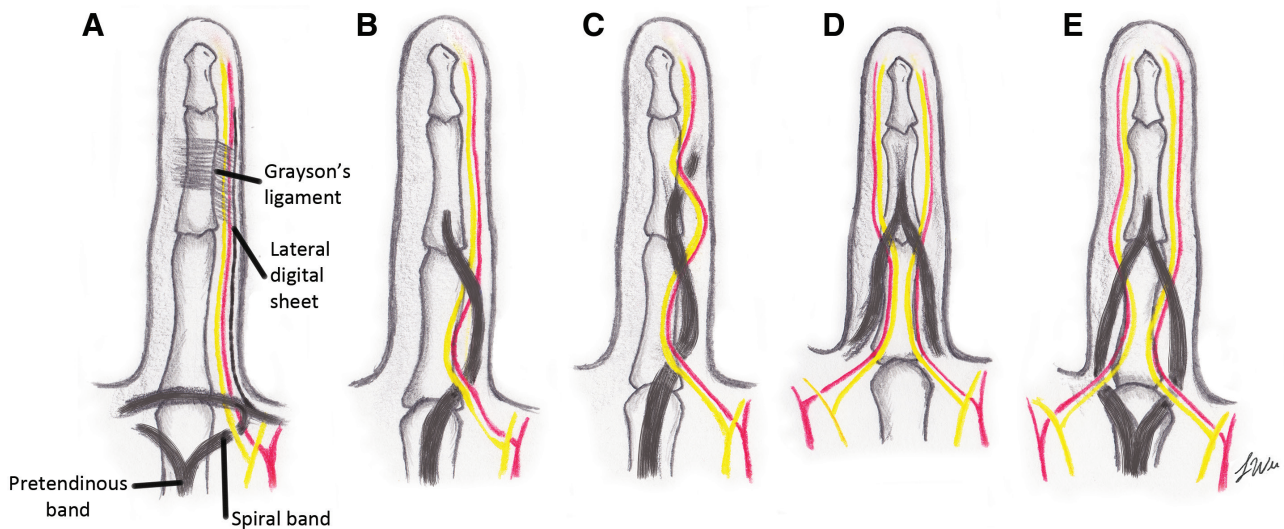
He was seen 1 week following surgery, at which time the incision was clean and intact, and the finger was noted to have excellent capillary refill. At 6 weeks post-operatively,

the patient's incisions continued to be healing well and he was sensate at the fingertips with good perfusion. He continues to work diligently with occupational therapy and has regained function in his daily activities, including shaking hands.

### DISCUSSION

The anatomical variations of Dupuytren's disease have been well documented and characterized in the literature. McFarlane's article laid the groundwork for describing the diverse fascial anatomy of Dupuytren cords. In his review, he describes 3 incidences of multiple cords in 1 digit, though never on both radial and ulnar sides of the digit.<sup>3</sup> Since, more variations in cords have been reported with increasing complexity. Hettiaratchy describes five cases of a spiral cord in conjunction with an isolated digital cord, causing a corkscrew nature of the neurovascular bundle.<sup>5</sup> In these digits, the neurovascular bundle spiraled twice around the same continuous fibrotic cord. These corkscrew cords were reported only on one side of the digit as well. Strickland describes what we find as the only other report of two opposing cords in 1 digit. In 6 digits, the authors discovered ulnar and radial isolated digital cords, originating and terminating in the digit without the involvement of the proximal neurovascular bundle or palmar fascia.<sup>6</sup> However, our patient is unique in that not only there were two opposing cords in one digit, they were both spiral cords (Fig. 4).

In Dupuytren's disease, surgical intervention is indicated for advanced stages, such as our patient with severe proximal interphalangeal joint flexion contracture over 100 degrees. In a review of surgical complications of Dupuytren's disease, there was a major complication rate of 15.7%, with injury to the digital nerve occurring in 3.4% of cases, and vascular damage occurring in 2% of cases. However, altered anatomy that displaces the neurovascular



**Fig. 4.** Diagrammatic representation of the various anatomical variants compromising the neurovascular bundle. A, Normal anatomy. B, Spiral cord. C, Hettiaratchy's corkscrew cord: spiral cord with ipsilateral isolated digital cord. D, Strickland's double isolated digital cords. E, Patient described in this case: double spiral cords.

bundle, such as a spiral cord, increases this risk of neurovascular injury.<sup>7,8</sup> In the case of spiral cords, the greater the tension on the cord, the more superficial and midline the neurovascular structures are displaced. Our patient's "double spiral" placed the digit at a greater risk for digital neuropathy and injury to the neurovascular bundles. After isolation of the hypertrophic ulnar spiral cord of the right ring finger, a second spiral cord was discovered originating from a shared pretendinous cord. With meticulous dissection, the diseased tissue was removed en bloc, and all physiologic structures were preserved.

### CONCLUSION

Our case demonstrates the first bilateral spiral cord affecting a single digit and emphasizes the importance of thorough dissection during limited fasciectomy to prevent iatrogenic injury and facilitate improved functional outcomes.

**Dr. Raymond Pensy, MD**

22 S. Greene St, Baltimore, MD 21201

E-mail: RPensy@som.umaryland.edu

### ACKNOWLEDGMENTS

*The authors thank Jocelyn Wu, BA, University of Maryland School of Medicine, for her artistic contributions to our work. Procedures followed in this study were in accordance with ethical*

*standards. This article does not contain any studies with human or animal subjects.*

### REFERENCES

1. Dibenedetti DB, Nguyen D, Zografos L, et al. Prevalence, incidence, and treatments of Dupuytren's disease in the United States: results from a population-based study. *Hand (N Y)*. 2011;6:149–158.
2. Agee JM, Goss BC. The use of skeletal extension torque in reversing Dupuytren contractures of the proximal interphalangeal joint. *J Hand Surg Am*. 2012;37:1467–1474.
3. McFarlane RM. Patterns of the diseased fascia in the fingers in Dupuytren's contracture. Displacement of the neurovascular bundle. *Plast Reconstr Surg*. 1974;54:31–44.
4. Guney F, Yuruten B, Karalezli N. Digital neuropathy of the median and ulnar nerves caused by Dupuytren's contracture: case report. *Neurologist*. 2009;15:217–219.
5. Hettiaratchy S, Tonkin MA, Edmunds IA. Spiralling of the neurovascular bundle in Dupuytren's disease. *J Hand Surg Eur Vol*. 2010;35:103–108.
6. Strickland JW, Bassett RL. The isolated digital cord in Dupuytren's contracture: anatomy and clinical significance. *J Hand Surg Am*. 1985;10:118–124.
7. Khashan M, Smitham PJ, Khan WS, et al. Dupuytren's disease: review of the current literature. *Open Orthop J*. 2011;5 Suppl 2:283–288.
8. Denkler K. Surgical complications associated with fasciectomy for Dupuytren's disease: a 20-year review of the English literature. *Eplasty*. 2010;10:e15.