



# Disseminated Histoplasmosis Mimicking Acute Liver Failure in a Patient Treated With a Tumor Necrosis Factor Inhibitor

Damini Saxena, MD<sup>1</sup>, Andrew Lange, MD<sup>2</sup>, Seanna R. Daves, MD<sup>1</sup>, and Carmi S. Punzalan, MD, MS<sup>3</sup>

<sup>1</sup>General Internal Medicine, Lahey Hospital and Medical Center, Beth Israel Lahey Health, Burlington, MA

<sup>2</sup>Department of Gastroenterology, Lahey Hospital and Medical Center, Beth Israel Lahey Health, Burlington, MA

<sup>3</sup>Department of Transplant and Hepatobiliary Diseases, Lahey Hospital and Medical Center, Beth Israel Lahey Health, Burlington, MA

## ABSTRACT

Disseminated histoplasmosis (DH) is typically seen in patients with organ transplantation or human immunodeficiency virus and rarely presents with acute liver failure. Tumor necrosis factor inhibitors may be immunosuppressive but unlikely to result in DH. A 70-year-old woman with a history of psoriatic arthritis on infliximab presented with altered mental status, fevers, and severe liver injury. She was found to have DH, which resolved on antifungal agents. Because the use of tumor necrosis factor inhibitors has increased, providers should consider this uncommon infection in patients who present with cryptogenic severe liver injury.

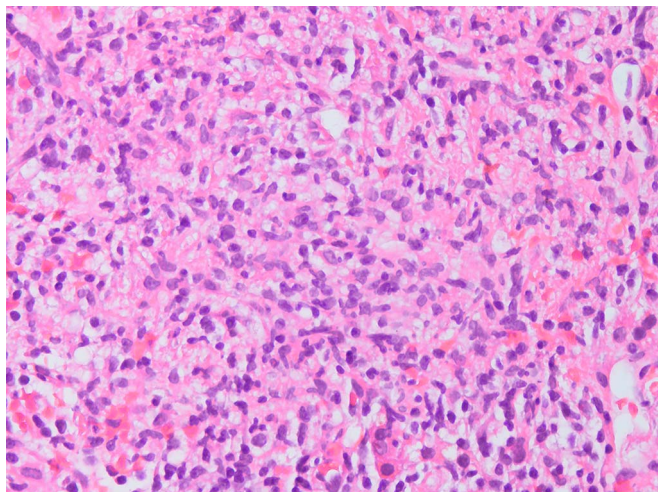
## INTRODUCTION

Acute liver failure (ALF) is defined by the development of severe liver injury within 8 weeks of symptom onset in the absence of prior disease, the international normalized ratio (INR) of at least 1.5, and the presence of hepatic encephalopathy.<sup>1,2</sup> Disseminated histoplasmosis (DH) presenting with ALF is uncommon,<sup>3</sup> typically seen in patients who have human immunodeficiency virus (HIV) or have had an organ transplant.<sup>4</sup> Rarely, it has also occurred in patients receiving tumor necrosis factor- $\alpha$  (TNF- $\alpha$ ) inhibitors, which may dampen immunogenic responses, increasing the risk for fungal infections.<sup>5</sup>

## CASE REPORT

A 70-year-old woman with psoriatic arthritis on infliximab presented with 1 week of altered mental status and jaundice and 5 months of malaise, night sweats, fever, and weight loss. She had no known history of liver disease or alcohol misuse but had notably traveled to Virginia and Ohio in the past year. On examination, the patient had normal vital signs except for a fever of 103°F, and was found to have asterixis and confusion. Laboratory findings were consistent with cholestatic hepatitis, including elevated total bilirubin (7.4 mg/dL), direct bilirubin (5.6 mg/dL), aspartate aminotransferase (129 IU/L), alanine transaminase (56 IU/L), alkaline phosphatase (549 IU/L), and INR (1.7).

The initial workup included negative viral hepatitis serologies and bacterial blood cultures. Autoimmune antibodies were positive (antinuclear antibody titer 1:80 with antismooth muscle antibody 72 U). Chest x-ray showed no acute pathology, although computed tomography imaging of the chest revealed 2 7-mm left lower lobe pulmonary nodules of unknown chronicity. Abdominal ultrasound revealed patent hepatic vasculature, ascites, and splenomegaly. Magnetic resonance cholangiopancreatography demonstrated no focal liver mass or biliary ductal dilatation. Numerous T2 hypointense lesions of nonspecific etiology were seen in the spleen. The concern for autoimmune hepatitis (AIH) prompted a liver biopsy, which noted severe portal and panlobular inflammation with marked interface activity, balloon degeneration, bridging and confluent necrosis, and severe biliary ductal injury (Figure 1). Initial pathologic findings were consistent with AIH, but because of persistent fevers, steroids for AIH treatment were deferred.



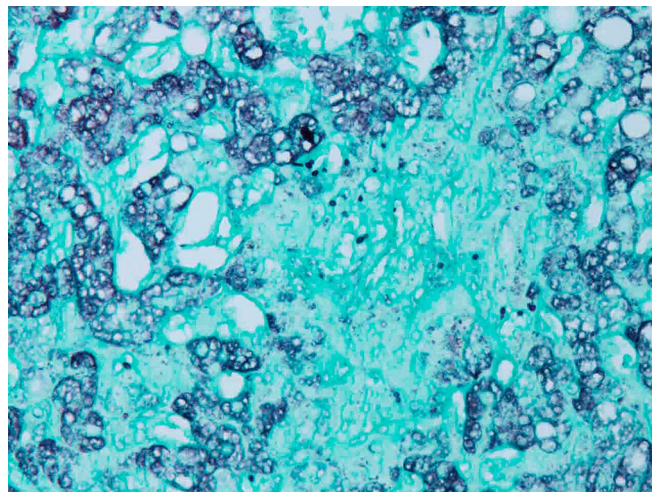
**Figure 1.** Transjugular liver biopsy showing portal and panlobular inflammation with lymphocytic predominance, interface activity, and extensive necrosis with biliary ductal injury (hematoxylin and eosin stain).

The patient's urine antigen, serum antibody, and fungal blood cultures 3 days after initial presentation resulted positive for *Histoplasma capsulatum*, consistent with a diagnosis of DH. Amphotericin B was started. Silver stain (Grocott's methenamine) on the liver biopsy confirmed fungal yeasts (Figure 2). Cerebrospinal fluid from the patient's lumbar puncture also yielded 2 yeast forms. Owing to the development of acute renal injury, the patient's antifungal treatment was later switched to itraconazole. Treatment monitoring with *Histoplasma* urine antigen showed improvement in titers. The patient's mental status, liver profile, and INR improved on antifungal medication and were normal by her discharge 2 months after admission.

## DISCUSSION

In immunocompetent patients, histoplasmosis presents asymptotically in 50%–90% of cases.<sup>6</sup> In immunocompromised patients, the risk of disseminated disease can be 10 times higher.<sup>6</sup> Cytotoxic drugs, such as TNF- $\alpha$  inhibitors, may increase the risk of DH in select patients. Typically, Th1 cells secrete TNF- $\alpha$  in response to fungal infections, resulting in the activation of innate immune cells, such as macrophages.<sup>7</sup> The TNF- $\alpha$  blockade, such as with infliximab, dampens the innate immune response to fungal infections, which may allow for the dissemination of *Histoplasma* through the reticuloendothelial system. The diagnosis of DH hinges on having a strong suspicion on initial presentation, which relies on the patient's risk factors. In this case report, the patient had no apparent risk factors, such as HIV infection or a history of solid organ transplant, but was on infliximab, which may have suppressed her innate immunity and predisposed her to DH.

Although the hallmark of histoplasmosis on histology is the presence of granulomas, these may not be prevalent in advanced DH.<sup>8</sup> Granuloma formation is a type IV hypersensitivity reaction composed of many macrophages fusing into giant cells under the



**Figure 2.** Transjugular liver biopsy showing many yeast cells (Grocott's methenamine silver stain).

direction of CD4<sup>+</sup> T cells.<sup>9</sup> The evolutionary benefit of granuloma formation may be that the infective organism is isolated in this matrix, preventing it from advancing into disseminated disease.<sup>9</sup> It follows, then, that under the presence of TNF- $\alpha$  blockade, macrophages may be unable to form granulomas surrounding *Histoplasma capsulatum*, resulting in the spread of infection and a lack of granulomas on microscopic examination in disseminated disease. Unsurprisingly, no granulomas were isolated on histological examination in our patient.

Furthermore, histological findings in cases of DH affecting the liver may be similar to histology found with AIH, but fungal stains will reveal yeasts. Our patient developed severe hepatic injury due to histoplasmosis in the setting of TNF- $\alpha$  inhibition. Her presentation, including acute encephalopathy, jaundice, and evidence of liver dysfunction in the absence of prior liver disease, was initially concerning for ALF, possibly from AIH based on initial findings on liver biopsy. Lymphoplasmacytic infiltration and interface activity on histologic examination that was seen in this case is commonly seen in AIH but can also be seen in DH.<sup>10–12</sup> As seen in this case, necrosis is also seen in DH and AIH, although is far less common in AIH than in DH.<sup>13</sup> Better tests distinguishing the 2 diagnoses on histology are Grocott's methenamine silver and periodic acid-Schiff stains, which strongly mark fungal polysaccharide walls.<sup>14</sup>

With the increasing use of TNF- $\alpha$  inhibitors, this case demonstrates the need to be vigilant about the adverse effects of these medications. Disseminated histoplasmosis should be considered in patients on TNF- $\alpha$  inhibitors who present with cryptogenic liver failure, encephalopathy, and fevers.

## DISCLOSURES

Author contributions: D. Saxena wrote the article and reviewed the literature. A. Lange revised the article for intellectual

content. SR Daves and CS Punzalan edited the article and reviewed the literature. CS Punzalan is the author guarantor.

**Acknowledgments:** The authors acknowledge Dr Xiaofei Wang, consultant pathologist who helped with the histological diagnosis.

**Financial disclosure:** None to report

**Previous presentation:** This case was presented at Digestive Disease Week; October May 2-5, 2020; Chicago, Illinois

**Informed consent** was obtained for this case report

Received March 14, 2021; Accepted July 27, 2021

## REFERENCES

- Bernal W, Wendon J. Acute liver failure. *N Engl J Med*. 2013;369:2525–34.
- Anand AC, Garg HK. Approach to clinical syndrome of jaundice and encephalopathy in tropics. *J Clin Exp Hepatol* 2015;5:S116–30.
- Kahi CJ, Wheat LJ, Allen SD, Sarosi GA. Gastrointestinal histoplasmosis. *Am J Gastroenterol*. 2005;100(1):220–31.
- Hajjeh RA. Disseminated histoplasmosis in persons infected with human immunodeficiency virus. *Clin Infect Dis*. 1995;21(Suppl 1):S108–10.
- Dakhoul L, Parikh K, Post A, et al. Disseminated histoplasmosis associated with anti-tumor necrosis factor alpha therapy: A case series. *Am J Gastroenterol*. 2015;110:S291.
- Gonzalez HH, Rane M, Cioci A, Goodman S, Espinosa PS. Disseminated central nervous system histoplasmosis: A case report. *Cureus*. 2019;11(3):e4238.
- Hage CA, Bowyer S, Tarvin SE, Helper D, Kleiman MB, Wheat LJ. Recognition, diagnosis, and treatment of histoplasmosis complicating tumor necrosis factor blocker therapy. *Clin Infect Dis*. 2010;50(1):85–92.
- Subramanian S, Abraham OC, Rupali P, Zachariah A, Mathews MS, Mathai D. Disseminated histoplasmosis. *J Assoc Physicians India*. 2005;53:185–9.
- Heninger E, Hogan LH, Karman J, et al. Characterization of the *Histoplasma capsulatum*-induced granuloma. *J Immunol*. 2006;177(5):3303–13.
- Gurung A, Assis DN, McCarty TR, Mitchell KA, Boyer JL, Jain D. Histologic features of autoimmune hepatitis: A critical appraisal. *Hum Pathol*. 2018;82:51–60.
- Chan AWH. Autoimmune Hepatitis. *PathologyOutlines.Com* Available from: <https://www.pathologyoutlines.com/topic/liverautoimmune.html>. Published May 20, 2021. Accessed June 19, 2021.
- Mukhopadhyay S, Katzenstein AL. Biopsy findings in acute pulmonary histoplasmosis: Unusual histologic features in 4 cases mimicking lymphomatoid granulomatosis. *Am J Surg Pathol*. 2010;34:541–6.
- Hofer H, Oesterreicher C, Wrba F, Ferenci P, Penner E. Centrilobular necrosis in autoimmune hepatitis: A histological feature associated with acute clinical presentation. *J Clin Pathol*. 2006;59(3):246–9.
- Wright AM, Mody DR, Anton RC, et al. Aberrant staining with Grocott's methenamine silver: Utility beyond fungal organisms. *J Am Soc Cytopathol*. 2017;6(6):223–7.

---

**Copyright:** © 2021 The Author(s). Published by Wolters Kluwer Health, Inc. on behalf of The American College of Gastroenterology. This is an open access article distributed under the terms of the Creative Commons Attribution-Non Commercial-No Derivatives License 4.0 (CCBY-NC-ND), where it is permissible to download and share the work provided it is properly cited. The work cannot be changed in any way or used commercially without permission from the journal.