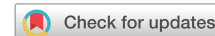

Intracoronary acetylcholine–induced augmentation of J waves: A case of idiopathic ventricular fibrillation



Shohei Kishi, MD,* Koichi Fuse, MD, PhD,* Hitoshi Kitazawa, MD,*
Takao Sato, MD, PhD,* Msaaki Okabe, MD,* Yoshifusa Aizawa, MD, PhD[†]

From the *Department of Cardiology, Tachikawa General Hospital, Nagaoka, Japan, and [†]Division of Research and Development, Tachikawa Medical Center, Nagaoka, Japan.

Introduction

Ventricular fibrillation (VF) may occur in patients without demonstrable cardiac disease, known as idiopathic VF (IVF). In these patients, slurring and notching may be observed in the terminal part of QRS complexes as a sole finding,^{1–4} and the electrocardiography (ECG) findings are known as J waves and are categorized as J-wave syndrome.⁵ A pause-dependent augmentation of the J-wave amplitude has been noted in IVF patients, which is a striking feature of J waves.^{1,6,7} Recently, tachycardia-dependent attenuation of J waves was confirmed in the J waves of IVF patients.⁸

Similar ECG findings can be seen in individuals in a general population and are shown to be associated with an increased risk of sudden cardiac death.⁹ Some of these J waves may show augmentation at higher heart rates but no augmentation at slower rates.¹⁰ The different response patterns of these J waves to changes in heart rate suggest the presence of different mechanisms for J waves, which may be useful for discriminating the malignant J waves of IVF patients from benign ones in individuals of a general population.

J waves were well reproduced in animal studies, and transient outward currents (*I_{to}*) expressed predominantly in the epicardial myocardium were shown to be responsible for J waves.¹¹ However, factors for the genesis and dynamicity of J waves are not fully understood.

Here, we examined a patient with out-of-hospital cardiac arrest. Intracoronary acetylcholine-induced augmentation of J waves was present during a provocation test, and a coronary spasm was not induced.

KEYWORDS Idiopathic ventricular fibrillation; Intracoronary acetylcholine; J-wave augmentation; No structural heart disease; Transient outward currents

(Heart Rhythm Case Reports 2018;4:247–250)

Address reprint requests and correspondence: Dr Yoshifusa Aizawa, Research and Development, Tachikawa Medical Center, 561-1 Yachi, Jo-Jo Cho, Nagaoka, Japan 940-8621. E-mail address: aizaways@med.niigata-u.ac.jp.

Case report

The patient was a 35-year-old man. He was well until he experienced a cardiac arrest while running in a gymnasium at night (around 10:00 PM). The episode was witnessed by his friends, who noted his absent arterial pulsation and performed cardiac massage and made an emergency call. Upon arrival of emergency personnel 5 minutes later, an electrical shock was delivered via an automatic external defibrillator. Both circulation and respiration returned, but he remained in a deep coma and was transferred to our hospital. Retrieval of ECG from the automatic external defibrillator showed VF as the cause of cardiac arrest.

On admission, the patient's blood pressure was 118/62 mm Hg (systolic/diastolic), his pulse rate was 106 beats/min, and his blood temperature was 37.7°C. Later, the patient was found to be 178 cm tall and 70 kg in weight.

He responded only to strong pain stimuli, but a physical examination was normal. Arterial gas analysis showed hypoxemia, hypercapnea, and acidosis ($PO_2 = 68$ mm Hg, $PCO_2 = 62$ mm Hg, and $pH = 7.26$), and the patient was intubated. Complete blood counts and serologic tests were normal. AST (85 IU/L), ALT (65 IU/L), and γ -GTP (92 IU/L) were elevated, whereas other blood chemistry was normal.

ECG showed atrial fibrillation with an incomplete right bundle branch block pattern (Figure 1A). J waves slur in the terminal part of the QRS complexes were suggested in the inferior leads, III and aVF, that were larger at prolonged R-R intervals (Figure 1B). The chest radiograph and echocardiography were normal.

Course after admission

Emergency catheterization revealed normal coronary arteries and cardiac wall motion. The patient was cared for in the coronary care unit under therapeutic hypothermia at 34°C. J waves became more evident after admission (Figure 1A). The patient gained consciousness and was extubated on the fourth day. On the fifth day after admission, he was moved to the general ward. His electroencephalogram and brain magnetic resonance imaging were normal, and no neurologic

KEY TEACHING POINTS

- J wave may be observed in patients with idiopathic ventricular fibrillation (IVF).
- J waves of IVF patients are known to be augmented under enhanced vagal tone or at bradycardia.
- In the present case, VF was precipitated by exercise at night, and J waves were augmented by intracoronary acetylcholine.
- The specificity and mechanism of the acetylcholine-induced J-wave augmentation is to be confirmed in a larger number of cases.

abnormality was detected. He received physical therapy, and exercise tests on a treadmill were performed before and after implantation of an implantable cardioverter-defibrillator. They induced no change in J waves, ST segment, or T wave. Neither premature ventricular contraction (PVC) nor ventricular tachycardia was induced during exercise.

Acetylcholine-induced ECG changes

On the 17th day, a provocation test for coronary vasospasm was attempted, and the result was negative. The baseline ECG showed J waves in leads III and aVF, measuring

0.18–0.21 mV and 0.09–0.10 mV, respectively (Figure 2). Introduction of acetylcholine into the right coronary artery induced a dose-dependent augmentation of the J-wave amplitude (Figure 2). The height of r' in V₁ was increased, and the slur of the ascending limb of S in V₂ (and V₃) became shallower with acetylcholine administration. However, augmentation of the J waves was negligible when acetylcholine (100 µg) was introduced into the left coronary artery, but in this case there was induced T-wave inversion in V₃ through V₅ (Figure 2). No PVC or ventricular tachycardia was induced during intracoronary acetylcholine administration, and the R-R interval changed little: 680 ms at baseline to 707 ms after acetylcholine (Figure 2).

Course after hospitalization

As this was a case of IVF associated with J waves, an implantable cardioverter-defibrillator with subcutaneous leads was implanted on the 20th day and the patient was discharged on the 28th day. He was well, without ventricular arrhythmias, at the follow-up at the outpatient clinic. Magnetic resonance imaging performed 1 month later was negative: normal structure, normal wall motion, and no delayed enhancement.

Discussion

This case involved a patient with IVF who experienced an out-of-hospital cardiac arrest. VF was precipitated during exercise. J waves were observed in the inferior leads.

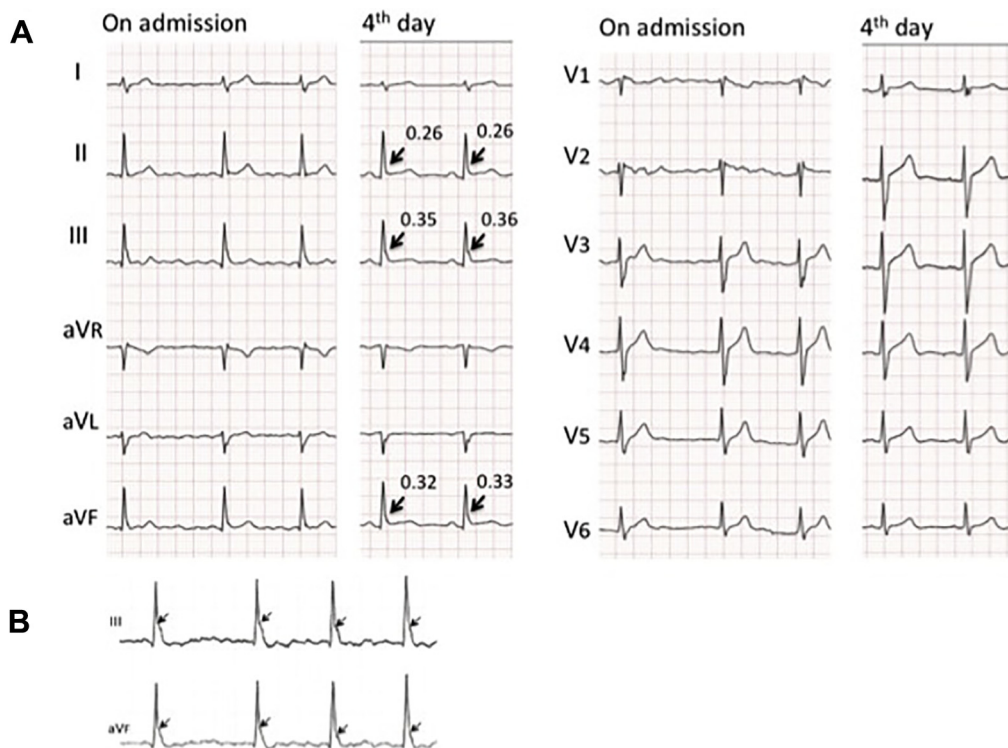


Figure 1 The surface electrocardiogram (ECG). **A:** On admission, the ECG showed atrial fibrillation. The QRS complexes were narrow without significant AT-T abnormality. Slurring was suggested in the inferior leads. On the fourth day after admission, sinus rhythm resumed. Slurring was evident in the inferior leads, II, III, and aVF. **B:** The J waves in leads III and aVF are bigger (smaller) when the preceding R-R interval is longer (shorter). The basic rhythm is atrial fibrillation.

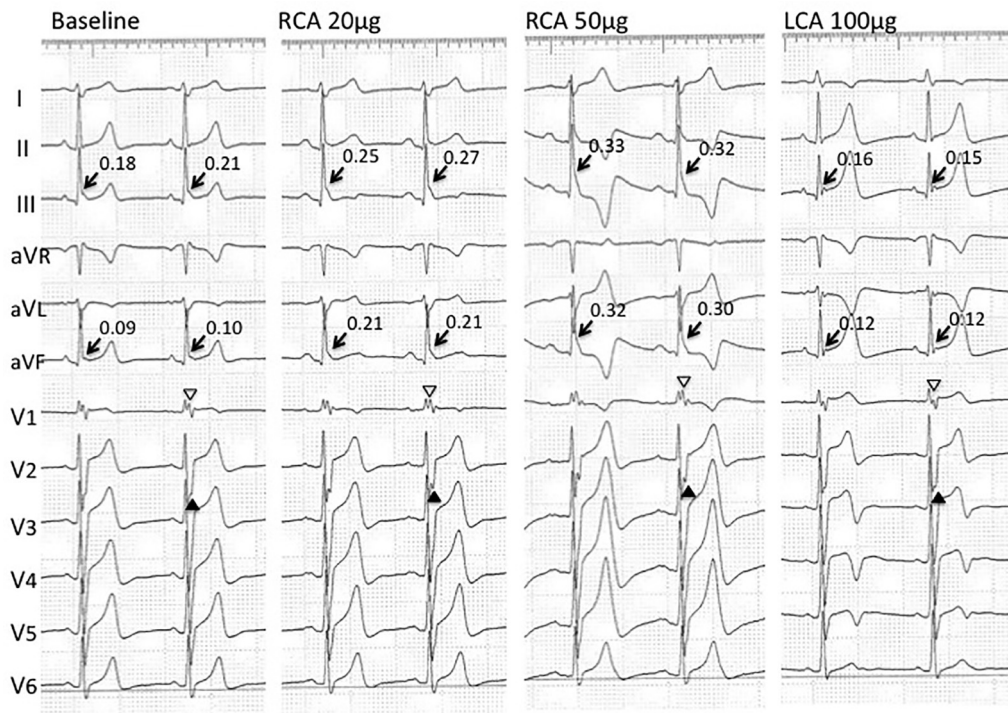


Figure 2 Electrocardiograms during the provocation test for coronary spasm. At baseline, J waves (arrows) were present in III and aVF, which increased after intracoronary administration of acetylcholine. A dose-dependent augmentation is evident. The height of r' in V_1 (white arrowheads) was increased, and the slur of the ascending limb of S in V_2 (and V_3) became shallower with acetylcholine (black arrowheads). However, augmentation of the J waves was negligible when acetylcholine (100 μg) was introduced into the left coronary artery, but in this case there was induced T-wave inversion in V_3 through V_5 . The R-R interval remained almost unchanged by acetylcholine: 680 ms at baseline vs 707 ms after acetylcholine infusion. PVC or ventricular tachycardia was not induced by acetylcholine infusion.

A provocation study for coronary spasm was negative, but acetylcholine introduced into the right coronary artery resulted in an augmentation of J waves, suggesting its action on J waves.

The J waves of the IVF patient were considered to represent early repolarization mediated by *Ito*.^{5,11} When *Ito* was inhibited by 4AP or quinidine, the phase 1 notch of the action potential decreased, with the concomitant diminution of J waves.¹¹ An augmentation of *Ito* is observed at slower rates and is considered to be the underlying mechanism of a pause-dependent augmentation of J waves, a characteristic ECG finding of IVF.^{1,6,7} Such a pause-dependent augmentation of J waves was observed in the present case.

Action of acetylcholine on phase 1 notch and/or ST segment were shown in animals. Koncz and colleagues¹² recorded action potentials from epicardial and endocardial sites of a coronary-perfused canine left ventricular wedge preparation, and produced J waves by giving an *Ito* agonist (NS5806) and verapamil. Addition of acetylcholine mimicking increased vagal tone to the perfusion medium led to increased AP notch, J waves, and phase 2 reentry followed by VF. Clinically, VF episodes of IVF patients with J waves are known to occur predominantly during nocturnal periods when the vagal tone increases, and augmentation of J waves of IVF patients by intracoronary acetylcholine administration can be expected from prior findings.^{1,6,13,14}

However, the change of J waves during intracoronary acetylcholine administration has never been reported thus far.

As an acquired type, J waves may be observed in association with myocardial ischemia and J waves may appear preceding vasospasm and/or development of VF.⁵ We analyzed J waves in patients with vasospastic angina.¹⁵ Among the 67 patients with proven coronary spasm, 14 patients (20.9%) revealed J waves in the baseline ECGs, and J waves were augmented (>0.1 mV) in 7 of 14 patients during intracoronary acetylcholine administration. Furthermore, 4 of the 7 patients with J-wave augmentation developed VF. Among the remaining 53 patients without J waves at the baseline, J waves were newly induced by intracoronary acetylcholine in 5 patients (9.4%), but VF developed in none of 53 patients. Thus, J waves related to myocardial ischemia in non-IVF patients can be augmented by intracoronary acetylcholine. We need further studies to confirm that acetylcholine modulates J waves, and the mechanism of action of acetylcholine on J waves is to be determined.

Conclusion

This is the first case showing that intracoronary acetylcholine augments J waves in an IVF patient. The action of acetylcholine on J waves and the mechanism are to be determined in a large number of J wave patients.

References

1. Aizawa Y, Tamura M, Chinushi M, Naitoh N, Uchiyama H, Kusano Y, Hosono H, Shibata A. Idiopathic ventricular fibrillation and bradycardia-dependent intraventricular block. *Am Heart J* 1993;126:1473–1474.
2. Haissaguerre M, Derval N, Sacher F, et al. Sudden cardiac arrest associated with early repolarization. *N Engl J Med* 2008;358:2016–2023.
3. Rosso R, Kogan E, Belhassen B, Rozovski U, Scheinman MM, Zeltser D, Halkin A, Steinvil A, Heller K, Glikson M, Katz A, Viskin S. J-point elevation in survivors of primary ventricular fibrillation and matched control subjects: incidence and clinical significance. *J Am Coll Cardiol* 2008;52:1231–1238.
4. Nam GB, Kim YH, Antzelevitch C. Augmentation of J waves and electrical storms in patients with early repolarization. *N Engl J Med* 2008;358:2078–2079.
5. Antzelevitch C, Yan GX, Ackerman MJ, et al. J-wave syndromes expert consensus conference report: emerging concepts and gaps in knowledge. *J Arrhythm* 2016;32(5):315–339.
6. Shinohara T, Takahashi N, Saikawa T, Yoshimatsu H. Characterization of J wave in a patient with idiopathic ventricular fibrillation. *Heart Rhythm* 2006;3:1082–1084.
7. Aizawa Y, Sato A, Watanabe H, et al. Dynamicity of the J-wave in idiopathic ventricular fibrillation with a special reference to pause-dependent augmentation of the J-wave. *J Am Coll Cardiol* 2012;59:1948–1953.
8. Aizawa Y, Takatsuki S, Nishiyama T, Kimura T, Kaneko Y, Inden Y, Takahashi N, Nagase S, Aizawa Y, Fukuda K. Tachycardia-induced J-wave changes in patients with and without idiopathic ventricular fibrillation. *Circ Arrhythm Electrophysiol* 2017;10(7).
9. Tikkanen JT, Junttila MJ, Anttonen O, Aro AL, Luttinen S, Kerola T, Sager SJ, Rissanen HA, Myerburg RJ, Reunanen A, Huikuri HV. Early repolarization: electrocardiographic phenotypes associated with favorable long-term outcome. *Circulation* 2011;123:2666–2673.
10. Aizawa Y, Sato M, Kitazawa H, Aizawa Y, Takatsuki S, Oda E, Okabe M, Fukuda K. Tachycardia-dependent augmentation of “notched J waves” in a general patient population without ventricular fibrillation or cardiac arrest: not a repolarization but a depolarization abnormality? *Heart Rhythm* 2015;12:376–383.
11. Yan GX, Antzelevitch C. Cellular basis for the electrocardiographic J wave. *Circulation* 1996;93:372–379.
12. Koncz I, Gurabi Z, Patocskaï B, Panama BK, Szél T, Hu D, Barajas-Martínez H, Antzelevitch C. Mechanisms underlying the development of the electrocardiographic and arrhythmic manifestations of early repolarization syndrome. *J Mol Cell Cardiol* 2014;68:20–28.
13. Mizumaki K, Nishida K, Iwamoto J, Nakatani Y, Yamaguchi Y, Sakamoto T, Tsuneda T, Kataoka N, Inoue H. Vagal activity modulates spontaneous augmentation of J-wave elevation in patients with idiopathic ventricular fibrillation. *Heart Rhythm* 2012;9:249–255.
14. Aizawa Y, Sato M, Ohno S, Horie M, Takatsuki S, Fukuda K, Chinushi M, Usui T, Aonuma K, Hosaka Y, Haissaguerre M, Aizawa Y. Circadian pattern of fibrillatory events in non-Brugada-type idiopathic ventricular fibrillation with a focus on J waves. *Heart Rhythm* 2014;11:2261–2266.
15. Sato A, Tanabe Y, Chinushi M, Hayashi Y, Yoshida T, Ito E, Izumi D, Iijima K, Yagihara N, Watanabe H, Furushima H, Aizawa Y. Analysis of J waves during myocardial ischemia. *Europace* 2012;14:715–723.