

# Ramsay Hunt syndrome with pontine lesion

## A case report

Ye Ji, MD<sup>a</sup>, Guo-Mei Ma, MD<sup>b</sup>, Zhi-Lei Kang, MD<sup>c</sup>, Yi Zhang, MD<sup>d</sup>, Jing-Zhe Han, MD<sup>b,\*</sup>, Jin Li, MD<sup>a</sup>, Dan-Dan Wu, MD<sup>a</sup>, Jia Wang, MD<sup>a</sup>

### Abstract

**Rationale:** The coexistence of Ramsay Hunt syndrome (RHS) and varicella-zoster virus (VZV) encephalitis is rare. A patient who developed RHS after being infected with VZV, along with a pontine lesion, is reported in the present study.

**Patient concerns:** A 41-year-old male patient presented with his mouth askew for 7 days, and dizziness, accompanied by hearing loss for 3 days.

**Diagnoses:** The patient was initially diagnosed with RHS. Brainstem encephalitis was confirmed by lumbar puncture and cerebrospinal fluid. Brain magnetic resonance imaging (MRI) and diffusion-weighted imaging (DWI) revealed how VZV entered the intracranial space along the vestibulocochlear nerve and facial nerve in the acute period.

**Interventions:** Intravenous acyclovir, IV, immunoglobulins (IVIg) and methylprednisolone were administered.

**Outcomes:** The herpes was cleared up and left facial nerve palsy was improved, but hearing loss in the left ear did not improve.

**Lessons:** An MRI was necessary for some VZV infections limited to the cranial nerve, although there was no evidence of brain stem injury. DWI provided evidence, showing how VZV entered the brain in the early stage. This allowed the doctor to judge the necessity of a lumbar puncture.

**Abbreviations:** CNS = central nervous system, CSF = cerebrospinal fluid, DWI = diffusion-weighted imaging, IVIg = immunoglobulins, MRI = magnetic resonance imaging, RHS = Ramsay Hunt syndrome, VZV = varicella-zoster virus.

**Keywords:** brainstem encephalitis, diffusion-weighted imaging, magnetic, Ramsay Hunt syndrome, resonance imaging, varicella-zoster virus

## 1. Introduction

Varicella-zoster virus (VZV) is a member of the family Herpesviridae. It has the ability to establish latency in the dorsal root, autonomic, and cranial ganglia, and the infection can lead to Ramsay Hunt syndrome (RHS), which is characterized by peripheral facial nerve involvement, or encephalitis with central nervous system (CNS)-related signs and symptoms.<sup>[1,2]</sup> The coexistence of RHS and VZV encephalitis is rare. The study conducted by T. Kin et al only revealed 8 cases, including 1 case in their study, and other cases from English and Japanese literature.<sup>[3]</sup> VZV reaches the CNS by either retrograde axonal

transport, or through the blood stream. Scattered inflammatory infiltrates along the intrapontine facial nerve from its core origin within the caudal and lateral pons to its nerve root exit zone at the lateral pons have been histologically described.<sup>[4]</sup> However, to date, the involvement of a pontine nucleus and intrapontine nerve course has only been demonstrated on post-contrast T1-weighted images and T2-weighted images in patients with RHS.<sup>[5,6]</sup> A patient who developed RHS after being infected by VZV, along with a pontine lesion, is reported in the present study. Magnetic resonance imaging (MRI) clearly revealed the invasion paths and demonstrated the complicated anatomical structure of this area.

## 2. Case report

A 41-year-old male patient presented with his mouth askew for 7 days and dizziness, accompanied by hearing loss for 3 days. This patient visited our hospital. At 7 days before the hospital visit, the patient had left facial nerve palsy, along with pain in the left external ear canal after upper respiratory infection. However, the patient did not take any medications. At 3 days before the hospital visit, herpes manifested in his left ear, along with dizziness, nausea and vomiting, and tinnitus and hearing loss in the left ear. In addition, the patient denied symptoms, such as headache, limbs twitch, and disturbance of consciousness. This patient visited our hospital. The patient had no history of hypertension and diabetes and was otherwise healthy except for the infection. However, the personal history was not particular. The results of the physical examination revealed that there were a lot of patchy blisters in the left auricle and back of the ear of the patient, along with some secretion. The patient was conscious

Editor: N/A.

The authors have no conflicts of interest to disclose.

<sup>a</sup> Department of Neurological Function Examination, <sup>b</sup> Department of Neurology, <sup>c</sup> Department of MRI, <sup>d</sup> Department of ENT, Harrison International Peace Hospital, Hengshui, China.

\* Correspondence: Jing-Zhe Han, Department of Neurology, Harrison International Peace Hospital, No. 180 of Renmin East Road, Taocheng District, Hengshui 053000, China (e-mail: drjingzhehan@163.com).

Copyright © 2019 the Author(s). Published by Wolters Kluwer Health, Inc. This is an open access article distributed under the terms of the Creative Commons Attribution-Non Commercial-No Derivatives License 4.0 (CCBY-NC-ND), where it is permissible to download and share the work provided it is properly cited. The work cannot be changed in any way or used commercially without permission from the journal.

Medicine (2019) 98:5(e14260)

Received: 24 September 2018 / Received in final form: 26 December 2018 /

Accepted: 1 January 2019

<http://dx.doi.org/10.1097/MD.0000000000014260>

and had fluent speech. Furthermore, the patient had horizontal nystagmus when his binoculars gazed left or right. In addition, left facial nerve palsy and a positive sign of Bell's palsy was observed when the patient closed his eyes, and the exposure occurred was 4 mm. Moreover, there was hearing loss in the left ear, negative meningeal irritation signs, and no abnormalities were found in other neurological examinations. The results of the routine blood test, blood coagulation index, and blood biochemical index were normal. The patient's anti-HIV antibody was negative. This patient fulfilled the criteria for RHS due to the herpes zoster of the head with facial nerve palsy. MRI of brain after admission revealed long T1 and T2 signals, high FLAIR, and diffusion-weighted imaging (DWI) signals in the left pedunculus cerebellaris medius. The DWI revealed a high signal. The facial nerve and vestibulocochlear nerve swelled. The DWI revealed a high signal along the nerve course. The gadolinium-enhanced MRI revealed that the facial nerve and vestibulocochlear nerve at the bottom of the internal auditory canal was enhanced, but the brainstem was not abnormally enhanced (Figs. 1 and 2).

Lumbar puncture was performed, and it was found that colorless and transparent cerebrospinal fluid (CSF) was discharged. CSF pressure was 160 mmH<sub>2</sub>O. The biochemistry of the CSF was as follows: total number of erythrocytes, 32 × 10<sup>6</sup>/L; total protein, 0.68 g/L. The levels of glucose and chlorides in the CSF were normal.

The cultures for bacteria in the CSF were negative. An elevated serum IgM antibody titer against VZV on enzyme-linked immunosorbent assay (ELISA) and the presence of CSF VZV DNA amplified by polymerase chain reaction (PCR) confirmed the VZV infection. The herpes simplex virus DNA was negative. Although there were no clinical manifestations of encephalitis, all these findings indicated that the patient had VZV encephalitis. This patient was immediately administrated with intravenous acyclovir (10 mg/kg Q8h, 21 days), IV, immunoglobulins (IVIg; 0.4 g/kg, 5 days), and methylprednisolone (40 mg/d, 10 days) after hospitalization. Lumbar puncture was performed again after 21 days of antiviral therapy. It was found that colorless and transparent CSF was discharged. CSF pressure was 110 mmH<sub>2</sub>O.

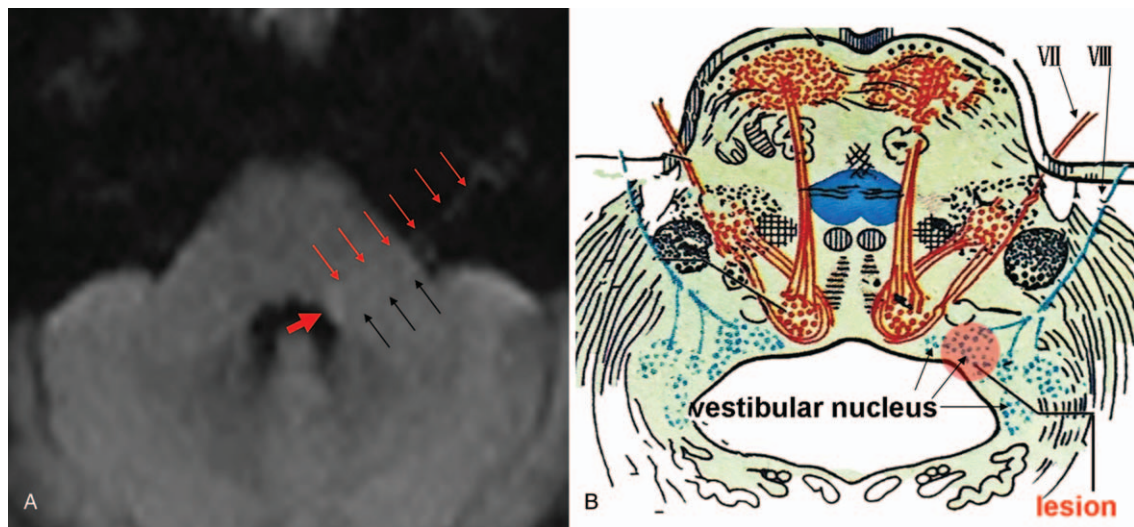
The biochemistry of the CSF was as follows: total number of erythrocytes, 4 × 10<sup>6</sup>/L; total protein, 0.32 g/L. The levels of glucose and chlorides in the CSF were normal.

The PCR results for VZV DNA in the CSF became negative. The patient and his family refused a brain MRI review, and the patient was discharged. At that time, the herpes was cleared up, but the left facial nerve palsy and hearing loss remained. At 6 months after discharge, the left facial nerve palsy improved, but hearing loss in the left ear did not improve.

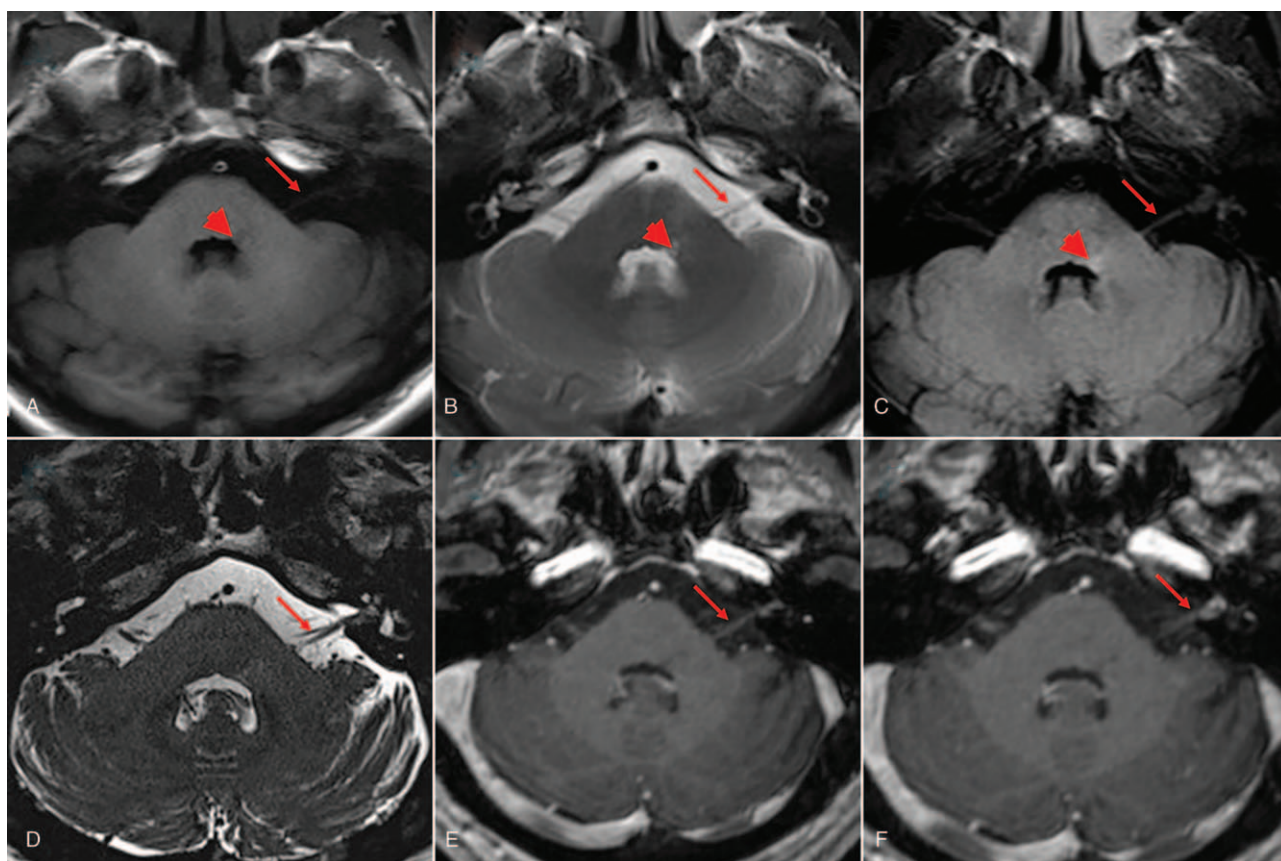
The patient has provided informed consent for publication of the case.

### 3. Discussion

Typical RHS involves unilateral peripheral facial nerve palsy accompanied by erythematous vesicular lesions in the ear (zoster oticus).<sup>[7,8]</sup> The VIII cranial nerve can often be involved, while the V, VI, IX, X, XI, and XII cranial nerves are rarely affected, causing extraocular movement limitations, facial sensorimotor changes, bulbar dysfunction, and neck weakness.<sup>[9,10]</sup> The patient in the present study had typical clinical manifestations, such as pain in the left external ear canal, herpes in the left ear, and left facial nerve palsy. All these symptoms corresponded to the diagnosis criteria for RHS. In addition, the patient admitted these symptoms, such as hearing loss and dizziness. All these symptoms revealed vestibulocochlear nerve involvement. Classical RHS refers to zoster oticus and peripheral facial palsy with or without vestibulocochlear nerve involvement. The gadolinium-enhanced MRI revealed that the facial nerve and vestibulocochlear nerve at the bottom of the internal auditory canal was enhanced, which are evidence for facial nerve and vestibulocochlear nerve involvement by viruses. VZV reactivation causes inflammation and edema throughout the facial nerve and vestibulocochlear nerve located in the narrow fallopian canal, which breaks down the blood-nerve barrier. Transverse hyperintensities in the central pons on T2 and FLAIR images obviously revealed signal changes in the left vestibular nucleus, and along vestibulocochlear nerve.



**Figure 1.** A. Facial colliculus level, DWI showed high signal in the left pedunculus cerebellaris medius and outside of facial colliculus, vestibulocochlear nucleus were injured mainly (a thick red arrow); high signal in the section of pons and cisterns of the facial nerve (long red arrow); high signal in the section of pons of the vestibulocochlear nerve (long black arrow). B. Corresponding brainstem pattern diagrams of Figure 1A in facial colliculus level. DWI = diffusion-weighted imaging.



**Figure 2.** A (T1), B (T2), C (FLAIR), axial image shows long T1 and T2 signals, high FLAIR signal in the left pedunculus cerebellaris medius and outside of facial colliculus (short red arrow); the left facial nerve and vestibulocochlear nerve of cisterns swell (long red arrow). D, 3D-CISS imaging shows the left facial nerve and vestibulocochlear nerve swell and thickening; E and F, axial image shows gadolinium-enhanced of the section of cisterns and internal auditory canal of the left facial nerve and vestibulocochlear nerve of cisterns (red arrow).

Hence, the present patient could also be diagnosed with VZV brainstem encephalitis, according to the CSF evidence of VZV and pontobulbar involvement on the brain MRI images. VZV finally reaches the CNS by either retrograde axonal transport, or through the blood stream. The patient suffered from RHS, and subsequently, brainstem encephalitis. It was speculated that the possible pathogenesis was that after the infection of VZV, which was activated while it lurked in the geniculate ganglia, it retrograded in the geniculate ganglia. Then, the VZV entered the intracranial space from the inner ear hole, invaded the facial nerve and vestibulocochlear nerve, and went up to the facial nerve nucleus, vestibular nucleus and anterior and posterior nucleus of the cochlea nerve.

Recent studies have shown that the invasion of viruses to the neuron could lead to cell swelling, necrocytosis, and restricted diffusion, with a high signal on DWI.<sup>[11,12]</sup> The DWI of the patient was specific and could verify the above hypothesis. Furthermore, the DWI of the patient revealed a high signal on the left intrapontine facial nerve, vestibular nucleus, and along the vestibulocochlear nerve, revealing the acute infection of VZV. DWI of the patient also clearly revealed how the VZV entered the intracranial space along the vestibulocochlear nerve and facial nerve during the acute period. The gadolinium-enhanced MRI revealed no enhancements in the injured parts of the brainstem. It was considered that this was associated with the degree of brainstem injury and degree of blood-nerve barrier damage. This case may widen our knowledge of the mechanism of VZV

infections spreading into the CNS, demonstrating the complicated anatomical structure of this area.

There was no evidence of VZV encephalitis apparent dissemination in the present patient who had a good prognosis. The investigators considered that all this was associated with in-time diagnosis and treatment.

The cranial nerve palsies and encephalitis caused by VZV can leave severe sequelae and even threaten the life of the patient. Hence, early diagnosis and clinical management are crucial for its prognosis. RHS was the initial diagnosed disease of the present patient. There were no symptoms and signs of brain stem injury or encephalitis. Brain stem injury was found by MRI. After the intravenous acyclovir, IV, IVIg, and methylprednisolone were administered, the herpes was cleared up and left facial nerve palsy was improved, but hearing loss in the left ear did not improve. This case revealed that an MRI was necessary for some infection of VZV limited to the cranial nerve, although there were no evidence of brain stem injury. DWI provided evidence, which revealed how VZV entered the brain at the early stage. This allowed the doctor to determine the necessity of a lumbar puncture.

#### Author contributions

**Conceptualization:** Ye Ji, Jing-Zhe Han.

**Data curation:** Guo-Mei Ma.

**Resources:** Jin Li, Dan-Dan Wu, Jia Wang.

**Software:** Zhi-Lei Kang, Yi Zhang.

**Writing – original draft:** Ye Ji, Jing-Zhe Han.

**Writing – review & editing:** Ye Ji, Jing-Zhe Han.

## References

- [1] Hunt JR. On herpetic inflammation of geniculate ganglion: a new syndrome and its complications. *J Nerve Ment Dis* 1907;34:73–96.
- [2] Yao-Yao Shen, Ting-Min Dai, Hai-Ling Liu, et al. Ramsay Hunt syndrome complicated by brainstem encephalitis in varicella-zoster virus infection. *Chin Med J (Engl)* 2015;128:3258–9.
- [3] Kin T, Hirano M, Tonomura Y, et al. Coexistence of Ramsay Hunt syndrome and varicella-zoster virus encephalitis. *Infection* 2006;34:352–4.
- [4] Denney-Brown MB, Adams RD, Fitzgerald PJ. Pathologic features of herpes zoster: note on “geniculate herpes”. *Arch Neurol Psych* 1944;51:216–31.
- [5] Suzuki F, Furuta Y, Ohtani F, et al. Herpes virus reactivation and gadolinium-enhanced magnetic resonance imaging in patients with facial palsy. *Otol Neurotol* 2001;22:549–53.
- [6] Morelli N, Mancuso M, Cafforio G, et al. Ramsay-Hunt syndrome complicated by unilateral multiple cranial nerve palsies. *Neurol Sci* 2008;29:497–8.
- [7] Sweeney CJ, Gilden DH. Ramsay Hunt syndrome. *J Neurol Neurosurg Psychiatry* 2001;71:149–54.
- [8] Gupta NM, Parikh MP, Panginikkod S, et al. Ramsay Hunt syndrome. *QJM* 2016;109:693.
- [9] Xanthopoulos J, Noussios G, Papaioannides D, et al. Ramsay Hunt syndrome presenting as a cranial polyneuropathy. *Acta Otorhinolaryngol Belg* 2002;56:319–23.
- [10] Gunbey HP, Kutlar G, Aslan K, et al. Magnetic resonance imaging evidence of varicella zoster virus polyneuropathy: involvement of the glossopharyngeal and vagus nerves associated with ramsay hunt syndrome. *J Craniofac Surg* 2016;27:721–3.
- [11] Kastrup O, Wanke I, Maschke M. Neuroimaging of infections. *NeuroRx* 2005;2:324–32.
- [12] Marziali S, Picchi E, Di Giuliano F, et al. Facial diplegia resembling bilateral Ramsay Hunt syndrome. *J Neurol Sci* 2017;376:109–11.