

Injection of Paraquat in the Neck: A Rare Complicated Case Report

Abstract

Paraquat is a highly toxic compound and a widely used herbicide that causes serious morbidity and mortality. The most well-known route of poisoning is oral ingestion, whereas parenteral injection of paraquat is individually uncommon. We present a case who injected paraquat in his neck in an attempt to commit suicide. His general condition got worsened gradually over 3 days. He received early hemodialysis in 4 h after self-injection and then supportive treatment in intensive care unit. Early hemodialysis helped him survive, but during hospitalization, some rare complications occurred, and unfortunately, he died after 3 months. Despite the high-risk route of poisoning, the patient survived for 3 months. Our patient was protected from renal and hepatic damage may be because of early hemodialysis but suffered from central nervous system and pulmonary damage.

Keywords: *Complications, hemodialysis, injection, paraquat*

**Vahid Mansouri,
Alireza Rostamian,
Maryam
Bemanalizadeh**

*Department of Clinical
Toxicology, School of Medicine,
Noor Hospital, Isfahan
University of Medical Sciences,
Isfahan, Iran*

Introduction

Paraquat, classified as bipyridyl compounds, is one of the most common herbicides. It is generally used in aqueous solution form, which results in a variety of concentrations ranging from 5 to 50 mg/L.^[1] Poisoning with paraquat occurs generally through ingestion and dermal route,^[2] but some other routes were rarely reported.^[2-5] Most of the deaths occurred in the first 2 days, but some cases survived, either.^[6] Following is the report of a very rare patient who injected poison in his neck.

Case Report

A 25-year-old male was referred to the department of clinical toxicology of Noor hospital in Isfahan, Iran, with the emergency system. He injected about 1 ml of paraquat, attempted suicide, on the right side of his neck, posterior to the sternocleidomastoid muscle. The concentration of paraquat was unknown because the patients mentioned that he diluted the poison with water. Due to the proximity of a large number of vessels, nerves, muscles, and soft tissue in the neck, it cannot be said with certainty that the injection was intravenous (IV), intramuscular (IM), intradermal, subcutaneous (SC), or even in soft tissue. On admission, his vital signs and Glasgow

Coma Scale (GCS) score were normal and stable. The only complaint of the patient was the pain and numbness in his right arm. Furthermore, he reported a sense of electricity at the time of injection. All the other physical examinations were in the normal range. Initial complete blood count, electrolytes, coagulation, liver, and kidney function tests showed no abnormalities [Supplementary Table 1], but urine sodium dithionite test was positive [Figure 1]. After admission, he was transferred to intensive care unit; where we started supportive treatments, notably pirfenidone, methylprednisolone, N-acetyl cysteine, Vitamin E, and Vitamin C (tablet Pirfenidone 200 mg, $n = 3$, q8 h/gavage; vial methylprednisolone 500 mg, $n = 1$, q12 h IV/Inf, vial N-acetyl cysteine, $n = 15$, daily IV/Inf, vial Vitamin E 300U, $n = 1$, q12 h/IM, and vial Vitamin C 1 g, IV/inf). Four hours after injection, due to positive dithionite test hemodialysis was implemented empirically for 8 h. An hour after hemodialysis the dithionite test was repeated and was slightly paler [Figure 1], however, due to a maintained positive dithionite test, hemodialysis was implemented for the second time for 8 h. Then, he was implemented under hemodialysis daily and was hemodynamically stable; however, 3 days after injection, his general condition gradually became worsened. He became lethargic and had a fluctuation in his

Address for correspondence:
Dr. Maryam Bemanalizadeh,
Department of Clinical
Toxicology, School of Medicine,
Noor Hospital, Isfahan
University of Medical Sciences,
Isfahan, Iran.
E-mail: maryam.bmn91@gmail.com

Received: 27 September 2020
Revised: 11 October 2020
Accepted: 20 January 2021
Published: 27 October 2021

Access this article online

Website: www.advbiores.net

DOI: 10.4103/abr.abr_236_20

Quick Response Code:



How to cite this article: Mansouri V, Rostamian A, Bemanalizadeh M. Injection of paraquat in the neck: A rare complicated case report. *Adv Biomed Res* 2021;10:32.

This is an open access journal, and articles are distributed under the terms of the Creative Commons Attribution-NonCommercial-ShareAlike 4.0 License, which allows others to remix, tweak, and build upon the work non-commercially, as long as appropriate credit is given and the new creations are licensed under the identical terms.

For reprints contact: WKHLRPMedknow_reprints@wolterskluwer.com

level of consciousness, which progressed during 3 days to coma probably because of the neurotoxic effect of the poison. Besides, follow-up chest X-ray (CXR) revealed the presence of diffuse fibrotic changes on the 5th day of admission [Figure 2].

However, laboratory findings showed that hemodialysis had protected him from kidney and liver damage [Supplementary Table 1]. After Permcath insertion for dialysis, on the 6th day of admission, left SC infraclavicular emphysema with crepitation was observed, which accompanied by a left-sided pneumothorax and left lung upper lobe atelectasis, demonstrated in CXR [Figure 3]. Therefore, a chest tube was inserted in the left hemithorax. Furthermore, due to loss of consciousness and respiratory distress, he was intubated and connected to a ventilator. By the 11th day of admission, he had a generalized tonic-clonic seizure, probably due to the neurotoxic effect of the poison on the central nervous system (CNS). His brain computed tomography (CT) scan, electrolyte levels (including Na, K, Mg, Ca, and Ph), and blood sugar level were normal [Supplementary Table 1]. Levetiracetam (1 g stat, and 500 mg q8 h/IV) as an antiepileptic agent was started and increased to maximum dose (1 g q8 h/IV) because of recurrent seizures. Since the patient was irritable, we could not obtain the electroencephalography. He also got midazolam (infusion of 10–20 mg/h) and thiopental sodium (infusion of 50–100 mg/h) for sedation. On the 18th day of hospitalization, the chest tube has been exited. 25 days after admission, thrombocytopenia developed. Nasal and oral bleeding started 2 days later. According to internal medicine consultation, the thrombocytopenia was due to consumption thrombocytopenia after rolling out other diagnosis such as thrombotic thrombocytopenic purpura. Furthermore, due to lateralized findings in physical examination, a new brain CT scan was taken. Hypodense lesions in the fronto-occipital cortex and basal ganglia were seen. On the 37th day of admission, his magnetic resonance angiography and magnetic resonance venography were normal; however, multiple acute infarctions were seen in his MRI. By the 39th day of hospitalization, tracheostomy was done and ventilation continued. He had been disconnected from the ventilator on the 60th day of admission in a vegetative state. During his hospitalization, he was threatened with various antibiotics for (ventilator-associated pneumonia) according to tracheal culture (first under treatment of meropenem 1 g q8 h IV/infusion during 1 h and ciprofloxacin 400 mg q12 h IV/infusion during 1 h, then according to infectious diseases consultation, piperacillin + tazobactam 4 g/500 mg daily, clindamycin 600 mg q8 h/IV, and Levofloxacin 750 mg daily was prescribed.). Despite antibiotic class change and further investigations for the source of fever, the fever continued, preventing him to be discharged. On the 77th day of hospitalization, bronchoscopy was done due to prolonged, resistant fever. Thick corpus secretion

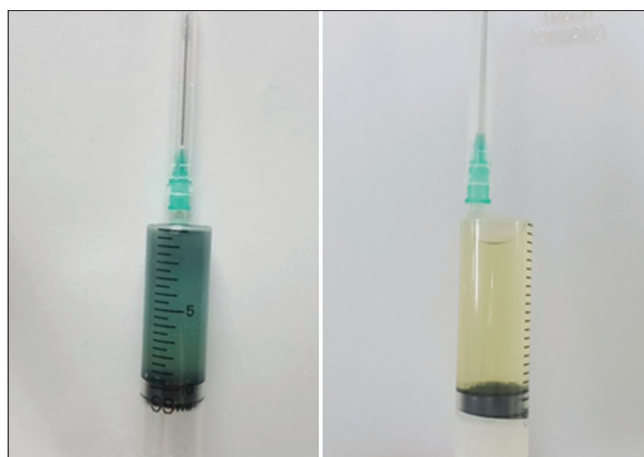

Figure 1: Sodium dithionite test on admission (on the left) and after the first hemodialysis (on the right)

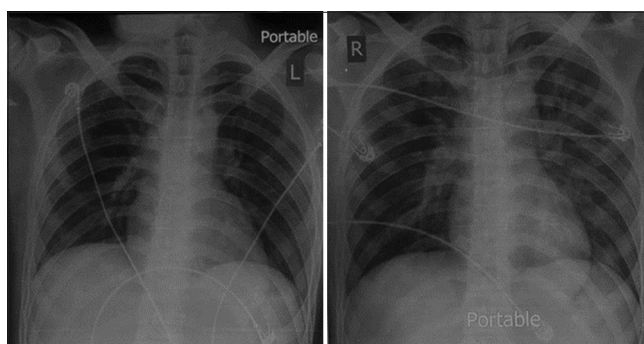


Figure 2: Chest radiography: on admission (on the left): normal and on the 5th day of admission (on the right): With diffuse fibrotic change and reticulonodular opacities in bilateral lungs

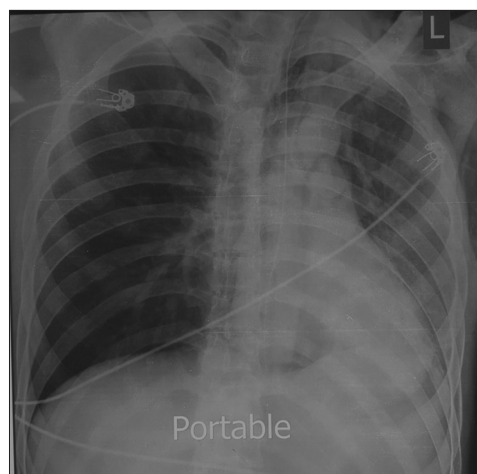


Figure 3: Chest radiography: with left-sided pneumothorax and left lung upper lobe atelectasis on the 6th day of admission

without intrabronchial lesion was reported, and according to bronchoalveolar lavage (BAL) culture, he was resistant to all of our available antibiotics except Colistin. Finally, due to prolonged fever and based on BAL culture, Colistin 10,000,000 IU q8 h was the only choice for our patient. On the 90th day of his hospitalization, he had a sudden decrease

in his GCS score. Emergent brain CT was done, and a large intracerebral hemorrhage (ICH) with midline shifting was seen. He prepared for an emergency neurosurgery operation, but his parents did not consent to the operation. Unfortunately, he died after 3 months of hospitalization.

Ethical consideration

Written informed consent was taken from the patient. All patient information, including name and address, was strictly confidential in this case report.

Discussion

This case is the first case, reports as paraquat injection in the neck, a very life-threatening site in the human body. Oral ulcers, hemoptysis, and gastrointestinal (GI) symptoms such as nausea, vomiting, diarrhea, and GI bleeding are the first symptoms in patients with oral ingestion. According to previous case reports, patients with parenteral paraquat poisoning might have some GI symptoms such as nausea and vomiting which may be explained by the systemic effect of paraquat on the CNS. Furthermore, these patients had local skin or vessel symptoms such as erythema and vesicles.^[4] However, our patient did not complain of nausea and vomiting and no skin abnormality was detected. While in a review literature, the systemic effects, such as CNS, renal, hepatic, or pulmonary damage, occur later than local effects and are suspected to be dose dependent and lethal,^[7] our patient was protected from renal and hepatic damage may be because of early hemodialysis but suffered from CNS and pulmonary damage.^[8] Several solutions for preventing lung injury were recommended including immunosuppressive therapy, vitamin E, deferoxamine, and N-acetyl cysteine. However, none of them improved our patient clinical course.^[4] While there is a study that reported developing epilepsy-like convulsions in five patients who consumed paraquat orally, to the best of our knowledge, the epilepsy-like convulsions have not been reported in recent parenteral paraquat poisoning reports.^[9] Our patient condition improved transiently at first days after poisoning; however, his condition eventually got worse and parallel complications such as pneumothorax and lung fibrosis, prolonged fever, and finally ICH were extremely rare events that occurred in this case. Despite all complications that occurred in our patient, the survival of our patient was even more than other parenteral paraquat poisoning that died during a period of 3–21 days after injection.^[4,5,10-12]

Conclusion

In this case, despite the high-risk route of poisoning, the patient survived for 3 months. A possible protective factor could be the hemodialysis that was done as soon as possible after admission. Although early hemodialysis had protective effects on the kidney, liver, and heart, it was not

effective for the protection of the brain and lung from the effects of the poison. Probably, the site of injection and long-term hospitalization are responsible for additional complications.

Acknowledgments

We wish to thank all doctors and nurses who work in the department of clinical toxicology of Noor hospital.

Declaration of patient consent

The authors certify that they have obtained all appropriate patient consent forms. In the form, the patient has given his consent for his images and other clinical information to be reported in the journal. The patient understands that name and initials will not be published and due efforts will be made to conceal identity, but anonymity cannot be guaranteed.

Financial support and sponsorship

Nil.

Conflicts of interest

There are no conflicts of interest.

References

- Phuinthiang P, Kajitvichyanukul P. Degradation of paraquat from contaminated water using green TiO₂ nanoparticles synthesized from *Coffea arabica* L. in photocatalytic process. *Water Sci Technol* 2019;79:905-10.
- Bismuth C, Garnier R, Baud FJ, Muszynski J, Keyes C. Paraquat poisoning. An overview of the current status. *Drug Saf* 1990;5(4):243-51.
- Almog C, Tal E. Death from paraquat after subcutaneous injection. *Br Med J* 1967;3:721.
- Chen HW, Tseng TK, Ding LW. Intravenous paraquat poisoning. *J Chin Med Assoc* 2009;72:547-50.
- Choi Y, Cho K, Yoon S, Lee H, Choi Y. A case of paraquat intoxication caused by intravenous injection. *Am J Emerg Med* 2008;26:836.e3-4.
- Fernando R. Survival of a patient after self-injection of paraquat and surgical excision of the injection site. *Ceylon Med J* 2015;60:66.
- Chen CW, Wu YH, Chien SC, Lin JC. A survival case of intravenous paraquat intoxication: A case report. *Medicine (Baltimore)* 2018;97:e11669.
- Yen TH, Wang IK, Hsu CW. Hemoperfusion for paraquat poisoning. *Kidney Int* 2018;94:1239.
- Huang C, Zhang X, Jiang Y, Li G, Wang H, Tang X, *et al.* Paraquat-induced convulsion and death: A report of five cases. *Toxicol Ind Health* 2013;29:722-7.
- Fernandez P, Bermejo AM, Lopez-Rivadulla M, Cruz A, Rodriguez E, Otero A. A fatal case of parenteral paraquat poisoning. *Forensic Sci Int* 1991;49:215-24.
- Hsu HH, Chang CT, Lin JL. Intravenous paraquat poisoning-induced multiple organ failure and fatality-A report of two cases: Case report. *J Toxicol Clin Toxicol* 2003;41:87-90.
- Elenga N, Merlin C, Le Guern R, Kom-Tchameni R, Ducrot YM, Pradier M, *et al.* Clinical features and prognosis of paraquat poisoning in French Guiana: A review of 62 cases. *Medicine (Baltimore)* 2018;97:e9621.

Supplementary Table 1: Supplementary lab findings

Analytes	Day							
	1	2	7	12	16	20	23	26
WBC	15,700	16,200	14,000	22,200	17,300	18,100	10,500	11,100
Hb	15.4	16.4	14.6	12.9	12.1	10	7.8	9.5
Plt	220,000	192,000	149,000	136,000	100,000	42,000	93,000	138,000
BUN	12	11.7	14.3	17.1	19.8	19.5	13.3	11
Cr	1	1.04	0.88	0.61	0.59	0.59	0.5	0.53
Na	142	140	136	NR	141	140	135	119
K	3.8	4.6	4.3	3.3	3.8	3.5	3.5	4.5
pH	7.42	7.36	7.5	7.4	7.51	7.4	7.5	7.4
pCO ₂	36	47	34.1	49.5	42.3	40.8	34.9	30.8
HCO ₃	23.6	24.3	28.1	32.5	32.1	29	24.5	24.8
PT	13	13.1	11.5	15.4	16.1	15.5	15.3	12.5
PTT	23	25.2	25	42.3	27	43.4	48	44.2
INR	1	1.01	1.03	1.5	1.38	1.31	1.2	1
AST	18	20	18	55	49	36	39	NR
ALT	11	11	15	53	137	70	65	NR
CPK	NR	NR	253	964	NR	79	94	51
LDH	NR	NR	597	767	NR	744	NR	NR

WBC: White blood cell, Hb: Hemoglobin, Plt: Platelet, BUN: Blood urine nitrogen, Cr: Creatinine, Na: Sodium, K: Potassium, PCO₂: Partial pressure of carbon dioxide, HCO₃: Bicarbonate, PT: Prothrombin time, PTT: Partial thromboplastin time, INR: International normalized ratio, AST: Aspartate aminotransferase, ALT: Alanine aminotransferase, CPK: Creatine phosphokinase, LDH: Lactate dehydrogenase, NR: Not requested