

# Genetic Risk Factors for Atypical Femoral Fractures (AFFs): A Systematic Review

Hanh H Nguyen,<sup>1,2\*</sup> Denise M van de Laarschot,<sup>3\*</sup> Annemieke JMH Verkerk,<sup>3</sup> Frances Milat,<sup>1,2,4</sup> M Carola Zillikens,<sup>3\*\*</sup> and Peter R Ebeling<sup>1,2\*\*</sup>

<sup>1</sup>Department of Medicine, School of Clinical Sciences, Monash University, Clayton, Australia

<sup>2</sup>Department of Endocrinology, Monash Health, Clayton, Australia

<sup>3</sup>Department of Internal Medicine, Erasmus Medical Centre, Rotterdam, The Netherlands

<sup>4</sup>Hudson Institute of Medical Research, Clayton, Australia

## ABSTRACT

Atypical femoral fractures (AFFs) are uncommon and have been associated particularly with long-term antiresorptive therapy, including bisphosphonates. Although the pathogenesis of AFFs is unknown, their identification in bisphosphonate-naïve individuals and in monogenetic bone disorders has led to the hypothesis that genetic factors predispose to AFF. Our aim was to review and summarize the evidence for genetic factors in individuals with AFF. We conducted structured literature searches and hand-searching of conference abstracts/reference lists for key words relating to AFF and identified 2566 citations. Two individuals independently reviewed citations for (i) cases of AFF in monogenetic bone diseases and (ii) genetic studies in individuals with AFF. AFFs were reported in 23 individuals with the following 7 monogenetic bone disorders (*gene*): osteogenesis imperfecta (*COL1A1/COL1A2*), pycnodysostosis (*CTSK*), hypophosphatasia (*ALPL*), X-linked osteoporosis (*PLS3*), osteopetrosis, X-linked hypophosphatemia (*PHEX*), and osteoporosis pseudoglioma syndrome (*LRP5*). In 8 cases (35%), the monogenetic bone disorder was uncovered after the AFF occurred. Cases of bisphosphonate-naïve AFF were reported in pycnodysostosis, hypophosphatasia, osteopetrosis, X-linked hypophosphatemia, and osteoporosis pseudoglioma syndrome. A pilot study in 13 AFF patients and 268 controls identified a greater number of rare variants in AFF cases using exon array analysis. A whole-exome sequencing study in 3 sisters with AFFs showed, among 37 shared genetic variants, a p.Asp188Tyr mutation in the *GGPS1* gene in the mevalonate pathway, critical to osteoclast function, which is also inhibited by bisphosphonates. Two studies completed targeted *ALPL* gene sequencing, an *ALPL* heterozygous mutation was found in 1 case of a cohort of 11 AFFs, whereas the second study comprising 10 AFF cases did not find mutations in *ALPL*. Targeted sequencing of *ALPL*, *COL1A1*, *COL1A2*, and *SOX9* genes in 5 cases of AFF identified a variant in *COL1A2* in 1 case. These findings suggest a genetic susceptibility for AFFs. A large multicenter collaborative study of well-phenotyped AFF cases and controls is needed to understand the role of genetics in this uncommon condition. © 2017 The Authors *JBMR Plus* published by Wiley Periodicals, Inc. on behalf of American Society for Bone and Mineral Research.

**KEY WORDS:** ATYPICAL FEMORAL FRACTURE; BISPHOSPHONATE; GENETIC FACTORS

## Introduction

There is currently a crisis in the treatment of osteoporosis, with a call to action by multiple international professional societies to aggressively reduce fracture risk in our aging population.<sup>(1)</sup> Despite the availability of effective antiresorptive osteoporosis drugs, namely bisphosphonates and denosumab, treatment rates after hip fracture—in patients at the highest risk for subsequent fractures—have halved from 40% in 2002 to 21% in 2011.<sup>(1)</sup> This crisis is driven by in large part by

fear of rare complications of antiresorptive drugs, such as atypical femoral fractures (AFFs) (Fig. 1).<sup>(2,3)</sup> Despite the significant burden of osteoporosis and fractures globally, since the first clinical reports of bisphosphonate-associated AFFs in 2005<sup>(4)</sup> and the subsequent FDA safety report in 2010,<sup>(5)</sup> there has been a 50% decline in the use of these effective osteoporosis therapies.<sup>(6)</sup>

Currently, the pathogenesis of AFFs is not known, but AFFs have also been described in individuals with monogenetic bone disorders and can occur in bisphosphonate-naïve individuals,

This is an open access article under the terms of the Creative Commons Attribution-NonCommercial License, which permits use, distribution and reproduction in any medium, provided the original work is properly cited and is not used for commercial purposes.

Received in original form August 17, 2017; revised form October 19, 2017; accepted October 27, 2017. Accepted manuscript online November 14, 2017.

Address correspondence to: Peter R Ebeling, AO, Department of Medicine, School of Clinical Sciences at Monash Health, Monash University, Level 5/Block E, Monash Medical Centre, 246 Clayton Road, Clayton, VIC 3168, Australia. E-mail: peter.ebeling@monash.edu

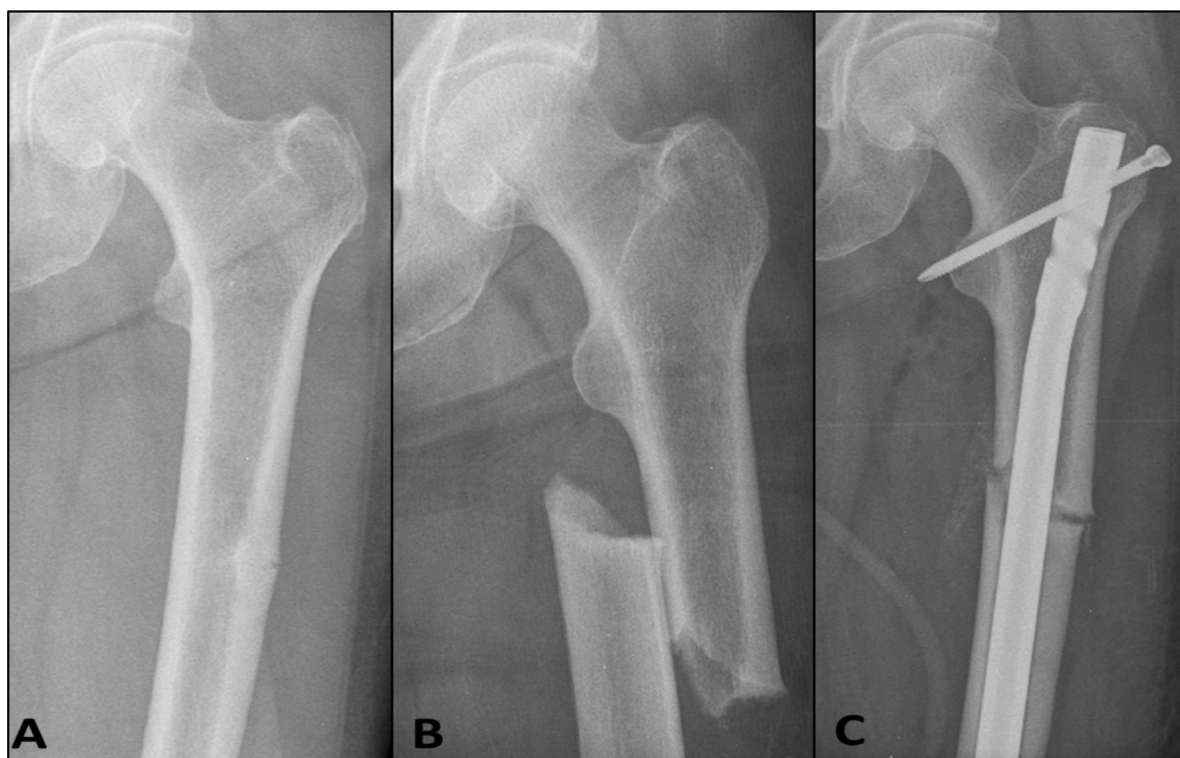\*HHN and DMvdL contributed equally to this work.

\*\*MCZ and PRE contributed equally to this work.

JBMR<sup>®</sup> Plus, Vol. 2, No. 1, January 2018, pp 1–11

DOI: 10.1002/jbm4.10024

© 2017 The Authors *JBMR Plus* published by Wiley Periodicals, Inc. on behalf of American Society for Bone and Mineral Research.



**Fig. 1.** X-ray series of a 61-year-old woman with postmenopausal osteoporosis presenting with prodromal left thigh pain in the setting of 11 years of alendronate therapy. An initial radiograph of the left femur demonstrated a transverse midshaft lateral stress fracture consistent with an incomplete atypical femoral fracture (A). After a minimal trauma fall, the fracture progressed to a complete fracture (B), and this required surgical fixation with an intramedullary nail (C). Reproduced from Nguyen et al. *Bone Rep.* 2017;6:34–7.

who comprise about 7% of cases.<sup>(2,3)</sup> As such, it is likely that genetic variants exist that predispose to AFFs. This article reviews and summarizes the evidence for genetic factors in individuals with AFFs after first discussing the epidemiology and clinical problem of this condition.

### Osteoporosis and anti-osteoporosis drugs

Osteoporosis is a condition with reduced bone strength due to abnormalities in the material composition and microstructure of bone predisposing to fractures. Hip fractures are catastrophic events resulting in chronic pain, disability, and increased mortality up to 35% within 12 months.<sup>(7)</sup> Bisphosphonates are well-established drugs for the management of osteoporosis. They are effective at reducing the risk of vertebral fractures by up to 70%<sup>(8)</sup> and also reduce nonvertebral and hip fractures.<sup>(9)</sup> They have been approved treatments for osteoporosis for more than 2 decades.

Bisphosphonates are structural analogs of inorganic pyrophosphate and inhibit bone resorption by binding avidly to bone mineral surfaces, are subsequently internalized by bone-resorbing osteoclasts, whereby they disrupt various biochemical processes.<sup>(10)</sup> In particular, nitrogen-containing bisphosphonates inhibit farnesyl pyrophosphate synthase, a key enzyme in the mevalonate pathway. This pathway is important for the biosynthesis of isoprenoids, molecules essential for multiple cellular processes. Disruption of this pathway affects osteoclast function and viability, ultimately resulting in reduced bone resorption.

### The problem of atypical femoral fractures

In 2005, Odvina and colleagues published the first case series of femoral shaft fractures associated with long-term bisphosphonate use and showed evidence of markedly suppressed bone formation on a bone biopsy.<sup>(4)</sup> A subsequent series of femoral fractures from Singapore in 2007<sup>(11)</sup> emphasized the unusual location of this fracture in the subtrochanteric region. This region (from just distal to the lesser trochanter to just proximal to the supracondylar flare of the femur) is notably resilient to traumatic injuries.<sup>(12)</sup> In 2010, the ASBMR convened an international Task Force to commission a report on and to create a case definition of AFF.<sup>(2)</sup> This case definition was subsequently revised in 2013 (Table 1).<sup>(3)</sup>

### Epidemiology and consequences of AFFs

In a population-based Swedish study including 12,777 women aged  $\geq 55$  years with femoral fractures, 59 AFFs were identified, of which 46 occurred in bisphosphonate users.<sup>(13)</sup> Linkage to the Swedish Prescribed Drug Register identified that 46 AFFs occurred in 83,311 women ever prescribed bisphosphonates in the preceding 3 years, whereas only 13 cases of bisphosphonate-naïve AFFs occurred out of 1,437,820 Swedish women aged  $\geq 55$  years who were not prescribed bisphosphonates. The age-adjusted relative risk of AFF with any use of bisphosphonates was 47.3.

Meier and colleagues found that the proportion of patients exposed to bisphosphonates was higher in patients with AFFs

**Table 1.** ASBMR TASK Force Revised Case Definition of AFFs

AFF must be located along the femoral diaphysis from just distal to the lesser trochanter to just proximal to the supracondylar flare. At least four of five Major Features must be present. No Minor Features are required.

Major features

- Minimal or no trauma as in a fall from a standing height or less
- The fracture line originates at the lateral cortex and is transverse, although it may become oblique as it progresses medially
- Complete fractures extend through both cortices and may be associated with a medial spike; incomplete fractures involve only the lateral cortex
- The fracture is non- or minimally comminuted
- Localized periosteal or endosteal thickening of the lateral cortex is present at the fracture site (“beaking” or “flaring”)

Minor features

- Generalized increase in cortical thickness of the femoral diaphyses
- Unilateral or bilateral prodromal symptoms such as dull or aching pain in the groin or thigh
- Bilateral incomplete or complete femoral diaphysis fractures
- Delayed fracture healing

than in those with non-atypical fractures (82.1% versus 6.4%).<sup>(14)</sup> The risk of AFF increases with longer duration of bisphosphonate exposure (1.8 per 100,000 cases per year after 0.1 to 1.9 years, rising to 113.1 per 100,000 cases per year for 8.0 to 9.0 years of use).<sup>(15)</sup> AFFs are also associated with a younger cohort,<sup>(16)</sup> Asian ethnicity,<sup>(17)</sup> a previous stress fracture of the contralateral femur,<sup>(14)</sup> and glucocorticoid use.<sup>(2)</sup>

Although the incidence of AFF is relatively low, the effect of a painful, spontaneous femoral fracture is devastating to the individual. In addition, up to 40% of AFFs occur in bilateral femora and delayed healing is common, resulting in prolonged immobilization. Prodromal pain occurs in more than 70%.<sup>(2)</sup>

### Pathophysiology: proposed mechanisms

Although the pathogenesis of AFFs remains largely unknown, its epidemiological association with bisphosphonate therapy led to several proposed mechanisms. Bisphosphonates alter collagen maturity and cross-linking, as indicated by the increase in pyridinoline (PYD)/deoxypyridinoline (DPD) ratio, increasing the strength but also stiffness of bone.<sup>(18,19)</sup> Moreover, reducing bone remodeling also increases pentosidine, which interacts with collagen through oxidative nonenzymatic cross-linkage, leading to advanced glycation end product accumulation, which results in reduced toughness. Both effects increase matrix stiffness and consequently reduce the peak-tolerated strain. The stiffening by increased matrix mineralization and pentosidine cross-linking reduces ductility; the structure becomes more brittle.<sup>(20,21)</sup>

Also, more homogeneously mineralized bone tissue facilitates fracture crack initiation and propagation.<sup>(22,23)</sup> Thus, remodeling suppression increases microfracture burden, allowing cracks to lengthen and reducing crack removal.<sup>(24,25)</sup> Microdamage accumulation may be further compounded by the preferential uptake of bisphosphonates at sites of high bone remodeling, including sites of stress fractures. Therefore, by suppressing remodeling at these local sites, bisphosphonates could potentially affect the intracortical repair of a developing stress fracture such as an AFF, allowing crack progression to a complete fracture.

Iliac crest bone biopsies from AFF cases showed reduced bone turnover in most cases, as would be expected with bisphosphonate treatment, but this has not been a universal finding.<sup>(2)</sup> In bone biopsies obtained close to the fracture site in AFF cases, both decreased and increased bone remodeling have

been described, although the latter may be influenced by the recent fracture and may not be indicative of the underlying pathogenic mechanism of AFFs.

### Hypotheses and aims

The rarity of AFFs amongst the millions of bisphosphonate users worldwide is suggestive of an individual susceptibility, which could be an underlying genetic predisposition.

The potential importance of genetic factors is supported by the occurrence of AFFs in bisphosphonate-naïve individuals.<sup>(13,26,27)</sup> Some of these bisphosphonate-naïve individuals were found to have an underlying monogenetic bone disease, such as hypophosphatasia, pycnodysostosis, osteopetrosis, X-linked hypophosphatemia (XLH), and osteoporosis pseudoglioma syndrome (OPPG), leading to the hypothesis that carriers of pathogenic mutations (very rare variants) or polymorphisms (common variants) in genes related to these monogenetic bone diseases may predispose to AFFs. Mild unrecognized forms of such heritable bone diseases may underlie the etiology of AFFs in some patients. Additionally, AFFs have been reported in patients with osteogenesis imperfecta (OI) and X-linked osteoporosis based on a *PLS3* mutation. Yet these cases may be related to the coexistent antiresorptive treatment rather than the underlying genetic condition, and no analysis has ever been done to investigate whether AFFs occur more frequently in patients with these genetic bone disorders. Even more suggestive of a genetic background of AFFs is the identification of 2 families with multiple family members with AFF.<sup>(28,29)</sup>

Furthermore, racial differences in risk and site of AFFs exist, which may be consistent with a genetic background. The age-adjusted relative risk for AFFs in Asians is 6.6 compared with white women corrected for current bisphosphonate use and duration of bisphosphonate treatment.<sup>(17)</sup> Schilcher and colleagues showed ethnic differences in location of the AFFs, with fractures mainly occurring in the subtrochanteric region in Singapore, compared with diaphyseal in Sweden.<sup>(30)</sup> The differences may be related to femoral geometric parameters that are more common in Asian women, such as increased femoral bowing and smaller neck-shaft angles.<sup>(31–34)</sup> Increased femoral curvature may lead to an altered distribution of loading with more tensile strain on the lateral side and more compression on the medial side of the femur. This imbalance of biomechanical stresses with increased femoral bowing might

contribute to spontaneous, transverse femoral fractures such as AFFs.<sup>(35)</sup>

We speculate that genetic factors may also interact with clinical risk factors for AFFs, including a high number of comorbid conditions, and concomitant medications, like glucocorticoids.<sup>(2)</sup>

The aim of this systematic review is to gather the data of AFF in relation to genetics and scrutinize the available evidence of genetic risk factors underlying the susceptibility for AFFs and to inform future directions for further research.

## Methods

We conducted a structured literature search of electronic databases, including Embase, Medline, Web of Science, Cochrane Central, and Google Scholar, and hand-searching of conference abstracts/reference lists using the following key words: femur/femoral fracture or subtrochanteric fracture, atypical and drug-induced disease, bisphosphonates, antiresorptives, and denosumab.

We identified 2566 citations, and authors HHN and DMvdL independently reviewed citations with the following inclusion criteria: (i) cases of AFFs in monogenetic bone diseases, and (ii) genetic studies in individuals with an AFF. Articles were only included if images of the femoral fracture were published and fulfilled the ASBMR case definition (Table 1) or if the authors used the recent ASBMR case definition to define the presence of AFFs. Twenty-six citations fulfilled the inclusion criteria and are described below. During preparation of this manuscript, two additional published articles and a conference abstract relevant to this topic were identified and also included in this review, making a total of 29 included studies.

## Results and Discussion

Reports of AFFs occurring in monogenetic bone disorders

Subtrochanteric femoral fractures fulfilling the ASBMR case definition of AFF were identified in 7 monogenetic bone disorders. These findings are summarized in Table 2 and explored further below.

The 7 bone disorders included primary defects in bone mineralization, bone remodeling, collagen synthesis and structure, and osteocyte function (Fig. 2). AFFs were also reported in juvenile forms of osteoporosis linked with long-term bisphosphonate use and may reflect a pediatric variant of bisphosphonate-associated AFF. These cases provide insight into the possible pathogenesis of AFFs and indicate potential candidate genes that may encode for variants predisposing to AFF. When dealing with bisphosphonate-naïve patients with AFFs, clinicians may need to carefully consider and exclude these underlying genetic conditions in their diagnostic assessment for secondary causes of skeletal fragility.

### Mineralization defect

**Hypophosphatasia:** The literature search identified 4 cases of AFFs occurring in adult hypophosphatasia,<sup>(36–39)</sup> in all of whom the genetic condition was unmasked after the femoral fracture. Three cases were bisphosphonate-naïve and in 1 case, reported by Sutton and colleagues, of bilateral atraumatic AFFs occurred simultaneously in a postmenopausal woman after 4 years of bisphosphonate therapy for osteoporosis.<sup>(38)</sup>

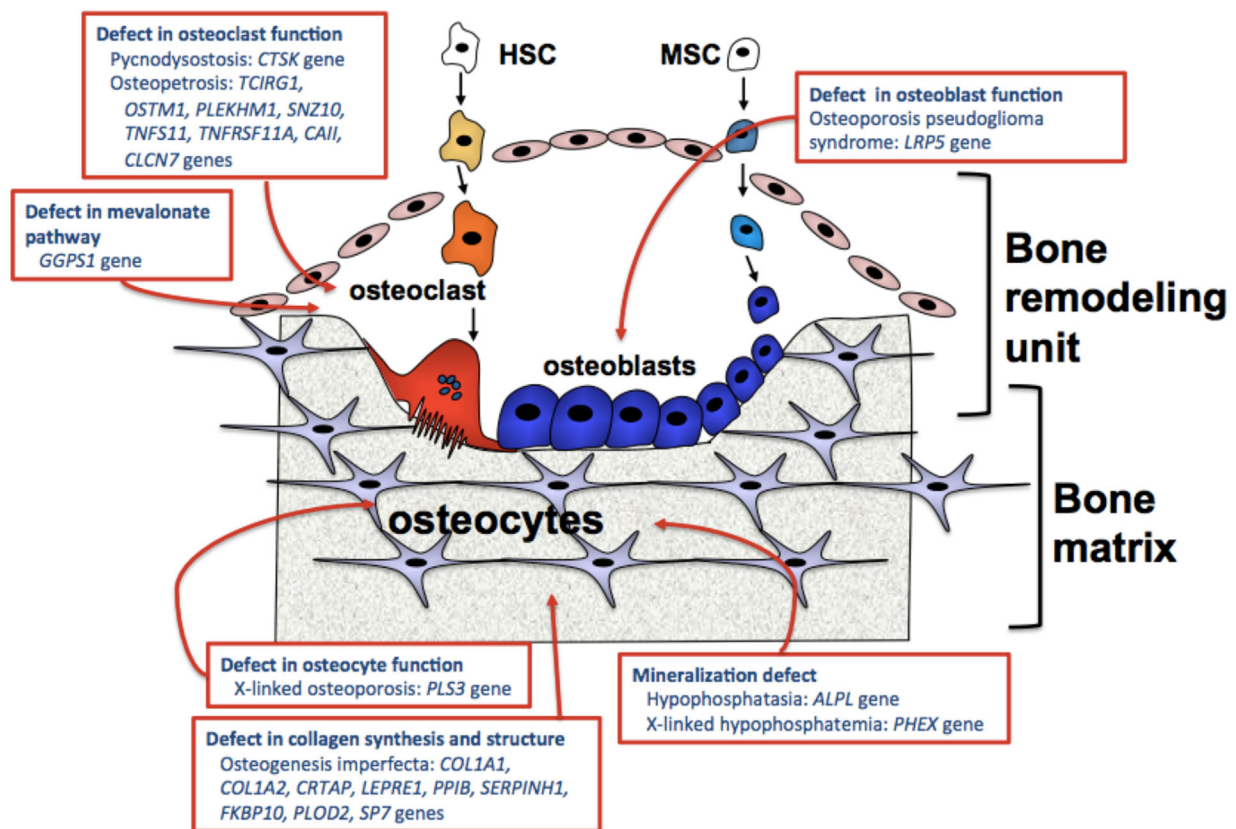
Hypophosphatasia is an inborn error of metabolism characterized by low alkaline phosphatase (ALP) levels, due to a loss-of-function mutation in the *ALPL* gene (also known as *TNSALP* gene) that encodes the tissue nonspecific ALP.<sup>(40)</sup> This defect in enzyme function leads to accumulation of substrates, such as inorganic pyrophosphate, pyridoxal 5' phosphate (active form of vitamin B6), and phosphoethanolamine. Inorganic pyrophosphate is an inhibitor of mineralization, and its accumulation in hypophosphatasia results in skeletal and dental manifestations.

The clinical spectrum of hypophosphatasia is broad and can range from severe lethal forms in infancy to mild forms in adulthood or with only dental complications (odontohypophosphatasia).<sup>(40)</sup> Skeletal manifestations in adulthood may include osteopenia, poorly healing stress fractures of the metatarsal bones, and pseudo-fractures. The pseudo-fractures commonly occur on the lateral side of the femoral shaft and can resemble bisphosphonate-associated AFFs.<sup>(41)</sup>

**Table 2.** List of Monogenetic Bone Disorders Associated With Atypical Femoral Fractures (AFFs)

Monogenetic bone disorder	Genes associated with disorder	Sex	Age (yrs)	Bilateral AFF	BP exposure	Disorder diagnosed following AFF
				<i>n</i>	<i>n</i>	<i>n</i>
<i>Hypophosphatasia</i> <sup>(36–39)</sup>	ALPL	4 F	50–55	4	1	4
<i>XLH</i> <sup>(41)</sup>	PHEX	1 M	27	0	0	0
<i>Pycnodysostosis</i> <sup>(44–49)</sup>	CTSK	3 M/4 F	23–55	3	0	2
<i>Osteopetrosis</i> <sup>(51–53)</sup>	TCIRG1, CLCN7, OSTM1, PLEKHM1, SNZ10, TNFS11, TNFRSF11A, CA11	4 F	21–56	2	0	1
<i>OPPG</i> <sup>(57)</sup>	LRP5	1 M	38	0	0	1
<i>OI</i> <sup>(61–65)</sup>	COL1A1/1A2, CRTAP, LEPRE1, PPIB, SERPINH1, FKBP10, PLOD2, SP7	4 F/1 M	11–75	2	5	0
<i>X-linked osteoporosis</i> <sup>(70)</sup>	PLS3	1 M	18	0	1	0

AFF = atypical femoral fracture, F = female, M = male, BP = bisphosphonate, XLH = X-linked hypophosphataemia, OPPG = osteoporosis pseudoglioma syndrome, OI = osteogenesis imperfecta.



**Fig. 2.** Genes implicated in atypical femoral fractures and their relationship to bone remodeling and bone matrix. HSC = hematopoietic stem cell; MSC = mesenchymal stem cell.

The similarity in the pseudo-fractures found in hypophosphatasia and the AFFs that occur in patients with osteoporosis treated with bisphosphonates may be explained by the fact that bisphosphonates are synthetic analogs of inorganic pyrophosphate resistant to ALP activity. There has been one case report of pyrophosphate accumulation at a site of a bisphosphonate-associated AFF.<sup>(42)</sup> Alternatively, the presence of AFFs found in bisphosphonate-naïve patients with hypophosphatasia may suggest that variants in the *ALPL* gene may be implicated in the pathogenesis of AFFs, independent of bisphosphonate exposure. Speculation also exists as to whether bisphosphonate therapy in individuals with mild forms of hypophosphatasia may precipitate AFFs. Targeted genetic testing of the *ALPL* gene in small cohorts of individuals with AFF have been conducted, and results will be described further below.

**X-linked hypophosphatemia (XLH):** Whyte and colleagues reported that pseudo-fractures in the lateral cortex of the femoral shaft can occur in XLH similar to AFFs.<sup>(41)</sup> In this report, a 27-year-old bisphosphonate-naïve male with XLH had radiological features of an incomplete AFF.

XLH is the most common form of hereditary rickets and is caused by loss-of-function mutations of the *PHEX* gene.<sup>(43)</sup> Biochemical findings in this condition are hypophosphatemia with renal phosphate wasting and associated inappropriately low 1,25-hydroxyvitamin D levels and high FGF-23 levels. Low bone mineral density, rickets, and/or osteomalacia with shortening and deformities of the lower limbs are common features of this condition.

#### Defect in bone remodeling

**Pycnodysostosis:** Subtrochanteric femoral fractures fulfilling criteria for AFFs have been described in 7 adult cases of pycnodysostosis. In 3 of these cases, pycnodysostosis was unmasked after the femoral fracture.<sup>(44–49)</sup> Five cases were bisphosphonate-naïve, whereas prior bisphosphonate use was unknown in the remaining 2 cases. Bilateral AFFs occurred in 4 cases of pycnodysostosis. Nakase and colleagues<sup>(45)</sup> reported delayed healing of the femoral shaft fracture of up to 3 years in 2 patients with pycnodysostosis.

Pycnodysostosis is a rare, autosomal recessive disorder of osteoclast function, characterized by short stature, osteosclerosis, pathological fractures with poor healing, acro-osteolysis of the terminal phalanges, and craniofacial dysmorphisms.<sup>(50)</sup> It is caused by mutations in the *CTSK* gene resulting in deficiency of cathepsin K activity. Cathepsin K is an enzyme that is highly expressed in osteoclasts and is responsible for degradation of bone matrix proteins during osteoclast-mediated bone resorption. The defect in osteoclast activity leads to osteosclerosis, increased bone density, abnormal bone matrix, and brittle bones, predisposing to pathological fractures of the long bones. Pycnodysostosis is managed symptomatically, and antiresorptive therapy has no place/is not indicated in this condition. The occurrence of AFFs in the absence of bisphosphonate use in pycnodysostosis, as described in these case reports, raises the possibility that genetic variants of the *CTSK* gene may predispose individuals to AFF.

**Osteopetrosis:** Our literature search identified 4 cases of AFFs occurring in bisphosphonate-naïve individuals with osteopetrosis, although the underlying mutated gene was not reported in these articles.<sup>(51–53)</sup> All authors described the surgical difficulties in the repair of the subtrochanteric femoral fractures in sclerotic bone.

Osteopetrosis is a class of rare heterogeneous genetic disorders characterized by high bone mass due to a failure of osteoclast-mediated bone resorption.<sup>(54)</sup> Mutations in 8 genes have been described, including *TCIRG1*, *OSTM1*, *PLEKHM1*, *SNZ10*, *TNFSF11*, *TNFRSF11A*, *C11orf119*, and *CLCN7*. Despite increased bone density, the sclerotic bone is brittle and fragility fractures occur,<sup>(55)</sup> and antiresorptive therapies are avoided in this condition. Other clinical features include craniofacial deformities, neurological compression from sclerotic bone, bone marrow failure due to reduction of bone marrow space, complications from extramedullary hematopoiesis, osteoarthritis, and dental complications.

**Osteoporosis pseudoglioma syndrome (OPPG):** OPPG is a rare, autosomal recessive form of juvenile osteoporosis caused by a loss-of-function mutation in the *LRP5* gene.<sup>(56)</sup> We identified a single case report of an AFF occurring in a 40-year-old bisphosphonate-naïve male with OPPG, who had multiple fragility fractures since childhood and evidence of low bone turnover on bone biopsy.<sup>(57)</sup> This is the only report of an AFF occurring in a genetic condition with primary osteoblast dysfunction. *LRP5* acts through the osteoblastic Wnt/ $\beta$ -catenin canonical signaling pathway to regulate bone formation.<sup>(56)</sup> Homozygous and compound heterozygous loss-of-function mutations in *LRP5* result in OPPG, whereas gain-of-function mutations in *LRP5* results in high bone mass. Common polymorphisms of *LRP5* can affect bone density in the general population.<sup>(58)</sup>

#### Defect in collagen synthesis and structure

**Osteogenesis imperfecta (OI):** OI is a heterogeneous, heritable connective tissue disorder with prominent skeletal features, including low bone mass, hypermineralized bone matrix, multiple fragility fractures, bone deformities, and short stature.<sup>(59)</sup> Bisphosphonates are widely used therapies in children and adults with this condition. However, in a recent Cochrane Review of bisphosphonate use in OI, the authors concluded that although bisphosphonates may improve bone mass, the evidence for long-term fracture reduction is unclear.<sup>(60)</sup>

To date, 4 case reports have been published describing classical AFFs in adults with OI.<sup>(61–64)</sup> All cases had prior bisphosphonate exposure. Vasanwala and colleagues reported bilateral AFFs in an 11-year-old female with OI after 5 years of pamidronate therapy,<sup>(65)</sup> representing the only reported case of classical AFFs occurring in a pediatric patient with OI.

Hegazy and colleagues published a case series of AFF occurring in 6 pediatric OI patients,<sup>(66)</sup> who all had prior long-term bisphosphonate therapy. However, the stress fractures occurred at periprosthetic sites and would technically be excluded from the ASBMR case definition. The occurrence of bisphosphonate-associated AFF in children raises the question of long-term safety of these drugs in pediatric populations.

A retrospective study by Nicolaou and colleagues demonstrated that a different pattern of femoral shaft fractures occurred in patients with OI and bisphosphonate use compared with a historical cohort of OI patients without bisphosphonate

therapy, with more fractures occurring in the proximal third of the femur in children treated with bisphosphonates, whereas mid-diaphyseal femoral fractures were more common in a control group without bisphosphonate exposure.<sup>(67)</sup>

OI is most often caused by defects in type 1 collagen synthesis (encoded by *COL1A1* and *COL1A2* genes), resulting in aberrant protein posttranslational modification, folding, intracellular transport, and bone matrix incorporation.<sup>(68)</sup> This either results in collagen protein deficiency or mutant collagen protein synthesis and leads to abnormal composition and organization of bone matrix, which increases bone stiffness and skeletal fragility.

Mice models suggest that skeletal microdamage levels are increased in OI, resulting in higher bone remodeling activity to target microcrack repair.<sup>(69)</sup> As bisphosphonates suppress bone remodeling and may impede microcrack repair, its use in patients with OI may result in even higher levels of microdamage accumulation and compromised bone toughness, predisposing to stress fracture development and AFF.

Although bisphosphonate treatment has been used to improve bone density in OI, they do not reverse the underlying impaired collagen defect. AFFs have been described in adult cases with OI and bisphosphonate exposure, whereas the risk of AFFs and the long-term safety of bisphosphonate use in pediatric populations remains unclear.

#### Defect in osteocyte function

**X-linked osteoporosis:** Our group has published a case report on an AFF occurring in an 18-year-old male with X-linked osteoporosis who had been treated with bisphosphonates for 9 years.<sup>(70)</sup> X-linked osteoporosis is a form of juvenile osteoporosis caused by pathogenic variants in *PLS3*, located on the X chromosome, encoding for the protein plastin 3.<sup>(71)</sup> Mutations in this gene have been associated with skeletal fragility in hemizygous males, whereas the clinical phenotype of heterozygous females may vary, ranging from normal bone mineral density and an absence of fractures to early-onset osteoporosis. Affected individuals can present in childhood with low bone density, vertebral compression fractures, and long bone fractures.<sup>(72)</sup> Although the exact mechanism through which *PLS3* mutations cause skeletal manifestations is unclear, decreased mechanosensing of osteocytes was proposed.<sup>(71)</sup> This is supported by a recent finding of altered osteocyte protein expression in low-turnover osteoporosis caused by mutations in *WNT1* and *PLS3*.<sup>(73)</sup> Similar to bisphosphonate use in pediatric cases of OI discussed previously, this case report of a bisphosphonate-associated AFF in an adolescent raises the concern of long-term safety of these agents in children.

#### Candidate gene studies

Three studies have been conducted to search for variants in selected genes in patients with AFFs. All 3 studies included *ALPL* mutation analysis, with 1 study also including *COL1A1*, *COL1A2*, and *SOX9* genes (Table 3).

Because inorganic pyrophosphate is a structural analog of bisphosphonates and femoral fractures with atypical features occur in cases of hypophosphatasia without prior antiresorptive therapy, it has been hypothesized that this condition is a genetic risk factor for AFF. The exact prevalence of mutations in the *ALPL* gene in the general population is unknown, but in the European population, it is estimated that the prevalence of

**Table 3. Genetic Studies in AFF Cohorts and Their Findings**

Author, year	Cases of AFF, n	Genetic analysis	Major findings
Roca-Ayats et al. 2017 <sup>(28)</sup>	6 (3 sisters)	Wholeexome sequencing	37 rare mutations in 34 genes were identified, including: GGPS1, CYP1A1, MVD, FN1, SYDE2, NGEF (The remaining 28 genes were not published)
Lau et al. 2017 <sup>(29)</sup>	2 sisters	Whole exome sequencing	Novel rare homozygous variant in CTSK gene (C.784 + 3A > C) was identified.
Perez-Nunez et al. 2015 <sup>(80)</sup>	13	Exon array analysis	Rare variants were more common in AFF cases compared to a control group (n = 268), and several rare variants tended to accumulate in AFF cases. Variants in 20 genes associated with AFF were identified: PPEF2, ACOXL, GGA3, LIPN, DOCK2, CCDC147, OR51T1, PCK2, CRYBB2, CXCR7, EDC3, SF3B3, SLC15A5, SLC2A6, FOXK2, CNGB1, NAT8B, HHAT, OR2L13, SYTL2
Funck-Brentano et al. 2016 <sup>(78)</sup>	5	ALPL, COL1A1, COL1A2, SOX9 gene sequencing	Heterozygous mutation in COL1A2 (c.213G > A; p. Arg708Gln) in 1 case
Bhattacharyya et al. 2016 <sup>(77)</sup>	10	ALPL gene sequencing	No mutations found
Sum et al. 2013 <sup>(75)</sup>	11	ALPL gene sequencing	Heterozygous mutation in ALPL gene (c.648 + 1G > A) in 1 case

mild forms of hypophosphatasia is 1:6300.<sup>(74)</sup> Carriers of mutations in the *ALPL* gene with a mild phenotype may be asymptomatic.

At the annual meeting of the ASBMR in 2013, an abstract was presented by Sum and colleagues<sup>(75)</sup> on prospective *ALPL* analysis in 11 patients with bisphosphonate-associated AFFs. All coding exons and adjacent splice sites were sequenced in these individuals. In 1 patient, a single mutation was found affecting the donor splice site in exon 6 that is reported in lethal infantile hypophosphatasia when associated with a second missense mutation on the other chromosome.<sup>(76)</sup> The patient was a 66-year-old woman with ALP levels between 33 and 40 U/L (range 35 to 129 U/L) while on bisphosphonate therapy. Bone mineral density was in the osteopenic range. Vitamin B6 status was not reported. The conclusion of this finding was that mutations of *ALPL* associated with subclinical hypophosphatasia may rarely result in bisphosphonate-associated AFFs.

In 2016, Bhattacharyya and colleagues<sup>(77)</sup> published on a retrospective case-control study that investigated hypophosphatasia as a risk factor for AFFs. Controls (n = 13) without an AFF had used bisphosphonates for at least 5 years. Patients (n = 10) had sustained a complete AFF while using bisphosphonates, and 3 patients were continuing bisphosphonate treatment. In both patients and controls, a standardized history, physical exam, and standing long leg radiographs were performed. Additionally, levels of ALP and pyridoxal 5' phosphate were measured. Participants withheld vitamin supplementation for at least 1 week before the blood test because this can affect pyridoxal 5' phosphate levels. DNA testing was performed in all patients with AFF (n = 10). Because of the high costs of genetic testing, analysis of *ALPL* was only performed in the controls who had low(-normal) serum ALP levels <60 U/L, which was found in 9 of 13. Serum ALP <50 U/L was considered abnormal in this study.

Mean ALP levels in AFF patients and controls were 58 U/L (range 37 to 73) and 56 U/L (38 to 74), respectively. Five of 10 AFF cases (50%) had an ALP level <50 U/L versus 5 of 13 controls (38%). Despite cessation of vitamin supplementation, pyridoxal 5'

phosphate level was elevated in 2 controls with low ALP who used multivitamins on a regular basis. No mutations of the *ALPL* gene were found in either the AFF patients or controls. Four different coding variants in the *ALPL* gene were found in patients and controls, which had an allele frequency of 0.1 or higher in a cohort with 4300 European American samples (Exome Variant Server, NHLBI GO Exome Sequencing Project (ESP), Seattle, WA, USA). Rare variants are usually defined by a minor allele frequency (MAF) <0.01, whereas variants with a MAF >0.05 are considered common and less common variants have a MAF of 0.01 to 0.05.

The 4 coding variants were found in equal frequencies in the AFF group versus the control group; rs1780316 (1.00 versus 0.94), rs3200254 (0.20 versus 0.17), rs3200255 (0.2 versus 0.17), and rs34605986 (0.10 versus 0.00). A post hoc analysis revealed that in this study a 40% prevalence of *ALPL* mutations in AFF patients would have been needed to detect a difference with 80% power.

These results suggest that the low ALP levels in this study population are most likely related to antiresorptive treatment rather than an underlying mild form of hypophosphatasia.

In this study, no evidence was found for hypophosphatasia as a risk factor for AFFs. However, considering the small sample size and ensuing lack of power in this study, *ALPL* cannot be ruled out as a potential susceptibility gene based on these results.

In a study by Funck-Brentano and colleagues in 2016,<sup>(78)</sup> the *ALPL*, *COL1A1*, *COL1A2*, and *SOX9* genes were sequenced in 4 females and 1 male with AFF. Fourteen AFF cases were identified by reviewing radiographs of patients with femoral fractures in three academic hospitals in France between 2007 and 2010, but only 5 patients gave consent for genetic testing. The rationale for *ALPL* and *COL1A1/1A2* testing in AFFs has been discussed above. *SOX9* plays a role in chondrocyte differentiation and regulation of the anti-Mullerian hormone (AMH). Mutations in this gene are associated with campomelic dysplasia, a syndrome characterized by skeletal malformations and sex reversal.

One patient carried a heterozygous missense mutation in *COL1A2* that was found in the NHLBI GO Exome Sequencing Project (ESP) with a MAF of 0.0008 (rs72658163; c.2123G>A;p.

Arg708Gln). Apart from short stature (146 cm), the 78-year-old patient had no specific physical features of Ol. Vertebral fracture status in this patient is not reported. She also had a single nucleotide polymorphism (SNP) in the *ALPL* gene that does not alter the protein (rs370212283; MAF 0.0002 in ESP). She had used risedronate for at least 5 years. The potential pathogenicity of the missense variant in *COL1A2* is unclear. Initially it was regarded as a pathogenic variant in Marfan syndrome or Ol. However, because this variant was also found in unaffected or mildly symptomatic family members, it was later considered not clinically relevant or possibly a genetic modifier, having small effects on the expression level of other, disease-causing genes. In cultured dermal fibroblasts of two unrelated heterozygous carriers of this variant, the diameter of the collagen fibrils was approximately 20% of control collagen fibrils.<sup>(79)</sup> This may imply that this variant affects connective tissue structure and is possibly involved in collagen-related disorders.

In another patient, six common variants of the *ALPL* gene were detected, including a nonprotein-altering variant, present in the Exome Aggregation Consortium (ExAC) with a MAF of 0.17 or higher (rs3200254; rs2275377; rs2275376; rs74063111; rs75829132; rs3200255). Another patient had a different nonprotein-altering variant in the *ALPL* gene (rs3200256; MAF 0.01 in ExAC). In 2 patients, no genetic variants were found. No variants were found in *COL1A1* and *SOX9*.

Although this was a small cohort study, genetic testing of 4 genes identified a previously reported mutation in *COL1A2* and common variants in the *ALPL* gene, supporting the hypothesis that AFF populations are enriched with variants in genes associated with monogenetic diseases.

### Exon array analysis

In a pilot study, Pérez-Núñez and colleagues<sup>(80)</sup> conducted an exon array analysis (Affymetrix Axion 2.0 exon array) in 13 women with AFFs and 268 controls that consisted of healthy women ( $n = 87$ ) and patients with postmenopausal osteoporosis without AFFs ( $n = 181$ ) (Table 3). By including the osteoporosis patients in the control group, the investigators intended to avoid the finding of osteoporosis-related variants rather than variants associated with AFFs. The analysis was restricted to variants with a minor allele frequency  $<0.03$  in the overall study population. Twenty-one SNPs in 20 genes were defined as risk variants based on the arbitrary threshold of a  $p$  value  $< 0.0025$ . However, only one variant remained statistically significant after correction for multiple testing, a missense variant in the *PPEF2* gene, which has no known function in bone metabolism. The distribution of these less common variants in cases and controls was statistically significantly different. In 12 of 13 AFF cases, three or more risk variants were present. In 15.7% ( $n = 42$ ) of the control group, one risk variant was present, but none of the controls had more than one risk variant. The genes involved are not linked to known bone disorders, although the authors suggested that a possibly damaging missense variant in the *HHAT* gene, belonging to the hedgehog protein family, may be connected to developmental bone defects, while another possibly damaging missense variant in the *CXCR7* gene (also known as *ACKR3*) modulates the activity of precursor osteoblasts. These findings indicate that several variants combined may be associated with (a higher risk of) AFF. Based on these results, the authors concluded that AFFs have a polygenic background. However, this study is also limited by a small sample size and lack of functional studies to understand the potential mechanisms leading to AFF.

### Whole-exome sequencing

To date, only one study has been published on whole-exome sequencing in patients with bisphosphonate-associated AFFs<sup>(28)</sup> (Table 3). Exome sequencing may lead to the discovery of yet unknown genetic variants related to the risk of AFFs, although potential susceptibility variants for AFFs in noncoding regions and regulatory areas of the genome may still be missed.

In a recent letter to the editor by Roca-Ayats and colleagues,<sup>(28)</sup> results were presented of a whole-exome sequencing study in 3 sisters with bisphosphonate-associated AFFs and in 3 unrelated patients with AFF after long-term bisphosphonate treatment. Rare, protein-altering mutations shared only by the 3 sisters were considered in this analysis. A dominant model was assumed by the authors. In total, 37 rare mutations were detected in 34 genes including a novel missense variant (p.Asp188Tyr) in geranylgeranyl diphosphate synthase 1 (*GGPS1*), a gene encoding for the enzyme geranylgeranyl pyrophosphate synthase (GGPPS). GGPPS catalyzes the formation of geranylgeranyl pyrophosphate in the mevalonate pathway. This novel variant is expected to severely impair GGPPS enzyme activity, potentially impairing osteoclast function (Fig. 2). However, when the mutation in *GGPS1* is believed to decrease osteoclast function, it might also be expected that the siblings have a high bone mineral density and an osteopetrosis-like phenotype, which is not evident from the case description in this letter.

In addition, the authors describe a mutation of the gene encoding *CYP11A1* in the 3 sisters and in 1 unrelated patient with AFF. Also, in 1 unrelated patient with an AFF, they identified a mutation encoding mevalonate diphosphate decarboxylase (*MVD*). Pathway analysis of the mutated genes showed enrichment of the isoprenoid biosynthesis, which proceeds through the mevalonate pathway in humans, including *GGPS1*, *CYP11A1*, and *MVD*.

According to Roca-Ayats and colleagues, missense changes in the *FN1*, *SYDE2*, and *NGEF* genes might also be relevant variants. However, the authors do not discuss the potential mechanism of action of these variants with regard to the pathophysiology of AFFs. An overview of all found rare variants is not presented in this letter. Replication of the novel *GGPS1* mutation and the other 36 genetic variants in other cases of AFFs could provide evidence that 1 or more of these variants are potential susceptibility genes for AFFs. Otherwise, several variants may only be a result of shared DNA amongst the 3 siblings.

It is also possible that the *GGPS1* is a private mutation in this family and related to the underlying bone disease, not necessarily to the AFFs. However, it is plausible that the mutation is related to AFFs because the mevalonate pathway is believed to be inhibited by bisphosphonates containing a nitrogen side-chain, such as alendronate, risedronate, and zoledronate. The novel *GGPS1* variant would possibly disrupt a binding site for magnesium of the GGPPS enzyme so that binding of farnesyl pyrophosphate and catalysis are disturbed. Blocking the farnesyl diphosphate synthase in this pathway induces the apoptosis of osteoclasts, decreasing bone resorption. In theory, this mutation could lead to a further accumulation of the mevalonate pathway substrate, isopentenyl pyrophosphate. In the literature, this substrate may indirectly activate T lymphocytes and is considered the cause of bisphosphonate-induced acute phase reaction in patients on intravenous treatment.<sup>(81,82)</sup> It has been suggested that this



mechanism may result in chronic immune stimulation and compromised immunity in patients on long-term bisphosphonate therapy, which may contribute to another bisphosphonate-associated adverse event, such as osteonecrosis of the jaw.<sup>(81,82)</sup>

Whole-exome sequencing in another family of AFFs was presented in an abstract at the Australian New Zealand Bone & Mineral Society Annual Meeting in 2017<sup>(29)</sup> (Table 3). Lau and colleagues described a consanguineous family in whom three siblings sustained bilateral AFFs without a history of bisphosphonate exposure. Whole-exome sequencing of two siblings revealed a novel homozygous variant in the splice site of exon 6 of the cathepsin K gene (*CTSK*) (c.784+3A>C), with a variant frequency of 0.0000577. Mutations in *CTSK* are associated with pycnodysostosis, and although the authors reported that the proband had short stature and high bone mass (*T*-scores of +2.02 at the femoral neck and +2.75 at the lumbar spine), the proband had no other dysmorphic, clinical, or radiographic features to suggest this condition. This finding supports our hypothesis that individuals who sustain AFFs may carry a rare variant associated with a monogenetic bone disorder.

## Conclusion

Although AFFs are rare fractures associated with antiresorptive therapy, fear of this complication has been linked to the poor uptake of this effective treatment for osteoporosis. The pathogenesis of AFFs has not yet been elucidated, and the future challenge lies in improving our understanding of the association with antiresorptive therapy and the predisposing risk factors, including genetic factors, in order to prevent these fractures from occurring.

Here we summarize the evidence for genetic factors in AFFs. These fractures can occur in patients with monogenetic bone diseases, even without prior bisphosphonate exposure and in some cases unmasking the underlying condition. Targeted sequencing of some of these genes in AFF populations have identified variants in *CTSK*, *COL1A2*, and *ALPL* genes, and we propose that mild, unrecognized forms of such monogenetic bone diseases may underlie the etiology of AFFs. Further, whole-exome sequencing and exon array analysis of AFF cohorts have identified novel genes that may predispose to AFFs, including genes related to the mevalonate pathway. These findings provide new insights into the pathogenesis of AFF. It is important that these initial findings can be replicated in future studies, in order to determine the exact genetic architecture of this rare complication. Consequently, a simple genetic test can be developed with all potential susceptibility variants involved. This test could be used to screen patients before prescribing (long-term) treatment with bisphosphonates or denosumab.

Identification of susceptibility genes predisposing to AFFs may provide a solution in detecting patients at greatest risk of AFFs by genetic testing, for whom alternative anabolic treatment should be recommended. To date, genetic studies in AFF cases have comprised small cohorts. An international, multicentered collaborative study of well-phenotyped AFF cases and controls is needed to detect rare variants associated with AFFs, as well as common variants in multiple genes. This would enable future targeting of antiresorptive therapy to those with low AFF risk.

## Disclosures

PRE is Editor-in-Chief of *JBMR Plus*. All other authors state that they have no conflicts of interest.

## Acknowledgments

The authors acknowledge Wichor Bramer, Biomedical Information Specialist of the Medical Library of Erasmus Medical Centre, for his assistance with the systematic literature search.

Authors' roles: Study design and first draft: HHN, DMvdL, MCZ, and PRE. Systematic literature review: HHN, and DMvdL. Revision of manuscript: AJMHV, FM, MCZ, and PRE.

## References

1. Khosla S, Shane E. A crisis in the treatment of osteoporosis. *J Bone Miner Res*. 2016;31(8):1485–7.
2. Shane E, Burr D, Ebeling PR, et al. Atypical subtrochanteric and diaphyseal femoral fractures: report of a task force of the American Society for Bone and Mineral Research. *J Bone Miner Res*. 2010;25(11):2267–94.
3. Shane E, Burr D, Abrahamsen B, et al. Atypical subtrochanteric and diaphyseal femoral fractures: second report of a task force of the American Society for Bone and Mineral Research. *J Bone Miner Res*. 2014;29(1): 1–23.
4. Odvina CV, Zerwekh JE, Rao DS, Maalouf N, Gottschalk FA, Pak CY. Severely suppressed bone turnover: a potential complication of alendronate therapy. *J Clin Endocrinol Metab*. 2005;90(3):1294–301.
5. Kim SC, Kim DH, Mogun H, et al. Impact of the U.S. Food and Drug Administration's safety-related announcements on the use of bisphosphonates after hip fracture. *J Bone Miner Res*. 2016;31(8): 1536–40.
6. Jha S, Wang Z, Laucis N, Bhattacharyya T. Trends in media reports, oral bisphosphonate prescriptions, and hip fractures 1996–2012: an ecological analysis. *J Bone Miner Res*. 2015;30(12):2179–87.
7. Cummings SR, Melton LJ. Epidemiology and outcomes of osteoporotic fractures. *Lancet* (London, England). 2002;359(9319):1761–7.
8. Black DM, Delmas PD, Eastell R, et al. Once-yearly zoledronic acid for treatment of postmenopausal osteoporosis. *N Engl J Med*. 2007;356(18):1809–22.
9. Wells GA, Cranney A, Peterson J, et al. Alendronate for the primary and secondary prevention of osteoporotic fractures in postmenopausal women. *Cochrane Database Syst Rev*. 2008(1):CD001155.
10. Russell GG. Bisphosphonates: mode of action and pharmacology. *Pediatrics*. 2007;119:S150–62.
11. Goh SK, Yang KY, Koh JS, et al. Subtrochanteric insufficiency fractures in patients on alendronate therapy: a caution. *J Bone Joint Surg Br*. 2007;89(3):349–53.
12. Salminen S, Pihlajamäki H, Avikainen V, Kyro A, Bostman O. Specific features associated with femoral shaft fractures caused by low-energy trauma. *J Trauma*. 1997;43(1):117–22.
13. Schilcher J, Michaëlsson K, Aspenberg P. Bisphosphonate use and atypical fractures of the femoral shaft. *N Engl J Med*. 2011;364(18):1728–37.
14. Meier RP, Perneger TV, Stern R, Rizzoli R, Peter RE. Increasing occurrence of atypical femoral fractures associated with bisphosphonate use. *Arch Intern Med*. 2012;172(12):930–6.
15. Dell RM, Adams AL, Greene DF, et al. Incidence of atypical nontraumatic diaphyseal fractures of the femur. *J Bone Miner Res*. 2012;27(12):2544–50.
16. Feldstein AC, Black D, Perrin N, et al. Incidence and demography of femur fractures with and without atypical features. *J Bone Miner Res*. 2012;27(5):977–86.
17. Lo JC, Hui RL, Grimsrud CD, et al. The association of race/ethnicity and risk of atypical femur fracture among older women receiving oral bisphosphonate therapy. *Bone*. 2016;85:142–7.

18. Tang SY, Zeenath U, Vashishth D. Effects of non-enzymatic glycation on cancellous bone fragility. *Bone*. 2007;40(4):1144–51.
19. Allen MR, Gineyts E, Leeming DJ, Burr DB, Delmas PD. Bisphosphonates alter trabecular bone collagen cross-linking and isomerization in beagle dog vertebra. *Osteoporos Int*. 2008;19(3):329–37.
20. Nalla RK, Kruzic JJ, Kinney JH, Ritchie RO. Effect of aging on the toughness of human cortical bone: evaluation by R-curves. *Bone*. 2004;35(6):1240–6.
21. Tjhia CK, Odvina CV, Rao DS, Stover SM, Wang X, Fyhrie DP. Mechanical property and tissue mineral density differences among severely suppressed bone turnover (SSBT) patients, osteoporotic patients, and normal subjects. *Bone*. 2011;49(6):1279–89.
22. Donnelly E, Meredith DS, Nguyen JT, et al. Reduced cortical bone compositional heterogeneity with bisphosphonate treatment in postmenopausal women with intertrochanteric and subtrochanteric fractures. *J Bone Miner Res*. 2012;27(3):672–8.
23. Karim L, Vashishth D. Role of trabecular microarchitecture in the formation, accumulation, and morphology of microdamage in human cancellous bone. *J Orthop Res*. 2011;29(11):1739–44.
24. Mashiba T, Hirano T, Turner CH, Forwood MR, Johnston CC, Burr DB. Suppressed bone turnover by bisphosphonates increases microdamage accumulation and reduces some biomechanical properties in dog rib. *J Bone Miner Res*. 2000;15(4):613–20.
25. Chapurlat RD, Arlot M, Burt-Pichat B, et al. Microcrack frequency and bone remodeling in postmenopausal osteoporotic women on long-term bisphosphonates: a bone biopsy study. *J Bone Miner Res*. 2007;22(10):1502–9.
26. Tan SC, Koh SBJ, Goh SK, Sen Howe T. Atypical femoral stress fractures in bisphosphonate-free patients. *Osteoporos Int*. 2011;22(7):2211–2.
27. Szolomayer LK, Ibe IK, Lindskog DM. Bilateral atypical femur fractures without bisphosphonate exposure. *Skelet Radiol*. 2017;46(2):241–7.
28. Roca-Ayats N, Balcells S, Garcia-Giral N, et al. GGPS1 mutation and atypical femoral fractures with bisphosphonates. *N Engl J Med*. 2017;376(18):1794–5.
29. Lau S, McInerney-Leo AM, Lanoda-Bassonga E, et al. Homozygous variant in Cathepsin K in a family with multiple cases of bilateral atypical femoral fracture but without clinical features of pycnodysostosis, abs# 87. Abstracts from the Combined 2017 Meeting of the Australian and New Zealand Bone and Mineral Society (ANZBMS) and the International Federation of Musculoskeletal Research Societies (IFMRS), in Conjunction With the Japanese Society for Bone and Mineral Research (JSBMR); Brisbane, Australia; June 17–21, 2017.
30. Schilcher J, Howe TS, Png MA, Aspenberg P, Koh JS. Atypical fractures are mainly subtrochanteric in Singapore and diaphyseal in Sweden: a cross-sectional study. *J Bone Miner Res*. 2015;30(11):2127–32.
31. Mahjoub Z, Jean S, Leclerc JT, et al. Incidence and characteristics of atypical femoral fractures: clinical and geometrical data. *J Bone Miner Res*. 2016;31(4):767–76.
32. Hagen JE, Miller AN, Ott SM, et al. Association of atypical femoral fractures with bisphosphonate use by patients with varus hip geometry. *J Bone Joint Surg Am*. 2014;96(22):1905–9.
33. Sasaki S, Miyakoshi N, Hongo M, Kasukawa Y, Shimada Y. Low-energy diaphyseal femoral fractures associated with bisphosphonate use and severe curved femur: a case series. *J Bone Miner Metab*. 2012;30(5):561–7.
34. Taormina DP, Marciano AI, Karia R, Egol KA, Tejwani NC. Symptomatic atypical femoral fractures are related to underlying hip geometry. *Bone*. 2014;63:1–6.
35. Martelli S, Pivonka P, Ebeling PR. Femoral shaft strains during daily activities: implications for atypical femoral fractures. *Clin Biomech (Bristol, Avon)*. 2014;29(8):869–76.
36. Gagnon C, Sims NA, Mumm S, et al. Lack of sustained response to teriparatide in a patient with adult hypophosphatasia. *J Clin Endocrinol Metab*. 2010;95(3):1007–12.
37. Maman E, Briot K, Roux C. Atypical femoral fracture in a 51-year-old woman: revealing a hypophosphatasia. *Joint Bone Spine*. 2016;83(3):346–8.
38. Sutton RAL, Mumm S, Coburn SP, Ericson KL, Whyte MP. “Atypical femoral fractures” during bisphosphonate exposure in adult hypophosphatasia. *J Bone Miner Res*. 2012;27(5):987–94.
39. Doshi KB, Hamrahian AH, Licata AA. Teriparatide treatment in adult hypophosphatasia in a patient exposed to bisphosphonate: a case report. *Clin Cases Miner Bone Metab*. 2009;6(3):266–9.
40. Whyte MP. Hypophosphatasia—etiology, nosology, pathogenesis, diagnosis and treatment. *Nat Rev Endocrinol*. 2016;12(4):233–46.
41. Whyte MP. Atypical femoral fractures, bisphosphonates, and adult hypophosphatasia. *J Bone Miner Res*. 2009;24(6):1132–4.
42. Shabestari M, Eriksen EF, Paschalis EP, et al. Presence of pyrophosphate in bone from an atypical femoral fracture site: a case report. *Bone Rep*. 2017;6:81–6.
43. Fuente R, Gil-Pena H, Claramunt-Taberner D, et al. X-linked hypophosphatemia and growth. *Rev Endocr Metab Disord*. 2017;18(1):107–15.
44. Kundu ZS, Marya KM, Devgan A, Yadav V, Rohilla S. Subtrochanteric fracture managed by intramedullary nail in a patient with pycnodysostosis. *Joint Bone Spine*. 2004;71(2):154–6.
45. Nakase T, Yasui N, Hiroshima K, et al. Surgical outcomes after treatment of fractures in femur and tibia in pycnodysostosis. *Arch Orthop Trauma Surg*. 2007;127(3):161–5.
46. Yates CJ, Bartlett MJ, Ebeling PR. An atypical subtrochanteric femoral fracture from pycnodysostosis: a lesson from nature. *J Bone Miner Res*. 2011;26(6):1377–9.
47. Hashem J, Krochak R, Culbertson MD, Mileto C, Goodman H. Atypical femur fractures in a patient with pycnodysostosis: a case report. *Osteoporos Int*. 2015;26(8):2209–12.
48. Yuasa T, Maeda K, Kaneko K, Yoshikata K. Total hip arthroplasty after treatment of an atypical subtrochanteric femoral fracture in a patient with pycnodysostosis. *Case Rep Orthop*. 2015;2015:731910.
49. Song HK, Sohn YB, Choi YJ, Chung YS, Jang JH. A case report of pycnodysostosis with atypical femur fracture diagnosed by next-generation sequencing of candidate genes. *Medicine*. 2017;96(12):e6367.
50. Xue Y, Cai T, Shi S, et al. Clinical and animal research findings in pycnodysostosis and gene mutations of cathepsin K from 1996 to 2011. *Orphanet J Rare Dis*. 2011;6:20.
51. Birmingham P, McHale KA. Case reports: treatment of subtrochanteric and ipsilateral femoral neck fractures in an adult with osteopetrosis. *Clin Orthop Relat Res*. 2008;466(8):2002–8.
52. Amit S, Shekhar A, Vivek M, Shekhar S, Biren N. Fixation of subtrochanteric fractures in two patients with osteopetrosis using a distal femoral locking compression plate of the contralateral side. *Eur J Trauma Emerg Surg*. 2010;36(3):263–9.
53. Kubaraci M, Karapinar L, Incesu M, Kaya A. Treatment of bilateral simultaneous subtrochanteric femur fractures with proximal femoral nail antitraction (PFNA) in a patient with osteopetrosis: case report and review of the literature. *J Orthop Sci*. 2013;18(3):486–9.
54. Coudert AE, de Vernejoul MC, Muraca M, Del Fattore A. Osteopetrosis and its relevance for the discovery of new functions associated with the skeleton. *Int J Endocrinol*. 2015;2015:372156.
55. Sobacchi C, Schulz A, Coxon FP, Villa A, Helfrich MH. Osteopetrosis: genetics, treatment and new insights into osteoclast function. *Nat Rev Endocrinol*. 2013;9(9):522–36.
56. Gong Y, Slee RB, Fukai N, et al. LDL receptor-related protein 5 (LRP5) affects bone accrual and eye development. *Cell*. 2001;107(4):513–23.
57. Alonso N, Soares DC, V McCloskey E, Summers GD, Ralston SH, Gregson CL. Atypical femoral fracture in osteoporosis pseudoglioma syndrome associated with two novel compound heterozygous mutations in LRP5. *J Bone Miner Res*. 2015;30(4):615–20.
58. van Meurs JB, Trikalinos TA, Ralston SH, et al. Large-scale analysis of association between LRP5 and LRP6 variants and osteoporosis. *JAMA*. 2008;299(11):1277–90.
59. Forlino A, Cabral WA, Barnes AM, Marini JC. New perspectives on osteogenesis imperfecta. *Nat Rev Endocrinol*. 2011;7(9):540–57.
60. Dwan K, Phillip CA, Steiner RD, Basel D. Bisphosphonate therapy for osteogenesis imperfecta. *Cochrane Database System Rev*. 2016;10:CD005088.

61. Meier RPH, Lorenzini KI, Uebelhart B, Stern R, Peter RE, Rizzoli R. Atypical femoral fracture following bisphosphonate treatment in a woman with osteogenesis imperfecta: a case report. *Acta Orthop.* 2012;83(5): 548–50.
62. Manolopoulos KN, West A, Gittoes N. The paradox of prevention—bilateral atypical subtrochanteric fractures due to bisphosphonates in osteogenesis imperfecta. *J Clin Endocrinol Metab.* 2013;98(3): 871–2.
63. Holm J, Eiken P, Hyldstrup L, Jensen JEB. Atypical femoral fracture in an osteogenesis imperfecta patient successfully treated with teriparatide. *Endocr Pract.* 2014;20(10):e187–e90.
64. Etxebarria-Foronda I, Carpintero P. An atypical fracture in male patient with osteogenesis imperfecta. *Clin Cases Miner Bone Metab.* 2015;12(3):278–81.
65. Vasanwala RF, Sanghrajka A, Bishop NJ, Högl W. Recurrent proximal femur fractures in a teenager with osteogenesis imperfecta on continuous bisphosphonate therapy: are we overtreating? *J Bone Miner Res.* 2016;31(7):1449–54.
66. Hegazy A, Kenaway M, Sochett E, Tile L, Cheung AM, Howard AW. Unusual femur stress fractures in children with osteogenesis imperfecta and intramedullary rods on long-term intravenous pamidronate therapy. *J Pediatr Orthop.* 2016;36(7):757–61.
67. Nicolaou N, Agrawal Y, Padman M, Fernandes JA, Bell MJ. Changing pattern of femoral fractures in osteogenesis imperfecta with prolonged use of bisphosphonates. *J Child Orthop.* 2012;6(1):21–7.
68. Forlino A, Marini JC. Osteogenesis imperfecta. *Lancet (London, England).* 2016;387(10028):1657–71.
69. Davis MS, Kovacic BL, Marini JC, Shih AJ, Kozloff KM. Increased susceptibility to microdamage in *Brtl*/+ mouse model for osteogenesis imperfecta. *Bone.* 2012;50(3):784–91.
70. van de Laarschot DM, Zillikens MC. Atypical femur fracture in an adolescent boy treated with bisphosphonates for X-linked osteoporosis based on *PLS3* mutation. *Bone.* 2016;91:148–51.
71. van Dijk FS, Zillikens MC, Micha D, et al. *PLS3* mutations in X-linked osteoporosis with fractures. *N Engl J Med.* 2013;369(16):1529–36.
72. Fahiminiya S, Majewski J, Al-Jallad H, et al. Osteoporosis caused by mutations in *PLS3*: clinical and bone tissue characteristics. *J Bone Miner Res.* 2014;29(8):1805–14.
73. Wesseling-Perry K, Makitie RE, Valimaki VV, et al. Osteocyte protein expression is altered in low-turnover osteoporosis caused by mutations in *WNT1* and *PLS3*. *J Clin Endocrinol Metab.* 2017;102(7):2340–8.
74. Mornet E, Yvard A, Taillandier A, Fauvert D, Simon-Bouy B. A molecular-based estimation of the prevalence of hypophosphatasia in the European population. *Ann Hum Genet.* 2011;75(3):439–45.
75. Sum M, Huskey M, Diemer K, et al. *TNSALP* mutation analysis in women with atypical femoral fracture and bisphosphonate therapy for osteoporosis. *J Bone Miner Res.* 2013;28.
76. Sergi C, Mornet E, Troeger J, Voigtlaender T. Perinatal hypophosphatasia: radiology, pathology and molecular biology studies in a family harboring a splicing mutation (648+1A) and a novel missense mutation (N400S) in the tissue-nonspecific alkaline phosphatase (*TNSALP*) gene. *Am J Med Genet.* 2001;103(3):235–40.
77. Bhattacharyya T, Jha S, Wang H, Kastner DL, Remmers EF. Hypophosphatasia and the risk of atypical femur fractures: a case-control study. *BMC Musculoskelet Disord.* 2016;17(1):1–4.
78. Funck-Brentano T, Ostertag A, Debiais F, et al. Identification of a p. Arg708Gln variant in *COL1A2* in atypical femoral fractures. *Joint Bone Spine.* 2017;84(6):715–8.
79. Vomund AN, Braddock SR, Krause GF, Phillips CL. Potential modifier role of the R618Q variant of pro $\alpha$ 2(I)collagen in type I collagen fibrillogenesis: in vitro assembly analysis. *Mol Genet Metab.* 2004;82(2):144–53.
80. Pérez-Núñez I, Pérez-Castrillón JL, Zarrabeitia MT, et al. Exon array analysis reveals genetic heterogeneity in atypical femoral fractures. A pilot study. *Mol Cell Biochem.* 2015;409(1–2):45–50.
81. Kalyan S, Huebbe P, Esatbeyoglu T, et al. Nitrogen-bisphosphonate therapy is linked to compromised coenzyme Q10 and vitamin E status in postmenopausal women. *J Clin Endocrinol Metab.* 2014;99(4):1307–13.
82. Kalyan S, Quabius ES, Wiltfang J, Monig H, Kabelitz D. Can peripheral blood gammadelta T cells predict osteonecrosis of the jaw? An immunological perspective on the adverse drug effects of amino-bisphosphonate therapy. *J Bone Miner Res.* 2013;28(4):728–35.