


Cue Ball Arthroplasty With Humeroradial Total Elbow Arthroplasty (TEA) Revision: An Approach to Managing Infection and Severe Ulnar Bone Loss in TEA

Journal of Shoulder and Elbow Arthroplasty
Volume 4: 1–5
© The Author(s) 2020
Article reuse guidelines:
sagepub.com/journals-permissions
DOI: 10.1177/2471549220961592
journals.sagepub.com/home/sea


Daniel E Gerow, DO¹ , Emily H Tan, DO², and H Brent Bamberger, DO² 

Abstract

Total elbow arthroplasties (TEA) have become more prevalent as indications expand. However, TEA complications remain a treatment conundrum. One such complication, periprosthetic joint infections (PJIs) have been reported to occur in up to 12% of all TEA procedures. Irrigation and debridement with retention of hardware and antibiotic suppression has a high failure rate. Two stage revisions of TEA, while more morbid, is an effective approach with previous studies showing a 79% eradication rate. These cases are often associated with periprosthetic bone loss, adding to the surgical complexity. In our case report, we present the case of a 59 year old diabetic male with a primary TEA secondary to a distal humerus fracture who developed a deep infection and was successfully treated with explantation, cue ball antibiotic cement arthroplasty, and humeroradial revision. This case report will discuss the cue ball antibiotic spacer technique and humeroradial revision as a salvage procedure in TEA revisions in the setting of extensive ulnar bone loss.

Keywords

Total elbow arthroplasty, periprosthetic joint infection, revision, arthroplasty, antibiotic, distal humerus, cue ball

Date received: 26 March 2020; revised: 2 September 2020; accepted: 3 September 2020

Introduction

Total elbow arthroplasty (TEA) has traditionally been a treatment for rheumatoid arthritis of the elbow but indications have expanded to include comminuted distal humerus fractures.¹ Frankle showed that treating distal humerus fractures with TEA resulted in a Mayo functional score of 95 compared with ORIF resulting in a Mayo functional score of 87.7.¹ Day found the number of TEA performed in the USA between 1993 and 2007 has increased by 2.5 times and the number of TEA revisions has increased by 5 times.² The indications and thus patient population has also shifted. In a retrospective review of all TEA's performed in New York State from 1997 to 2006, TEA performed in settings of trauma significantly increased from 43 to 69% over a 10 year period, while the percentage of TEA for Rheumatoid Arthritis (RA) decreased from 48 to 19%.³

After 11.1 years, Welsink found the mean survival rate of TEA implants to be 79.2%.⁴ Literature

has shown various rates for the main complications of TEA, which are infection and aseptic loosening, with reports as high as 12% and 7% respectively.^{4,5}

Treatment of infected TEA is difficult. Irrigation and debridement with implant retention has a 50% eradication rate.^{6,7} Gille found a 67% eradication rate of infection in TEA patients who were treated with single stage revisions in a relatively small sample size.⁸

In comparison, Rudge found a 79% eradication rate of TEA infection after 2 stage revision.⁹ Several methods have been described to maintain form and function of the elbow during the explanted stage.

¹Metro Health-University of Michigan Health, Wyoming, Michigan

²Grandview Medical Center, Dayton, Ohio

Corresponding Author:

Daniel E Gerow, 5900 Byron Center Ave SW, Wyoming, MI 49519, USA.
Email: d.gerow6@gmail.com



Williams describes a construct with a bent Steinman pin covered in antibiotic loaded cement.¹⁰ Liporace describes a spacer using Ilizarov rods covered in antibiotic cement.¹¹ Although both of these options maintain some functional motion of the elbow, a metal implant still remains in the joint, which may theoretically allow biofilm formation. An antibiotic cement monoblock is a metal-free option but may not preserve tissue length and tension because active flexion and extension is limited. This may lead to elbow flexor and extensor atrophy, which could reduce the success of the 2nd stage revision.¹⁰ We have found the cue ball arthroplasty technique to be an effective way to avoid metal, while maintaining a functional elbow.

The second stage TEA revision is often complicated by considerable humeral and ulnar bone loss. There are various techniques to manage humeral bone loss including allograft augmentation with impaction grafting or struts or utilizing an endoprosthesis.¹² Likewise, revision of the ulnar component in the setting of bone loss can be treated with allograft prosthetic component, long stem or custom components, impaction or strut grafts.^{12,13} In our case study, we describe an alternative method of addressing ulnar bone loss that uses the radius in lieu of the ulna, the humeroradial TEA revision.

Case

A 59 year old diabetic male suffered polytrauma from a motor vehicle collision with the following injuries: open left distal humerus fracture, closed fracture of the left radius and ulna, closed fracture of the left femur, closed fracture of the left patella, closed fracture of the left tibia, closed fracture of the acetabulum, and closed dislocation of the sacrum. This case report will focus on the management of the distal humerus fracture, which at the time of injury was debrided, stabilized with an external fixator with placement of antibiotic beads. Two weeks after the injury, a TEA was performed using a Coonrad-Morrey implant.

Within the first 5 years there were several complications which were addressed with three additional procedures, which included heterotopic ossification with excision and radiation, polyethylene wear treated with polyethylene exchange, and triceps failure treated with reconstruction with achilles/calcaneus allograft.

Two and a half years after the triceps reconstruction, the patient presented to the hospital in septic shock reporting one year of swelling in his elbow. At that time, the patient underwent an irrigation and debridement (I&D). He was placed on IV antibiotics for six weeks followed by continued oral suppressive antibiotics.

Six months later, the patient was referred to the senior author with clinical signs of periprosthetic joint infection (PJI) including increased swelling. The patient underwent an I&D with replacement of hinge pin and bushings, and the prosthesis was stable and well-fixed. The patient was placed on IV antibiotics for six weeks for cultures positive for methicillin-resistant *Staphylococcus aureus* (MRSA) and then transitioned to oral suppressive antibiotics.

One year later, the patient continued to show clinical signs consistent with PJI and a 2 stage revision was planned (Figure 1). During explantation, cement was carefully removed from the intramedullary canals and joint space. Next, using a mixture of vancomycin and polymethylmethacrylate (PMMA) cement, three antibiotic cue balls were formed and allowed to cure. These were then placed into the pericapsular tissue sleeve and the extensor mechanism was closed over top (Figure 2). Repeat I&D and exchange of antibiotic cement was performed several months later. The patient was still able to use the elbow with functional flexion and extension with no brace needed.

Once clinical and laboratory results demonstrated adequate improvement, the second stage revision was performed (Figure 3). Upon exposure of the joint space, the cue ball arthroplasty beads were found to be encased in bony material and a soft tissue membrane. This heterotopic bone formation and synovium was resected back. Intraoperatively, the decision was made to place the ulnar component into the radius due to severe loss of ulnar bone stock. The radial head was resected. A canal finder and subsequent broaches were used in the radius. Although not needed in this case, one can consider using the instrumentation for the contralateral arm to aid in proper prosthesis placement in the context of the increased bow of the radius compared to the ulna. Of note, the patient's preoperative forearm rotation was greatly reduced due to synostosis bridging the ulna and radius at the level of his previous plating. To maximize function of the extremity, the ulnar component was inserted with the radius in slight pronation. After curing of the cement, the extremity was found to have approximately 15 degrees of hyperextension as well as full flexion. The wound was thoroughly irrigated with an acetic acid irrigation compound designed to reduce biofilm. The residual tissue triceps mechanism reconstruction with achilles allograft was attenuated but still present with fibrous tissue surrounding it. This remaining triceps mechanism was closed with #1 PDS in a running locked fashion in the soft tissue and integrated with new bone tunnels in the proximal ulna. A deep drain was placed along with a subcutaneous drain to avoid any postoperative hematoma. Next, the subcutaneous tissues were closed with 2-0 vicryl and staples were used on the skin. A sterile dressing was applied. The patient was

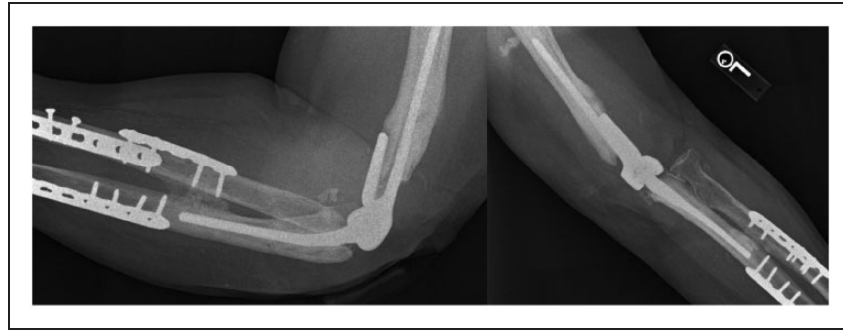


Figure 1. X-Ray of Infected TEA Prior to Revision. TEA: total elbow arthroplasty.

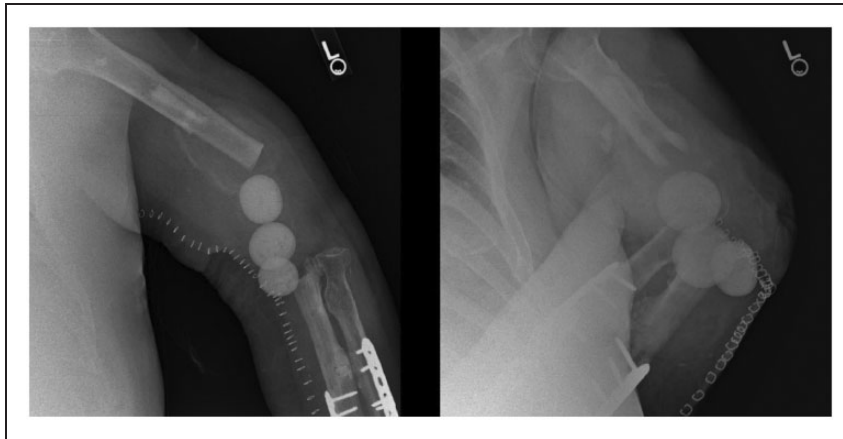


Figure 2. X-Ray After Cue Ball Arthroplasty.

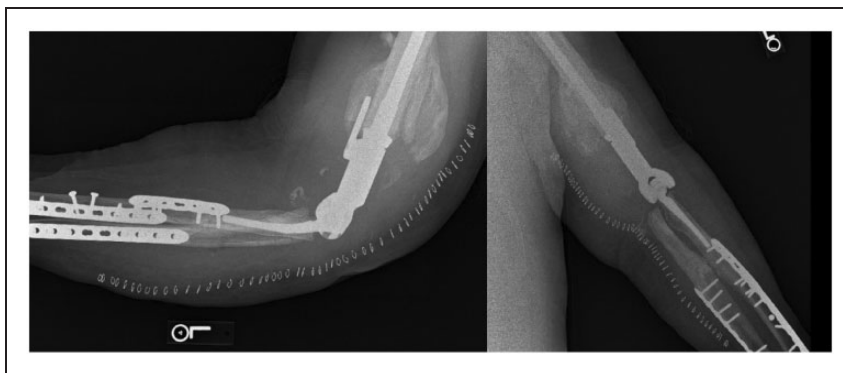


Figure 3. X-Ray 2 Weeks After Humeroradial Revision.

placed in an anteroposterior long-arm splint at 45 degrees of elbow flexion.

Patient had a normal postoperative course. At 9 months, Mayo score was 90 and DASH score was 23.15. At the most recent followup, 2.5 years postoperatively, the patient has functional elbow range of motion with any signs of infection (Figure 4).

Discussion

In the face of a PJI involving a TEA, surgical explantation of the implant is often a necessity. Irrigation and debridement with retention of implants has a 50% eradication rate. Single stage revision has an eradication rate of 67%.⁶⁻⁸ Two stage revisions of TEA's have been shown to have the highest eradication rate of 79%.⁹

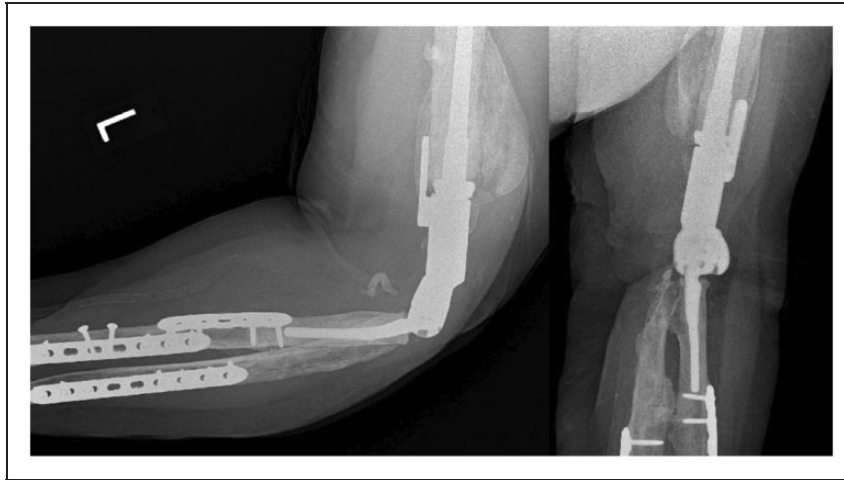


Figure 4. X-Ray 20 Months After Humeroradial Revision.

For 2 stage TEA revisions, Rudge found that 6 weeks of IV antibiotics after hardware removal is usually sufficient to clear the infection.⁹ The cue ball arthroplasty technique is a configuration of antibiotic spacers which allows motion and grip strength to be maintained in a pain-free elbow.¹⁴ In our case, 4–6 cm vancomycin impregnated PMMA balls (1g/bag of PMMA) are implanted within the elbow to maintain soft tissue tension. This soft tissue tensioning may be key in preventing atrophy of tissues which creates challenges to stability during reimplantation.¹⁰ Furthermore, the cue ball arthroplasty does not require retained metal, a potential source of biofilm in the setting of infection.^{10,11,15} In addition, the cue ball arthroplasty allows the bone canals to be free from any type of cement or implant. Even after removal of TEA, Stoodley found residual cement in the humeral canal to contain antibiotic resistant bacteria.¹⁵ Other articulating spacers made of metal constructs rely on stability from entering the medullary canal.^{10,11} When faced with the challenge of an infected TEA, the cue ball arthroplasty provides a reliable and simple approach to maximizing the patient's function while clearing the infection during a 2 stage revision.

Ulnar bone defects in the setting of infection is a difficult problem. In such cases, re-implantation of the prosthesis with allograft is a potential disadvantage as deep infection is a concern.¹² Furthermore, these ulnar bone defects can be too extensive for treatment with impaction grafting or custom or long stem implants. In cases of grade III or worse ulnar bone defect, ulnar to radial conversion can provide patients with a pain free elbow that has maintained flexion and extension in exchange for losing some rotation.¹⁶ It is key to counsel patients on this expectation. Placing the forearm in neutral position for implant insertion has been shown to create no significant worsening in functional disability

as most patients have stiff elbows before revision.¹⁶ The risk of aseptic loosening and periprosthetic fracture in ulnar to radial conversion has not been studied. With the non-anatomical reconstruction in this procedure, the radius becomes part of the flexion and extension mechanism. This could lead to abnormal stress placed on it and resultant fracture. Patients must be compliant with restriction of excessive forearm weight bearing. Gong showed success in counseling patients after ulnar to radial conversion to avoid repetitively lifting >1 kg or 5 kg in a single event.¹⁶

Conclusion

With infection rates of TEA as high as 12%, more literature is needed on the management of these difficult situations.^{2,5} When faced with a chronically infected TEA, 2 stage revision is an effective approach with a 79% eradication rate.⁹ The cue ball arthroplasty provides a spacer configuration that avoids retained metal and its potential bacterial biofilms, while also providing a functional elbow while maintained soft tissue tension.¹⁴ The humeroradial revision is a unique solution to the challenging problem of ulnar bone loss in the setting of TEA revision. This is a single patient case report with encouraging results at 2 year follow-up, but more data is needed concerning the long-term durability of a humeroradial revision.

Acknowledgments

The authors would like to acknowledge Dr Thomas J Graham, MD, for his guidance in performing the surgical techniques of the procedures outlined in this case.

Declaration of Conflicting Interests

The author(s) declared no potential conflicts of interest with respect to the research, authorship, and/or publication of this article.

Funding

The author(s) received no financial support for the research, authorship, and/or publication of this article.

ORCID iDs

Daniel E Gerow  <https://orcid.org/0000-0001-7664-9365>

H Brent Bamberger  <https://orcid.org/0000-0003-3019-0936>

References

1. Frankle MA, Herscovici D, DiPasquale TG, et al. A comparison of open reduction and internal fixation and primary total elbow arthroplasty in the treatment of intraarticular distal humerus fractures in women older than age 65. *J Orthop Trauma*. 2003;17(7):473–480.
2. Day JS, Lau E, Ong KL, et al. Prevalence and projections of total shoulder and elbow arthroplasty in the United States to 2015. *J Shoulder Elbow Surg*. 2010;19(8):1115–1120.
3. Gay DM, Lyman S, Do H, et al. Indications and reoperation rates for total elbow arthroplasty: an analysis of trends in New York state. *J Bone Joint Surg Am*. 2012;94(2):110–117.
4. Welsink CL, Lambers KT, van Deurzen DF, et al. Total elbow arthroplasty: a systematic review. *J Bone Joint Surg Rev*. 2017;5(7):1–10.
5. Kasten MD, Skinner HB. Total elbow arthroplasty: an 18-year experience. *Clin Orthop Relat Res*. 1993;(290):177–188.
6. Zmistowski B, Pourjafari A, Padegimas EM, et al. Treatment of periprosthetic joint infection of the elbow: 15-year experience at a single institution. *J Shoulder Elbow Surg*. 2018;27(9):1636–1641.
7. Yamaguchi K, Adams RA, Morrey BF. Infection after total elbow arthroplasty. *J Bone Joint Surg Am*. 1998;80(4):481–491.
8. Gille J, Ince A, Gonzalez O, et al. Single-stage revision of peri-prosthetic infection following total elbow replacement. *J Bone Joint Surg Br*. 2006; 88(10):1341–1346.
9. Rudge W, Eseonu K, Brown M, et al. The management of infected elbow arthroplasty by two-stage revision. *J Shoulder Elbow Surg*. 2018;27(5):879–886.
10. Williams KE, MacLean S, Jupiter J, et al. An articulating antibiotic cement spacer for first-stage reconstruction for infected total elbow arthroplasty. *Tech Hand Up Extrem Surg*. 2017;21(2):41–47.
11. Liporace FA, Kaplan D, Stickney W, et al. Use of a hinged antibiotic-loaded cement spacer for an infected periprosthetic fracture in a total elbow arthroplasty: a novel construct using Ilizarov rods. *J Bone Joint Surg Case Connect*. 2014;4(4):1–6.
12. Mansat P, Adams R, Morrey B. Allograft-prosthesis composite for revision of catastrophic failure of total elbow arthroplasty. *J Bone Joint Surg Am*. 2004;86(4):724–735.
13. Foruria AM, Sanchez-Sotelo J, Oh LS, et al. The surgical treatment of periprosthetic elbow fractures around the ulnar stem following semiconstrained total elbow arthroplasty. *J Bone Joint Surg Am*. 2011;93(15):1399–1407.
14. Evans P. Salvage procedures. *Reoper Hand Surg*. 2012;13:221.
15. Stoodley P, Nistico L, Johnson S, et al. Direct demonstration of viable *Staphylococcus aureus* biofilms in an infected total joint arthroplasty. *J Bone Joint Surg Am*. 2008;90(8):1751–1758.
16. Gong M-Q, Jiang J-L, Jiang X-Y, et al. Inserting the ulnar prosthesis into radius as a novel salvage surgery for revision total elbow arthroplasty with massive bone defect. *Chin Med J*. 2016;129(16):1917–1921.