

Operations about Hip in Human Immunodeficiency Virus-Positive Patients

Jeong Joon Yoo, MD, Sae Hyung Chun, MD, Young Sam Kwon, MD,
Kyung-Hoi Koo, MD, Kang Sup Yoon, MD, Hee Joong Kim, MD

Department of Orthopedic Surgery, Seoul National University College of Medicine, Seoul, Korea

Background: The number of human immunodeficiency virus (HIV)-infected patients is increasing constantly, and it is well known that there is a significantly high prevalence of osteonecrosis of the femoral head in HIV-infected patients. Therefore, it is important to develop methods that can ensure the safety of both the patients and medical personnel who participate in surgery on HIV-infected patients. Recently, the authors performed 8 procedures on 5 HIV-infected patients. This paper reports our experience.

Methods: This study examined the medical records and radiological studies of 5 HIV-infected patients who had undergone surgery around the hip joint from January, 2005 to September, 2007. During the procedures, their mean age was 38.6 years (range, 23 to 53 years) and all were male. Four of them were under an anti-retroviral therapy program. The reasons for the operations were nonunion of the femoral shaft after trauma in two patients and osteonecrosis of both femoral heads in three. One autologous bone grafting, one screw fixation with autologous bone grafting, five total hip replacement arthroplasties, and one multiple drilling were performed. All procedures were carried out according to the guidelines of HIV infection control made by the Korea Centers for Disease Control and Prevention. The mean follow-up period was 16.6 months (range, 4 to 37 months).

Results: The preoperative CD4 count was 130 in one patient, and 200 to 499 in the other 4. The viral loads were 15100 and 420 in two patients, and negative in the other 3. Bony union was achieved in those who had undergone autologous bone grafting. There were significant improvements in both the Harris Hip Score and functional state in those who had total hip replacement arthroplasty. There were no immediate postoperative complications, such as infection. During the follow-up period, one patient died from esophageal variceal bleeding. However, no surgery-related complications were observed in the other 4 patients.

Conclusions: There were no significant complications in HIV-infected patients after the operations around the hip joint when their preoperative immunity was optimal. In addition, the safety of medical personnel can be assured when the operation is performed in line with the guidelines of HIV infection control.

Keywords: Human immunodeficiency virus, Acquired immunodeficiency syndrome, Operation, Hip joint, Complication

According to the statistics, the number of human immunodeficiency virus (HIV)-infected people in Korea reached 5,323 in January 2008 with 4,343 of them still alive, and the number of cases is growing steadily.¹⁾ Even so, no

effective treatment methods have been established and prevention is the best way of avoiding HIV infections and acquired immune deficiency syndrome (AIDS).

Many studies have reported that patients infected with HIV have a high incidence of osteonecrosis of the femoral head.^{2,3)} HIV infections are prevalent in people between 20 to 50 years of age accounting for 79.4% of infected patients.¹⁾ Considering that many of the affected are in the young and active age group, there would be a relatively high number of trauma-related injuries in

Received November 21, 2008; Accepted March 28, 2009

Correspondence to: Hee Joong Kim, MD

Department of Orthopedic Surgery, Seoul National University Hospital, 28
Yeongeong-dong, Jongno-gu, Seoul 110-744, Korea

Tel: +82-2-2072-2970, Fax: +82-2-3672-7448

E-mail: oskim@snu.ac.kr

Copyright © 2010 by The Korean Orthopaedic Association

This is an Open Access article distributed under the terms of the Creative Commons Attribution Non-Commercial License (<http://creativecommons.org/licenses/by-nc/3.0>) which permits unrestricted non-commercial use, distribution, and reproduction in any medium, provided the original work is properly cited.

Clinics in Orthopedic Surgery • pISSN 2005-291X eISSN 2005-4408

the HIV-infected population, which will in turn lead to a higher demand for orthopedic surgery. Therefore, medical personnel should be equipped with a solid understanding of the surgical procedures performed on HIV-infected patients. Moreover, a study on the impact of HIV infections on the surgical outcomes will be needed to promote the safety of both medical personnel and patients during orthopedic surgery.

The authors recently performed eight operations on five HIV-infected patients. This paper is based on our experience and focuses on the preoperative preparations, caution taken during surgery, and the risk of early postoperative complications.

METHODS

Of the patients who had undergone surgery around the hip joint at our institution between January 2005 and September 2007, five patients with a HIV infection confirmed by enzyme-linked immunosorbent assay (ELISA) and Western blotting were included. Their medical records (internal medicine and orthopedics), laboratory test results, and radiographs were analyzed. All five patients were male with an average age of 38.6 years (range, 23 to 53 years). Four of the patients had been on anti-retroviral treatment for an average of 23 months (range, 2 to 34 months) prior to surgery, while it was started after surgery in the remaining one patient, who had been diagnosed with HIV immediately before surgery. The infection route was heterosexual contact in two of the five patients. The probable infection route was either homosexual or heterosexual contact in another patient who was bisexual.

Surgery was required for nonunion after a femoral

fracture that occurred in a traffic accident and for bilateral osteonecrosis of the femoral head in two and three patients, respectively. Regarding the surgical procedures, autologous bone grafting was performed in one case, screw fixation with autologous bone grafting in one, total hip replacement arthroplasty in five, and multiple drilling in one. The mean duration from confirmation of the HIV infection to surgery in the five patients ranged from five months to nine years, respectively (Table 1).

The preoperative and postoperative status of the patients was assessed using the CD4+ T cell count and HIV RNA level (viral load). The CD4+ T cell count is a marker of the immune system status and is classified into 3 levels, < 200/ μ L, 200-499/ μ L, and \geq 500/ μ L. A CD4+ T cell count of < 200/ μ L indicates a high risk of opportunistic infection and a diagnosis of AIDS. The viral load, which is used to predict changes in CD4+ T cell count in the near future, is associated with the prognosis.

All procedures were carried out according to the HIV infection control guidelines provided by the Korea Centers for Disease Control and Prevention. Only essential surgical instruments were available in the operating room and the operating table was covered with vinyl. The walls and instruments in the operating room were covered with disposable linen and the drainage bucket was also disposable. All the surgeons involved in the surgery wore waterproof gowns, caps, masks, head gear, two pairs of sterilized gloves, and protective boots. To prevent occurrence of injuries to the medical personnel during surgery, the needles and knives were handed over indirectly through a space set up between the surgeons and nurses. Postoperatively, all the surgical instruments and tissues were tagged with an HIV infection mark to ensure

Table 1. Demographic Data

| Case | Sex | Age | Diagnosis | Operation date | Operation name | Follow-up period |
|------|------|-----|-----------|----------------|---|------------------|
| 1 | Male | 23 | Nonunion | 2005. 1. 7 | Autologous bone graft | 3 yr 1 mo |
| 2 | Male | 53 | Nonunion | 2005. 3. 18 | Screw fixation with autologous bone graft | 8 mo |
| 3 | Male | 39 | ONFH | 2005. 4. 8 | THA | 2 yr 4 mo |
| | | | ONFH | 2005. 8. 5 | THA | 2 yr |
| 4 | Male | 32 | ONFH | 2007. 6. 1 | THA | 8 mo |
| | | | ONFH | 2007. 8. 24 | THA | 6 mo |
| 5 | Male | 46 | ONFH | 2007. 9. 17 | THA | 6 mo |
| | | | ONFH | 2007. 9. 17 | MD | 6 mo |

ONFH: Osteonecrosis of the femoral head, THA: Total hip replacement arthroplasty, MD: Multiple drilling.

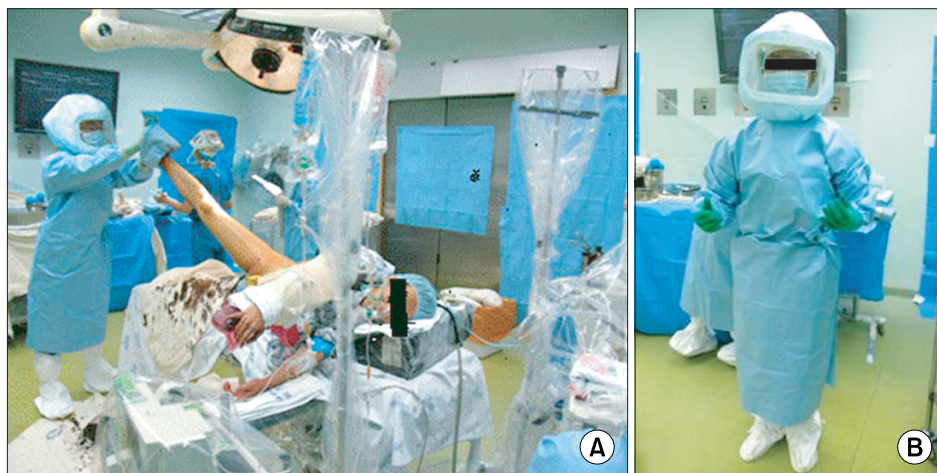


Fig. 1. Preparation of the operating room and operator. All preparations were carried out according to the guidelines of HIV infection control set by the Korea Centers for Disease Control and Prevention.

Table 2. Patients' Data

| Case | Preop. CD4+ count (/ μ L) | Preop. viral load (copies/mL) | Preop. anti-retroviral therapy period (mo) | Postop. X-ray | Postop. infection | Final CD4+ count (/ μ L) | Final viral load (copies/mL) |
|------|-------------------------------|-------------------------------|--|---------------|-------------------|------------------------------|------------------------------|
| 1 | 220 | Negative | No | Union | No | 147 | 143,000 |
| 2 | 270 | 15,100 | 2 | Union | No | 441 | 113 |
| 3 | 130 | 420 | 24 | No loosening | No | 24 | 98,000 |
| | 110 | No data | | No loosening | No | | |
| 4 | 409 | Negative | 34 | No loosening | No | 205 | 79,100 |
| | 370 | Negative | | No loosening | No | | |
| 5 | 463 | Negative | 32 | No loosening | No | 548 | Negative |
| | | | | No collapse | No | | |

Preop.: Preoperative, Postop.: Postoperative.

that they were easily recognizable by other personnel at our institution (Fig. 1).

The mean postoperative follow-up period was 16.6 months (range, 4 to 37 months). During the regular follow-up examination performed on an outpatient basis, an ordinary blood test, T cell subset test and radiological test were carried out. The Harris Hip Scores was also measured in patients who had undergone hip replacement arthroplasty.

RESULTS

Preoperatively, the CD4+ T cell count ranged from 130 to 463/ μ L respectively (Table 2); it was < 200/ μ L in one patient and 200-499/ μ L in the remaining four patients. The viral load was 15,100 and 420 copies/mL in two patients

2 and 3, respectively, but negative in the remaining three patients. At the last follow-up, the CD4+ T cell count ranged from 24 to 548/ μ L (Table 2); it was < 200/ μ L in two patients and 200-499/ μ L in the remaining three patients. The viral load ranged from 113, 79,100, 98,000, and 143,000 copies/mL in four patients, and was negative in one patient (Table 2).

Of the two patients (two cases) with nonunion after a femoral fracture, one was treated with an autologous bone graft and the other underwent screw fixation with autologous bone grafting. Surgery was performed for 166 minutes and 170 minutes under spinal anesthesia in one patient and under spinal/epidural anesthesia in the other, respectively. Both achieved bone union and were followed up for eight months and 37 months, respectively. The patient who had been followed for eight postoperative

months died from esophageal variceal bleeding at the 14th postoperative month (Fig. 2).

Of the three patients (six cases) with osteonecrosis of the femoral head, five cases were treated with hip replacement arthroplasty and one with multiple drilling. Two of them underwent a two of bilateral hip replacement procedures under spinal anesthesia with an interval of four months and two months respectively. The surgical time was 144, 144, 140, and 136 minutes, respectively. In the other patient, hip replacement arthroplasty was performed on one side and multiple drilling was performed on the other side simultaneously under spinal/epidural anesthesia for 275 minutes. Significant improvements in the Harris Hip Score and functional state were noted during 4, 6, and 28 month follow-up examination. There were no

acute postoperative complications, such as infection, early loosening of implants, and dislocation. The one patient without preoperative anti-retroviral treatment was placed on anti-retroviral treatment postoperatively and the remaining four patients were on the anti-retroviral treatment that they had received preoperatively (Fig. 3). At the final follow-up, excluding the patient who died from esophageal variceal bleeding, the remaining four patients showed no complications associated with the orthopedic surgery.

DISCUSSION

The 2007 report of the Korea Centers for Disease Control and Prevention, 'Knowledge, attitudes, beliefs, and practices on HIV', shows that people's knowledge of AIDS is improving but is still at a low level compared to advanced countries. Discriminative attitudes toward HIV-infected patients were also reflected in the survey results of that report: 24.3% and 26.7% of respondents answered expulsion from family and work were necessary, respectively; 44.4% responded that the HIV-infected should not be allowed to visit their children's school; and 36.5% demanded social segregation. Similarly, HIV-infected patients are not accepted in most medical institutions and are even referred to university hospitals by tertiary hospitals. These attitudes can be attributed to ignorance of the infection control guidelines and a lack of treatment experience.

Many authors reported that the incidence of osteonecrosis of the femoral head is high among HIV-infected patients. For example, Miller et al.²⁾ evaluated the prevalence of osteonecrosis of the femoral head using MRI in 339 asymptomatic HIV-infected patients and 118 non-infected people who were matched for age and gender. In that study, osteonecrosis was diagnosed in 4.4% of HIV-

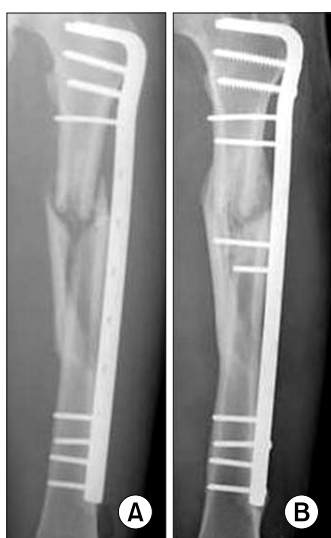

Fig. 2. Preoperative and postoperative X-ray of one nonunion patient. The postoperative X-ray shows that a callus had formed and union was achieved.

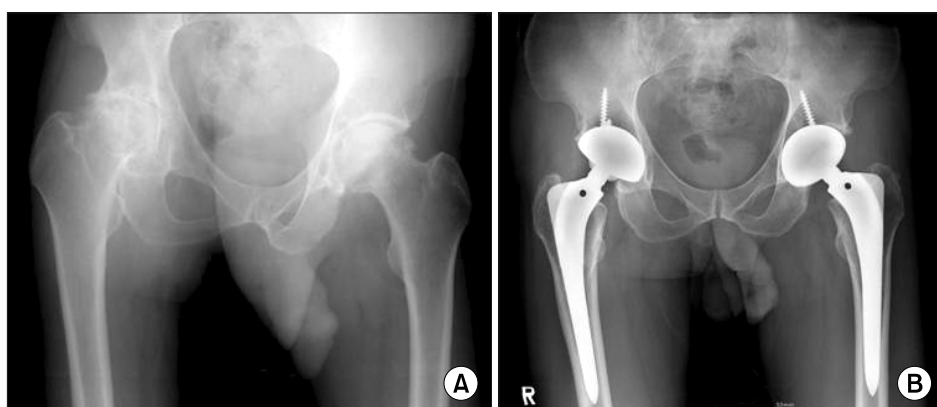


Fig. 3. Preoperative and postoperative X-ray of one osteonecrosis patient. The postoperative X-ray shows no evidence of complications, such as loosening or infection.

infected patients while not a single case was found in the non-infected group. In addition, they found that the incidence was 100 times higher in infected individuals than in ordinary people.³⁾ According to recent reports, the prevalence has increased sharply in HIV-infected patients while they have remained constant in those not infected.^{4,5)} Scribner et al.⁵⁾ attributed the high incidence of osteonecrosis in HIV-infected patients to the use of corticosteroid and highly active anti-retroviral therapy. Ries et al.⁶⁾ suggested that HIV infection itself is a major risk factor for osteonecrosis in their study involving 38 patients with atraumatic osteonecrosis of the femoral head. Another report⁷⁾ also showed that the outcome of osteonecrosis in HIV-infected patients was affected by the occurrence site, gender and CD 4+ T cell count.

HIV-infected patients are vulnerable to infection after hip replacement arthroplasty or surgery after trauma. According to Lehman et al.,⁸⁾ postoperative infections were encountered in 4 (14%) of 28 HIV-infected patients who had undergone hip or knee replacement arthroplasty. The percentage was remarkably high compared to that in non-infected people. Parvizi et al.⁹⁾ identified 6 cases of postoperative infection after 21 arthroplasties (13 knee and 8 hip replacement arthroplasties) performed on 15 HIV-infected patients and carried out 13 reoperations. Hoekman et al.¹⁰⁾ reported that the infection rate following invasive fracture reduction was significantly higher in symptomatic HIV-infected patients than in non-infected individuals. Paiement et al.¹¹⁾ observed that various infections, including operation-related ones, occurred at a remarkably high rate both symptomatic and asymptomatic HIV-infected patients after fracture surgery.

However, some recent reports showed that there was no increase in the postoperative infection rates among HIV-infected patients postoperatively. In the prospective study of Harrison et al.¹²⁾ involving 41 HIV-infected patients and 141 non-infected counterparts, no difference was found between the two groups regarding the postoperative infection rate unless intraoperative contamination had occurred. Mahoney et al.¹³⁾ observed a single case of postoperative infection in 54 cases of hip replacement arthroplasty performed on 40 HIV-infected patients. They postulated that the improvement in the management of the HIV-infected patients resulted in such outcomes. In the present study, no case of postoperative infection was encountered. Although this study was based on a small number of patients, it is believed that a proper evaluation of the immune system before surgery and thorough enforcement of the guidelines during surgery contributed to such satisfactory outcomes.

Medical practitioners are exposed to a risk of infection during surgery from the blood and body fluids of HIV-infected patients. Therefore, it is important to be fully aware of the safety practices used during treatment. One epidemiological study described the risk of HIV infections in medical personnel after transcutaneous exposure as 0.3%.¹⁴⁾ Based on this, an approximate estimation of the infection risk in domestic medical personnel can be obtained. Currently, 4,343 people, approximately 0.01% of the total population, are infected with HIV in Korea. If a surgeon is exposed to infected blood about 10 times a year during surgery for 40 years, then the surgeon has a 0.012% chance of infection ($0.0001 \times [40 \text{ years} \times 10 \text{ times/year}] \times 0.003 [\text{risk of infection after exposure}] = 0.00012$). However, considering that orthopedic surgery involves sharp and high-speed metal equipment to deal with hard and sharp tissues, such as fractured bones, these surgeons are more likely to be injured during surgery. Therefore, it is our understanding that orthopedic surgeons should pay special attention to the fact that they are exposed to a higher risk of infection than indicated by the above-cited reports. In particular, based on reports that osteonecrosis can be found in 4.4% of HIV-infected and that the number of the HIV survivors in Korea is 4,343, it can be assumed that the number of the HIV infected patients with femoral head necrosis is approximately 190 ($4,343 \times 0.044 = 191$). With these patients expected to undergo orthopedic treatments as the disease progresses, orthopedic surgeons in Korea should be equipped with the basic knowledge, preparations and precautions needed during surgery for HIV-infected patients.

This study shows that hip replacement arthroplasty in HIV-infected patients does not result in early postoperative complications if the preoperative immune system is healthy. In addition, the safety of the surgeons can be guaranteed if infection control guidelines are enforced thoroughly. As the number of the people with HIV infections increase, it is expected that the demand for orthopedic treatments from HIV-infected patients will also increase. Therefore, the importance of meticulous preparation and study should never be neglected. Specifically, HIV-infected patients with the risk factors for osteonecrosis of the femoral head should be subject to a regular long-term examination to allow early diagnosis and treatment.

ACKNOWLEDGEMENTS

This work was supported by a grant (06-03-063) from the Seoul National University Hospital Research Fund.

REFERENCES

1. Korea Centers for Disease Control and Prevention. Annual Report from the Division of HIV and TB control. Seoul: Korea Centers for Disease Control and Prevention; 2008.
2. Miller KD, Masur H, Jones EC, et al. High prevalence of osteonecrosis of the femoral head in HIV-infected adults. *Ann Intern Med.* 2002;137(1):17-25.
3. Morse CG, Mican JM, Jones EC, et al. The incidence and natural history of osteonecrosis in HIV-infected adults. *Clin Infect Dis.* 2007;44(5):739-48.
4. Keruly JC, Chaisson RE, Moore RD. Increasing incidence of avascular necrosis of the hip in HIV-infected patients. *J Acquir Immune Defic Syndr.* 2001;28(1):101-2.
5. Scribner AN, Troia-Cancio PV, Cox BA, et al. Osteonecrosis in HIV: a case-control study. *J Acquir Immune Defic Syndr.* 2000;25(1):19-25.
6. Ries MD, Barcohana B, Davidson A, Jergesen HE, Paiement GD. Association between human immunodeficiency virus and osteonecrosis of the femoral head. *J Arthroplasty.* 2002;17(2):135-9.
7. Gutierrez F, Padilla S, Masia M, et al. Osteonecrosis in patients infected with HIV: clinical epidemiology and natural history in a large case series from Spain. *J Acquir Immune Defic Syndr.* 2006;42(3):286-92.
8. Lehman CR, Ries MD, Paiement GD, Davidson AB. Infection after total joint arthroplasty in patients with human immunodeficiency virus or intravenous drug use. *J Arthroplasty.* 2001;16(3):330-5.
9. Parvizi J, Sullivan TA, Pagnano MW, Trousdale RT, Bolander ME. Total joint arthroplasty in human immunodeficiency virus-positive patients: an alarming rate of early failure. *J Arthroplasty.* 2003;18(3):259-64.
10. Hoekman P, van de Perre P, Nelissen J, Kwisanga B, Bogaerts J, Kanyangabo F. Increased frequency of infection after open reduction of fractures in patients who are seropositive for human immunodeficiency virus. *J Bone Joint Surg Am.* 1991;73(5):675-9.
11. Paiement GD, Hymes RA, LaDouceur MS, Gosselin RA, Green HD. Postoperative infections in asymptomatic HIV-seropositive orthopedic trauma patients. *J Trauma.* 1994;37(4):545-50.
12. Harrison WJ, Lewis CP, Lavy CB. Wound healing after implant surgery in HIV-positive patients. *J Bone Joint Surg Br.* 2002;84(6):802-6.
13. Mahoney CR, Glesby MJ, DiCarlo EF, Peterson MG, Bostrom MP. Total hip arthroplasty in patients with human immunodeficiency virus infection: pathologic findings and surgical outcomes. *Acta Orthop.* 2005;76(2):198-203.
14. Lemaire R, Masson JB. Risk of transmission of blood-borne viral infection in orthopaedic and trauma surgery. *J Bone Joint Surg Br.* 2000;82(3):313-23.