

Retrodiscal epidural balloon adhesiolysis through Kambin's triangle in chronic lumbar spinal stenosis

A retrospective analysis and technical considerations

Dong-Kyun Seo, MD, Sookyung Lee, MD, Gunn Lee, MD, Myung-Su Lee, MD, Syn-Hae Yoon, MD, Seong-Soo Choi, MD, PhD*, Jin-Woo Shin, MD, PhD*

Abstract

A previous study showed that transforaminal balloon adhesiolysis via the safe triangle was effective in lumbar spinal stenosis. However, retrodiscal pathology is difficult to treat with this method. Therefore we attempted retrodiscal balloon adhesiolysis via Kambin's triangle. The design of our study is a retrospective analysis. The setting of our study is a tertiary, interventional pain management practice, speciality referral center.

The primary indication for this procedure is radicular pain arising from ipsilateral retrodiscal pathology. Medical records were reviewed of patients who received retrodiscal decompression with a transforaminal balloon inflatable catheter between January 1, 2016 and July 31, 2017. The intervention was conducted by 2 well-trained pain specialists. The introducer needle was positioned at Kambin's triangle. Adhesiolysis was performed using a balloon filled with radiocontrast media. After balloon adhesiolysis, an agent containing lidocaine and dexamethasone was injected through the introducer sheath. Numeric rating scale pain scores were obtained 1 and 3 months after the procedure.

The mean pre-procedure numeric rating scale score was 7.05 ± 1.40 . After 1 and 3 months, the mean scores were 3.91 ± 2.20 and 3.77 ± 2.11 , respectively. No patient had significant complications. Also, technical considerations were discussed.

Chronic pain due to lumbar central stenosis, especially ipsilateral retrodiscal pathology, can be reduced by retrodiscal balloon adhesiolysis through Kambin's triangle. Although this study is limited by its retrospective design, the results suggest that this procedure is a useful treatment due to its ease of performance and cost-effectiveness.

Abbreviations: MRI = magnetic resonance imaging, NRS = numeric rating scales.

Keywords: balloon, chronic pain, Kambin's triangle, percutaneous epidural adhesiolysis, retrodiscal, spinal stenosis

1. Introduction

Spinal stenosis is one of the diseases that adversely affect the quality of life. Strategies to relieve the pain arising from spinal stenosis include surgery, nerve blocks, neuroplasty, and others. The value of nonsurgical treatment will increase as life expectancy after

surgery becomes longer. Expansion of nonsurgical interventions will be necessary to meet the demands of society.

Our institute previously published several articles about nonsurgical interventions,^[1-4] particularly balloon decompression and adhesiolysis of the lumbar epidural space and neural foramen in patients with lumbar spinal stenosis.^[1,2] Transforaminal epidural steroid injection was proven to be effective in patients with foraminal stenosis.^[5] However, because the pathology of spinal stenosis exists at the foramen as well as the preganglionic area, practitioners perform the injection at the retrodiscal epidural space.^[6] Our previous study showed that transforaminal balloon adhesiolysis via the safe triangle was effective in lumbar spinal stenosis.^[2] Based on these results, we perform epidural balloon adhesiolysis in the retrodiscal area using an inflatable 2-Fr transforaminal balloon catheter.

This report presents cases of retrodiscal balloon adhesiolysis in patients with ipsilateral retrodiscal central stenotic lesions of the lumbar spine.

2. Methods

2.1. Patients and study design

Records of 22 patients who underwent retrodiscal balloon adhesiolysis in our institute between January 1, 2016 and July 31, 2017 were reviewed (Table 1). Permission to conduct this study was granted by our Institutional Review Board (approval

Editor: Jianxun Ding.

S-SC and J-WS contributed equally to this work.

The authors have no funding and conflicts of interest to disclose.

Department of Anesthesiology and Pain Medicine, Asan Medical Center, University of Ulsan College of Medicine, Seoul, Republic of Korea.

* Correspondence: Seong-Soo Choi, Department of Anesthesiology and Pain Medicine, Asan Medical Center, University of Ulsan College of Medicine, 88 Olympic-ro 43-gil, Songpa-gu, Seoul, 05505, Republic of Korea (e-mail: choiss@amc.seoul.kr); Jin-Woo Shin, Department of Anesthesiology and Pain Medicine, Asan Medical Center, University of Ulsan College of Medicine, 88 Olympic-ro 43-gil, Songpa-gu, Seoul, 05505, Republic of Korea (e-mail: sjinwoo@hotmail.com)

Copyright © 2018 the Author(s). Published by Wolters Kluwer Health, Inc. This is an open access article distributed under the terms of the Creative Commons Attribution-Non Commercial License 4.0 (CCBY-NC), where it is permissible to download, share, remix, transform, and buildup the work provided it is properly cited. The work cannot be used commercially without permission from the journal.

Medicine (2018) 97:41(e12791)

Received: 30 June 2018 / Accepted: 18 September 2018

<http://dx.doi.org/10.1097/MD.00000000000012791>

Table 1
Patient demographics, outcome and complications.

Demographics							Subject symptoms, imaging study findings and location of procedure			Outcome (NRS)			Complication
No.	Age	Sex	Height (m)	Weight (kg)	BMI (kg/m ²)	Underlying disease	Dermatome of radicular pain*	MRI findings [†]	Balloon level	Basal	1m.	3m.	
A	59	F	1.55	53	22.1	Hypertension, Osteoporosis	L5, S1 Rt	L4–5 central	L4–5 Rt	5	5	5	None
B	32	F	1.56	45	18.5	Systemic Lupus Erythematosus	S1 Lt	L5-S1 central	L5-S1 Lt	8	8	7	None
C	65	F	1.53	47	20.1	None	S1 Rt	L5-S1 central	L5-S1 Rt	6	3	4	None
D	39	M	1.74	84	27.7	None	L5 Lt	L4–5 central	L4–5 Lt	8	7	5	None
E	57	M	1.71	67	22.9	None	L5 Rt	L4–5 central	L4–5 Rt	7	4	4	None
F	68	M	1.72	73	24.7	None	L3 Lt	L2–3 central	L2–3 Lt	6	4	3	None
G	67	F	1.60	58	22.7	None	S1 Lt	L5-S1 central	L5-S1 Lt	6	0	3	None
H	65	M	1.68	63	22.3	None	L5 Rt	None	L4–5 Rt	9	5	4	None
I	72	F	1.47	40	18.5	None	L5 Rt	L4–5 central	L4–5 Rt	7	4	3	None
J	72	M	1.68	80	28.3	Hypertension	L5 Rt	L4–5 central	L4–5 Rt	8	4	3	None
K	58	M	1.70	67	23.2	Hypertension	L5 Rt	L4–5 central	L4–5 Rt	6	5	2	None
L	37	M	1.65	72	26.4	None	S1 Lt	L4-L5-S1 central	L4–5 Lt	8	4	2	None
M	54	F	1.56	64	26.3	Hypertension	L5 Lt	L4–5 central	L4–5 Lt	8	0	0	None
N	42	F	1.62	55	21.0	None	S1 Lt	L5-S1 central	L5-S1 Lt	8	3	3	None
O	27	M	1.80	82	25.3	None	S1 Lt	L5-S1 central	L5-S1 Lt	5	3	3	None
P	48	M	1.74	70	23.1	None	L5 Rt	L4–5 central	L4–5 Rt	7	2	2	None
Q	49	M	1.66	52	18.9	None	L5 Rt	L4–5 central	L4–5 Rt	5	2	2	None
R	44	F	1.59	48	19.0	None	L5, S1 Lt	L4–5 central	L4–5 Lt	7	5	5	None
S	71	M	1.68	63	22.3	None	L5 Rt	L4–5 central	L4–5 Rt	10	3	8	None
T	53	F	1.52	48	20.8	None	L5 Rt	L4–5-S1 central	L4–5 Rt	8	8	8	None
U	60	F	1.55	54	22.5	None	L5 Lt	L4–5 central	L4–5 Lt	5	3	3	None
V	78	M	1.60	60	23.4	Hypertension	L5 Rt	L4–5 central	L4–5 Rt	8	7	7	None

BMI = body mass index, MRI = magnetic resonance imaging, NRS = numeric rating scale.

* Affected nerve roots (e.g., L5 means lumbar 5 nerve root).

† MRI findings. Balloon decompression at the retrodiscal area is indicated in patients who have central canal stenosis caused by herniated discs (e.g., L4–5 central: central spinal canal stenosis caused by herniated L4–5 disc).

number, 2018–0473). All reviewed patients complained of chronic low back and/or leg pain lasting more than 3 months. They were diagnosed with lumbar spinal stenosis caused from herniated intervertebral disc confirmed by magnetic resonance imaging (MRI) except for a patient H. Lumbar MRI of a patient H did not show any abnormality. It can be postulated that the epidural adhesion may cause his symptom because his symptom occurred along right L5 dermatome. In all patients, previous treatment with conventional transforaminal block or retrodiscal epidural steroid injection had no effect or the effect did not last more than 1 month. All patients underwent the same ballooning procedure in the retrodiscal area of the lumbar spine by the methods described below. The balloon adhesiolysis procedure was performed by 2 well-trained pain specialists. The patients were followed up in the outpatient department of the pain clinic at 1 and 3 months after the procedure. Numeric rating scale (NRS) pain scores were routinely obtained on follow-up.

The primary indication for this procedure is radicular pain arising from ipsilateral retrodiscal pathology. The radiating pain can manifest with foraminal stenosis at the same level and also with central stenosis with ipsilateral bulging of the disc at the upper 1 or 2 level of the spine (Fig. 1).

2.2. Interventional technique: retrodiscal epidural balloon decompression and adhesiolysis

A novel thin (2-Fr) balloon catheter (ZiNeuF, JUVENUI, Seoul, Korea) was used (Fig. 2). The device includes the balloon catheter, the enforcement wire, a 1-cc syringe for ballooning, and

a 16G introducer needle. The balloon was inflated with 0.1 cc of radiocontrast dye (Omnipaque, Nycomed Imaging AS, Oslo, Norway). The introducer needle is covered by a plastic sheath. The intervention was conducted in an operating room that was equipped with an anesthetic machine. Pulse oximetry and noninvasive blood pressure were monitored. Radiographic imaging equipment was also present. In the operating room, the patient was placed in the prone position. A pillow or chest bar was placed under the abdomen to reduce the lordotic curvature of the lumbar spine,^[7] thus extending the neural foramen to facilitate the positioning of the introducer needle. Betadine solution was used for skin preparation. In the anteroposterior view, the C-arm (OEC 9800, General Electric Healthcare, Little Chalfont, United Kingdom) was tilted to adjust the level of the vertebra and the end plate of the vertebral body and was then rotated in the ipsilateral direction until the superior articular process met the one-half of the vertebral body. The entry point of the needle was checked, and the local anesthetic (1% lidocaine) was infiltrated. The needle was advanced via Kambin's triangle (the inferior triangle of the foramen) using the tunnel-view technique. While the needle was being advanced, the response of the patient was considered to avoid accidental painful touching of the spinal nerve.

When the needle was sufficiently advanced, the lateral and anteroposterior views were checked to confirm the accurate position of the needle. The tip of the needle was positioned at the ipsilateral margin of the vertebral body in the anteroposterior view and at the anterior or middle third of the spinal canal in the lateral view (Fig. 3). After removal of the stylet, the balloon catheter with the wire was inserted through the sheath. The

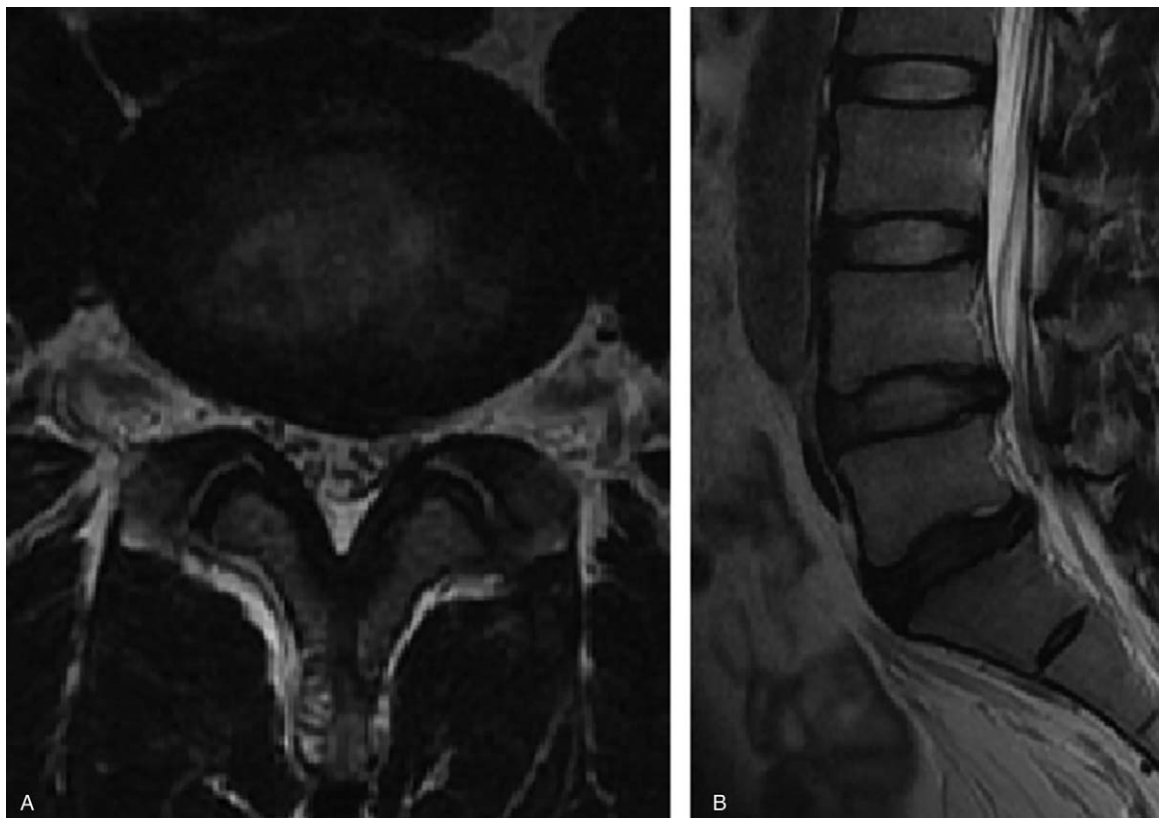


Figure 1. T2-weighted magnetic resonance imaging of patient L. A: Transverse plane image of L4–5 level. B: Right sagittal image of lumbar spine.

catheter was not advanced in patients with severe disc bulging, accompanying foraminal stenosis, or retrolisthesis. In these cases, the depth and angle of the sheath were adjusted, and the conventional smooth epidural catheter was used to secure the

passage of the balloon catheter. A small volume of normal saline could also be used to secure the passage and resolve the adhesion. When the tip of the balloon catheter reached the center of the anterior epidural space, the wire was removed, the air inside the




Figure 2. A novel inflatable balloon catheter. Note the inflatable balloon at the tip of the catheter.

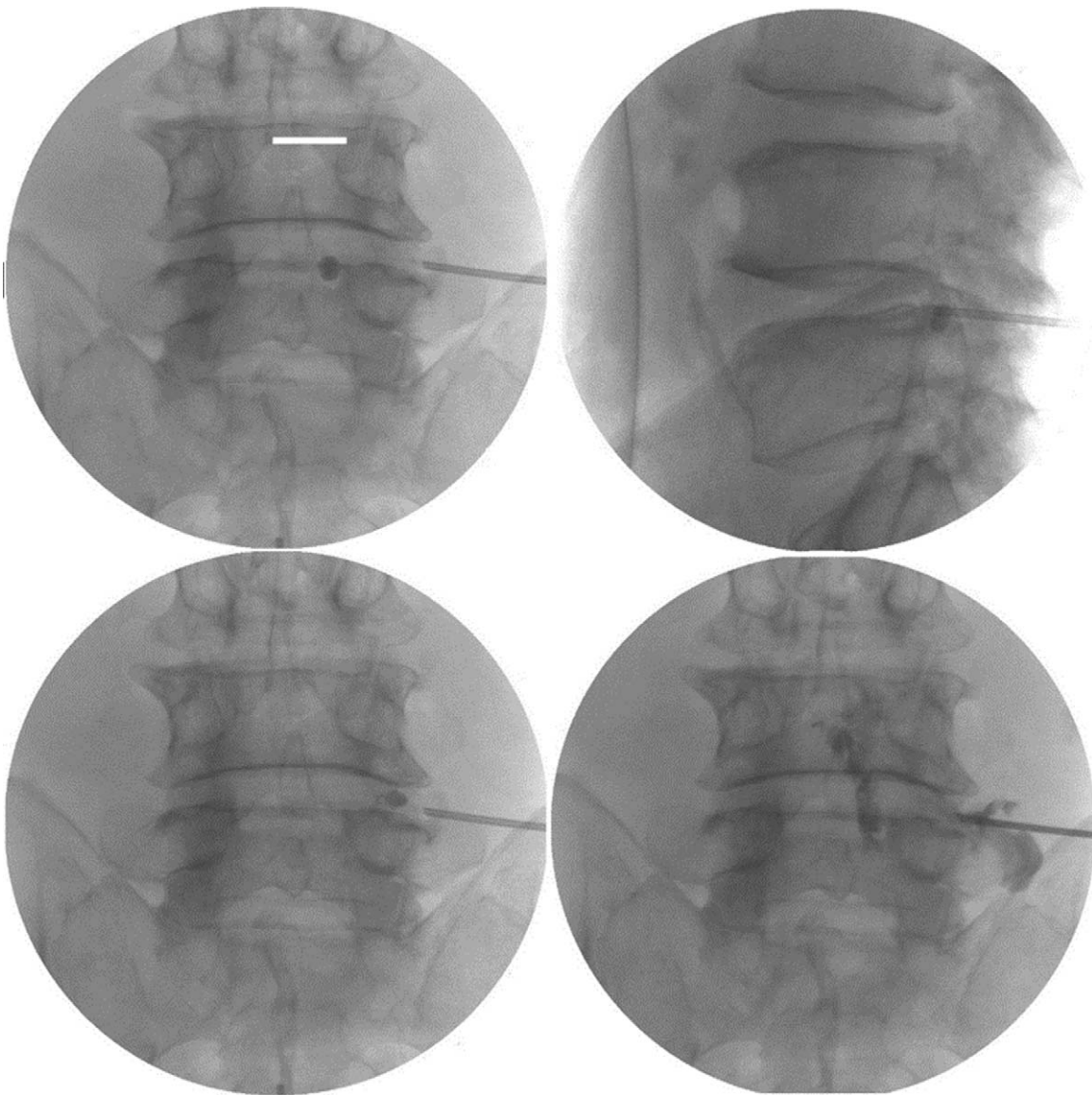


Figure 3. Fluoroscopic image of balloon decompression and adhesiolysis at the lumbar 4–5 retrodiscal area of patient E. Note the location of the needle.

catheter was eliminated, and the lumen of the catheter was filled with radiocontrast media using the negative pressure technique. If air remained in the balloon catheter, the radiographic image could have some air artifact that could be mistaken for a stenotic lesion. The balloon was then inflated with a small volume (0.05 cc). While the catheter was gradually withdrawn, the balloon was inflated and deflated with 0.05 cc of radiocontrast media until the tip of the catheter reached the extraforaminal area. The balloon was always deflated when the catheter was moved forward or backward. After that, the catheter was readvanced to the anterior epidural space. The balloon was fully inflated with 0.1 cc of radiocontrast media and then deflated while withdrawing the catheter. The duration of balloon inflation did not exceed 5 seconds because of concern for possible ischemic damage. In most stenotic lesions, the balloon was inflated 2 or 3 times without moving the catheter. The response of the patient was considered to reduce procedure-related pain. If the patient complained of severe pain, inflation of the balloon was stopped and the balloon was deflated (Fig. 3).

If balloon adhesiolysis was successfully performed, radiocontrast medium was injected through the introducer sheath to confirm the resolution of the adhesive lesion. After spreading of the dye was confirmed, a mixture of 3 mL of 1% lidocaine and 5 mg of dexamethasone was injected through the sheath. After injection, the sheath was removed, and betadine ointment and a simple dressing were applied.

In the recovery room, peripheral oxygen saturation and noninvasive blood pressure were monitored every 15 minutes for 60 minutes. After confirmation that there were no procedure-related complications (e.g., motor weakness, dural puncture, unstable vital signs), the patient was discharged.

2.3. Statistical analysis

Continuous variables are presented as means with standard deviation. Statistical analysis was conducted with repeated-measures analysis of variance using the Statistical Package for the Social Sciences (SPSS, IBM Corp, Armonk, NY).

3. Results

The demographic data of the patients were shown in Table 1. The mean preprocedure NRS was 7.05 ± 1.40 . The mean NRS significantly decreased after 1 and 3 months to 3.91 ± 2.20 and 3.77 ± 2.11 , respectively (Fig. 4). None of the patients had significant complications.

In patients A, B, T, and V, there was no improvement or worsening of the symptoms at 3 months compared with basal symptoms. The other patients (81.8%) had significant improvement of symptoms. Three patients (C, G and S) had significant improvement at 1 month, but the symptoms worsened at 3 months. All patients except patient B had neurogenic claudication due to herniated discs. All patients except patients A, C, G, T, and V subjectively reported functional improvement such as walking distance (77.3%). No patient received additional treatment 3 months after the procedure. Patient A, B, T, and V showed poor response to the procedure. Patient B was previously diagnosed with systemic lupus erythematosus and showed no response to the procedure.

4. Discussion

Balloon decompression and adhesiolysis through the foramen can be performed in 2 ways: the safe-triangle approach introduced in a previous report^[2] and the Kambin's triangle approach introduced in the present report. The safe-triangle approach is similar to that used for conventional transforaminal epidural blocks, and it can be used in patients whose lesions are confined to extraforaminal, foraminal, and preganglionic areas.^[2] The Kambin's triangle approach is indicated in patients whose lesions are confined to the retrodiscal area and who consequently complain of radiating pain. The proper approach technique depends on the location of the lesion causing pain in the patient. To resolve the problems caused by compression of the spinal nerve passing down through the site of the central stenosis, our center tried retrodiscal balloon decompression about 2 years ago. In the present report, we showed that an approach through

Kambin's triangle can reduce symptoms arising from ipsilateral retrodiscal epidural pathology.

The treatment was ineffective in patients A, B, T, and V. Patient A had a history of partial laminectomy of the right lumbar levels 4 and 5 performed 4 months before the procedure. Epidural adhesive lesions were found around the surgical site on preoperative MRI. Balloon adhesiolysis was successfully performed, but the treatment was ineffective due to advanced epidural adhesion and a possible combined neuropathic component. Patient B was diagnosed with systemic lupus erythematosus and had almost no neurogenic claudication before the procedure. However, we decided to perform the procedure because the patient complained of paresthesia of the S1 dermatome and wanted the procedure. We presumed the poor outcome due to lupus-related neuronal damage that had already progressed before balloon adhesiolysis and abnormal healing of the connective tissue.^[8] Patient T had become worse symptoms 1 month before the procedure. Preoperative MRI showed a severe herniation of disc and motor weakness (grade 3–4) was visible. Therefore, the surgical operation was indicated, but the patient refused the surgery and wanted to be performed a retrodiscal balloon procedure. Patient T decided to undergo surgery after 3 months of balloon procedure. Patient V has a history of microscopic discectomy at L4–5 level 2 years ago like Patient A. and the symptom started about 5 months before balloon procedure. Preoperative MRI showed thickening of ligamentum flavum and hypertrophy of zygapophysial joint. This patient also scheduled surgery afterwards.

Review of the records of patients who showed positive response to the treatment found that were no comorbidities invading the connective tissue, stenosis was not severe except at the level of the procedure, and central stenosis was more common than foraminal stenosis. In addition, most of the patients did not show the nature of neuropathic pain. In the case of patient E, dorsal root ganglion pulsed radiofrequency treatment was performed after balloon adhesiolysis, showing the nature of neuropathic pain.^[9] Neuropathic pain remaining after the procedure can be resolved by pulsed radiofrequency treatment and medication. This may be helpful in

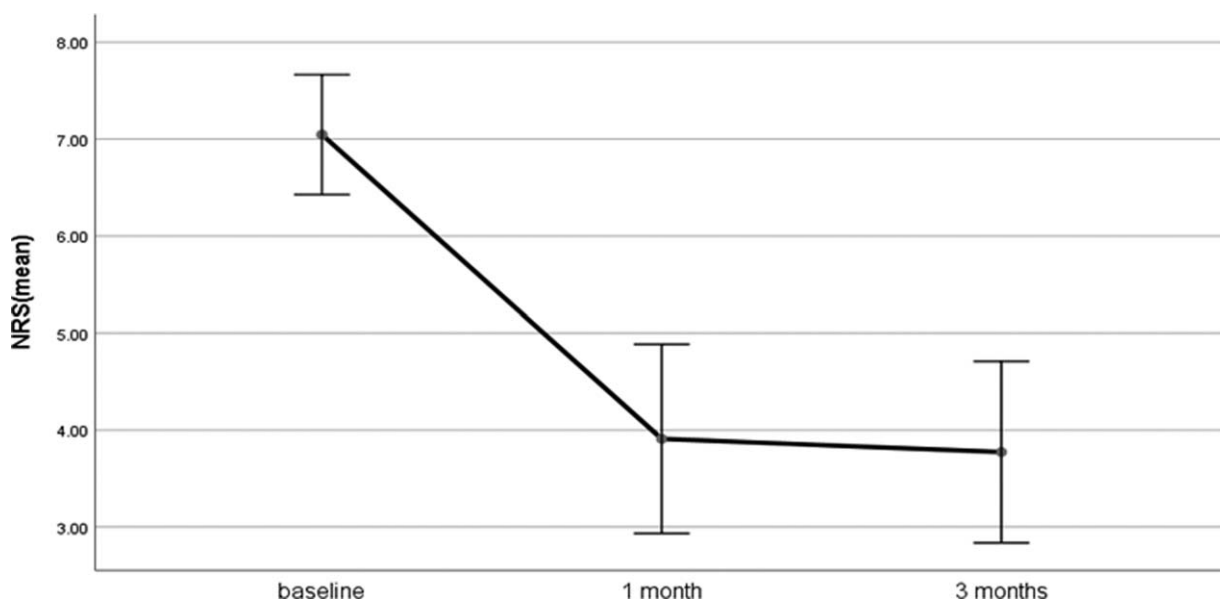


Figure 4. Patient outcome based on NRS pain score. Analyzed from Table 1. The mean basal NRS score was 7.05 ± 1.40 . After 1 month and 3 months, the mean NRS score was significantly decreased to 3.91 ± 2.20 and 3.46 ± 2.11 , respectively ($P < .01$). NRS=numeric rating scale.

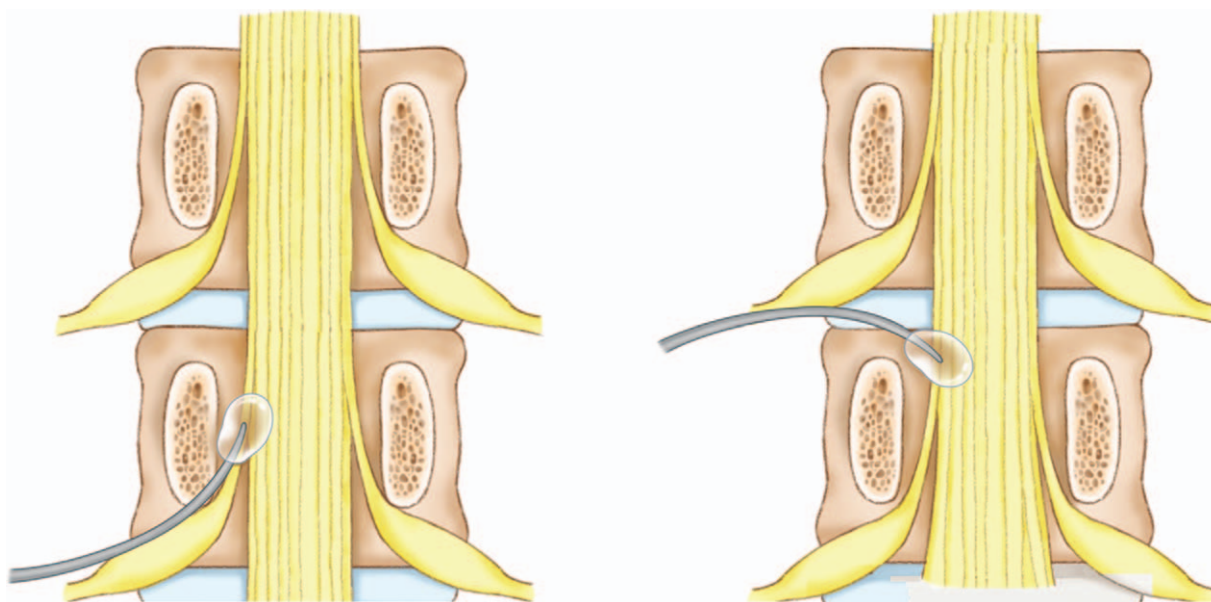


Figure 5. Schematic image of transforaminal and retrodiscal catheter placement.

selecting patients who are expected to benefit from retrodiscal epidural balloon decompression.

4.1. Technical considerations

The retrodiscal area can be reached by either the sacral hiatus or Kambin's triangle. The catheter used in our previous study was introduced through the sacral hiatus, and the introducer needle was thick, which caused the patient pain and increased the cost.^[1] The catheter used in the present report has the advantage that the needle is thinner, which reduces the pain of the patient and the risk of tissue damage. The procedure is easy to learn and can be performed in the clinic. However, the catheter used in the present report has disadvantages that make it inconvenient to apply in patients with multilevel lesions. Furthermore, due to the retrodiscal approach, there may be a problem of incidental intradiscal placement of the catheter.^[10] In the case of central stenosis at the L5–S1 level, if the height of the iliac crest is greater than that of the needle trajectory, the procedure may not be easy to perform. In such cases, the contralateral interlaminar approach may be used.

Several approaches through the foramen can be used with the catheter introduced in this study. The first is the safe-triangle approach, which can be a good indication for patients with single-level foraminal stenosis. The second is the Kambin's triangle approach, which can be used in patients with single-level retrodiscal pathology (Fig. 5). However, in patients with a combined (foraminal and central canal stenosis) case or multifocal pathology, it may be more beneficial to use the ZiNeu catheter through the sacral hiatus, as described in our previous study.^[1] As shown in Fig. 3, the position of the balloon must be in the vicinity of the inferior margin of the target level disc to effectively resolve the decompression and adhesiolysis of the compressed nerve moving downward.

4.2. Limitations

The disadvantages of this study are that it was not well-designed or well-controlled, it was not blinded because of its retrospective

nature, and no modality other than the NRS score was used to judge the effect of the treatment. There is also a problem with standardization of the procedure because it was performed by 2 pain specialists rather than 1. The symptoms of patients who have undergone the procedure tend to improve gradually over time. Therefore, a well-designed, long-term follow-up study is desirable.

5. Conclusions

Chronic pain caused from lumbar central stenosis, especially ipsilateral retrodiscal pathology, can be reduced by retrodiscal balloon adhesiolysis. Although this study is limited by its retrospective design, the results suggest that this procedure is a useful treatment due to its ease of performance and cost-effectiveness. It is hoped that the results of this study will help alleviate the pain of patients with spinal stenosis.

Author contributions

Conceptualization: Seong-Soo Choi, Jin-Woo Shin.

Data curation: Dong-Kyun Seo, Sookyung Lee, Gunn Lee, Myung-Su Lee, Syn-Hae Yoon, Seong-Soo Choi, Jin-Woo Shin.

Formal analysis: Dong-Kyun Seo, Seong-Soo Choi, Jin-Woo Shin.

Investigation: Dong-Kyun Seo, Sookyung Lee, Gunn Lee, Myung-Su Lee, Syn-Hae Yoon.

Methodology: Seong-Soo Choi, Jin-Woo Shin.

Supervision: Seong-Soo Choi, Jin-Woo Shin.

Writing – original draft: Dong-Kyun Seo.

Writing – review & editing: Seong-Soo Choi, Jin-Woo Shin. Seong-Soo Choi orcid: 0000-0002-2333-0235.

References

- [1] Choi SS, Lee JH, Kim DH, et al. Effectiveness and factors associated with epidural decompression and adhesiolysis using a balloon-inflatable catheter in chronic lumbar spinal stenosis: 1-year follow-up. *Pain Med* 2016;17:476–87.

- [2] Kim SH, Choi WJ, Suh JH, et al. Effects of transforaminal balloon treatment in patients with lumbar foraminal stenosis: a randomized, controlled, double-blind trial. *Pain Physician* 2013;16:213–24.
- [3] Choi SS, Joo EY, Hwang BS, et al. A novel balloon-inflatable catheter for percutaneous epidural adhesiolysis and decompression. *Korean J Pain* 2014;27:178–85.
- [4] Kim SH, Koh WU, Park SJ, et al. Clinical experiences of transforaminal balloon decompression for patients with spinal stenosis. *Korean J Pain* 2012;25:55–9.
- [5] Manchikanti L, Abdi S, Atluri S, et al. An update of comprehensive evidence-based guidelines for interventional techniques in chronic spinal pain. Part II: guidance and recommendations. *Pain Physician* 2013;16:S49–283.
- [6] Park JW, Nam HS, Cho SK, et al. Kambin's triangle approach of lumbar transforaminal epidural injection with spinal stenosis. *Ann Rehabil Med* 2011;35:833–43.
- [7] Fujiwara A, An HS, Lim TH, et al. Morphologic changes in the lumbar intervertebral foramen due to flexion-extension, lateral bending, and axial rotation: an in vitro anatomic and biomechanical study. *Spine (Phila Pa 1976)* 2001;26:876–82.
- [8] Mawrin C, Brunn A, Röcken C, et al. Peripheral neuropathy in systemic lupus erythematosus: pathomorphological features and distribution pattern of matrix metalloproteinases. *Acta Neuropathol* 2003;105:365–72.
- [9] Cahana A, Van Zundert J, Macrea L, et al. Pulsed radiofrequency: current clinical and biological literature available. *Pain Med* 2006;7:411–23.
- [10] Levi D, Horn S, Corcoran S. The Incidence of intradiscal, intrathecal, and intravascular flow during the performance of retrodiscal (infraneural) approach for lumbar transforaminal epidural steroid injections. *Pain Med* 2016;17:1416–22.