

Comparison between CT and MRI in the assessment of pulmonary embolism

A meta-analysis

Feng Chen^a, Yi-Hong Shen^b, Xu-Qing Zhu^c, Jing Zheng^a, Feng-Jie Wu^{d,*}

Abstract

Objective: Besides pulmonary arteriography, a number of imaging techniques, such as magnetic resonance imaging (MRI) and computed tomography (CT), were adopted in the detection of identifying pulmonary embolism (PE). However, the contrast of sensitivity and specificity in these methods was studied little in a statistical way. To compare the effects of MRI and CT, this study used a series of methods to analyze data in included researches.

Methods: A comprehensive computer search was conducted through internet up to July 2016. The quality assessment was performed by the Quality Assessment Tool for Diagnostic Accuracy Studies, version 2 tool. The diagnostic value of comparison between MRI and CT was evaluated by using the pooled estimate of sensitivity, specificity, and summary receiver operating characteristic (SROC) curve. In addition, sensitivity analysis and bias analysis were applied to ensure the accuracy of the results.

Results: Ten studies with 590 cases were involved in the study. Only 2 trials had high risk regarding bias while other trials were supposed to be at low risk of applicability. Heterogeneity existed in analysis of both CT and MRI. The pooled sensitivity of CT was 0.90 (95% CI: 0.85–0.93), pooled specificity was 0.88 (95% CI: 0.77 to 0.95), the pooled sensitivity of MRI was 0.92 (95% CI: 0.89–0.94), and pooled specificity was 0.91 (95% CI: 0.77–0.97). The Q index of sensitivity and specificity for CT and MRI were 71.38, 19.67, 47.14, and 12.35, respectively. The SROC curve area under the curve of CT and MRI were 0.94 (95% CI: 0.91–0.96) and 0.93 (95% CI: 0.91–0.95), respectively.

Conclusion: This meta-analysis demonstrates that MRI has better sensitivity and specificity in detecting subsegmental artery PE. MRI is a relatively better detection technique for PE. This conclusion is consistent with many published researches.

Abbreviations: AUC = area under the curve, CT = computed tomography, MRI = magnetic resonance imaging, PAG = pulmonary arteriography, PE = pulmonary embolism.

Keywords: computed tomography, magnetic resonance imaging, meta-analysis, pulmonary embolism

1. Introduction

Pulmonary embolism (PE) is widely acknowledged as one of the most frequently encountered medical emergencies that is easily neglected and misdiagnosed, and can result in mortality. The reference method, conventional pulmonary angiography, is

invasive and carries small risk of complications.^[1–4] Therefore, diagnostic strategies are often complex, consisting of noninvasive diagnostic tests, such as plasma D-dimer measurement, lung scintigraphy, and ultrasonography of the leg veins, to try to avoid conventional pulmonary angiography for as many patients as possible.^[5–7]

Among the various imaging modalities, pulmonary computed tomography (CT) is recommended as the first-line method. Although it is considered as an essential diagnostic way for the detection of PE, and it is contraindicated in patients who are allergic to iodinated contrast media or who have reduced renal function. In such cases, ventilation-perfusion scintigraphy and magnetic resonance imaging (MRI) are alternatives.^[8–11]

In recent years, there have been notable technical progresses in MRI, allowing us to better evaluate the lung. Certain techniques have been shown useful for detecting PEs. According to other researches, there have been little previous studies of comparison between CT and MRI in regard to diagnosing PE.^[12–15]

The purpose of our study was to perform a preliminary assessment of CT compared with MRI for diagnosing PE.

2. Methods

2.1. Ethics approval

The requirement of ethics approval was waived because there are no human beings or animals involved in this study

Editor: Levent Dalar.

FC and Y-HS are co-first authors.

The authors have no conflicts of interest to disclose.

^a Department of Respiratory Medicine, Taizhou Municipal Hospital, Taizhou,

^b Department of Respiration, The First Affiliated Hospital, Zhejiang University,

Hangzhou, ^c Department of Gastroenterology, Taizhou Municipal Hospital,

Taizhou, ^d Department of Respiratory Medicine, The Second Hospital of Jiaxing, Jiaxing, China.

* Correspondence: Feng-Jie Wu, Department of Respiratory Medicine, The Second Hospital of Jiaxing, Nanhu District, Jiaxing, China (e-mail: juehui820923@163.com).

Copyright © 2017 the Author(s). Published by Wolters Kluwer Health, Inc.

This is an open access article distributed under the terms of the Creative Commons Attribution-Non Commercial-No Derivatives License 4.0 (CCBY-NC-ND), where it is permissible to download and share the work provided it is properly cited. The work cannot be changed in any way or used commercially without permission from the journal.

Medicine (2017) 96:52(e8935)

Received: 13 March 2017 / Received in final form: 7 September 2017 /

Accepted: 8 November 2017

<http://dx.doi.org/10.1097/MD.0000000000008935>

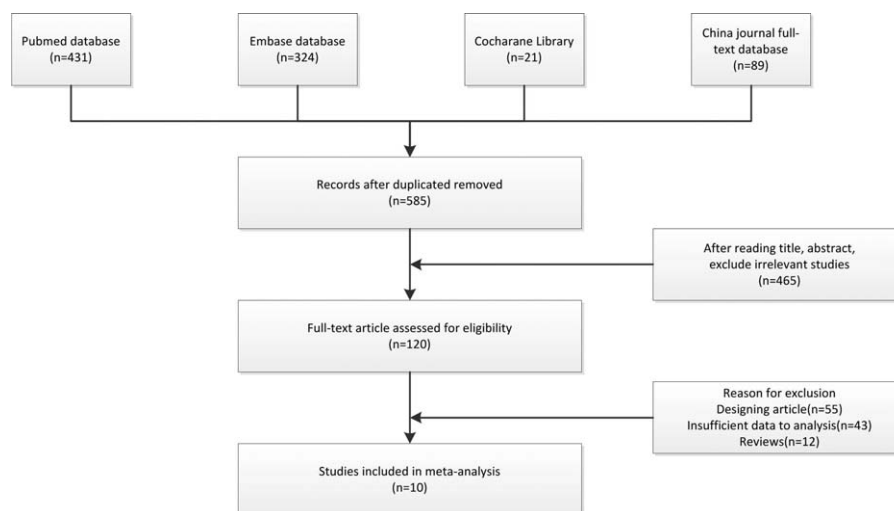

Figure 1. Flow diagram of the study selection.

2.2. Literature search strategy

Related articles about the comparison between CT and MRI in the assessment of PE were systematically searched in all publication status (published, unpublished, in press, and in progress) among multiple databases including PubMed, EMBASE, Library Cochrane, and China Journal Full-text Database, from January 1981 to July 2016. Two researchers carried out literature search independently. The search terms were as follows: (1) “CT” OR “computed tomography” OR “MRA” OR “computed tomography angiography”; (2) “MRI” OR “magnetic resonance imaging” OR “CTA” OR “magnetic resonance angiography”; (3) “PE” OR “pulmonary embolism” OR “PTE” OR “pulmonary thromboembolism”. These keywords were combined to seek for the researches using the Boolean operator “and” without languages restriction. In addition, the reference catalogues of all retrieved papers were checked for qualified articles which were not included as abovementioned.

2.3. Study selection

The inclusion criteria were as follows: CT and MRI were used to detect PE; the sensitivity and specificity of CT and MRI were clearly noted; the complications happened in treatment were clearly declared; at least 10 patients entered; no lapping data was included.

Two authors assessed possibly related articles independently complying inclusion criteria and exclusion criteria. If there is disagreement between 2 researchers, a third author will help to solve it.

2.4. Data extraction and quality assessment

There were 2 reviewers independently scanning the full text of the manuscripts and extracting the following data from each eligible research: first author’s name, country of origin, publication year, sampling size, study period, age, and gender of the patients in each article. The methodological quality of the studies was evaluated by Quality Assessment Tool for Diagnostic Accuracy Studies, version 2 (QUADAS-2), which is an improvement over

the original one since it consider more transparent rating of bias and applicability of primary diagnostic accuracy studies.

2.5. Statistical analysis

Stata (Version 12.0, Stata Corp LP, College Station, TX, 2011) was adopted to carry out synthesis analysis and publication bias detection. The effect scope involved sensitivity, specificity, and area under the curve (AUC). When comparing sensitivity and specificity of different imaging techniques, Cochrane’s Q test and I^2 statistic were performed for heterogeneity. Studies with an I^2 of 25% to 50% were considered low heterogeneity, I^2 of 50% to 75% was considered moderate heterogeneity, and $I^2 > 75%$ was considered high heterogeneity. If $I^2 > 50%$, there exists significant heterogeneity, in which case a random model (Der Simonian and Laird method) was used. Otherwise, a fixed model (Mantel-Haenszel method) was applied. Publication bias for diagnostic accuracy test was detected by Deek’s funnel plot asymmetry test and a $P \leq .10$ was considered significant publication bias. A 2-tailed $P \leq .05$ indicated statistical significance for outcomes of publication bias test. To obtain the post-test probability, Fagan’s nomogram was used at a pretest probability of 20% based on previously reported incidence.

3. Results

3.1. Search process

The initial search found 865 related publications, in which 280 were excluded for duplication. After the screening based on the titles and abstracts, 120 articles were remained. Then, 110 researches were excluded because of type of article and insufficient data. In the end, 10 articles were selected for this meta-analysis, in which 7 were published in English and 3 in Chinese. The study selection process is detailed in Figure 1.

3.2. Characteristics of included studies

There were 10 articles comprising a total sample size of 590 patients with PE meeting all inclusion and exclusion criteria, and then were included in this meta-analysis. The sampling sizes of

Table 1**Characteristics of studies included in the meta-analysis of comparison of URSL and ESWL for the treatment of ureteric calculi.**

Study	Nation	Recruitment time	Groups	n	Age, year	Male/Female
Kluge et al (2006) ^[16]	Germany	August 2002–June 2003	MRI	41	53.1 ± 12.3	21/20
			CT	41	54.2 ± 10.1	22/19
Yang and Yang (2012) ^[17]	China	October 2005–December 2010	MRI	40	52.6 ± 8.5	28/12
			CT	40	50.1 ± 7.4	22/18
Kanne (2004) ^[18]	USA	March 2000–May 2002	MRI	12	47.3 ± 8.5	8/4
			CT	12	51.2 ± 7.4	9/3
Jianbo (2012) ^[19]	China	January 2006–June 2010	MRI	50	53.5 ± 7.5	28/22
			CT	50	54.2 ± 8.3	31/19
Hu (2016) ^[20]	China	January 2013–2016	MRI	30	56.4 ± 13.8	18/12
			CT	30	57.2 ± 15.6	17/13
Revel (2012) ^[21]	France	May 2007–2009	MRI	37	51.8 ± 5.4	25/12
			CT	37	50.1 ± 5.2	27/10
Oudkerk et al (2002) ^[22]	The Netherlands	January 1999–May 2001	MRI	13	50.5 ± 5.8	9/4
			CT	13	52.4 ± 5.8	11/2
Ishiyama et al (2011) ^[23]	Japan	November 2008–April 2009	MRI	10	58.6 ± 12.1	5/5
			CT	10	57.8 ± 11.7	5/5
Patrick et al (2003) ^[24]	Germany	March 2000–2002	MRI	20	54.9 ± 4.2	12/8
			CT	20	53.2 ± 10.6	14/6
Tang (2013) ^[25]	China	January 2009–2012	MRI	42	52.9 ± 6.2	28/14
			CT	42	49.9 ± 4.6	30/12

CT = computed tomography, MRI = magnetic resonance imaging.

these studies varied from 20 to 100. These researches were performed in America, Europe, and Asia. The publication date of 10 trails ranged from 2003 to 2016. Most of the researches were published in English with 3 in Chinese. All of the 10 studies were conducted in a prospective controlled design. The scope of age among patients was from 47.3 to 58.6 and in all the trials the number of male is more than that of female. The gold standard of 10 studies was based on pulmonary arteriography, which was rarely clinical used now. About the sampling time, it ranges from 1 to 5 years. The characteristics of the involved researches are shown in Table 1.

3.3. Results of quality assessment

The QUADAS-2 tool was used to evaluate the risk of bias in the 10 trials in which none trials showed problems in patient selection, 4 showed problems in index test, 1 showed problems in reference standard, and 3 trials showed problems in the flow and time. When applicability was taken into consideration, none

trials performance any problems. In general, 2 trials were at risk of bias and 8 ones were out of risk. All the trials had little trouble regarding applicability. The detailed results of the quality assessment are listed in Table 2.

3.4. Results of heterogeneity test

Figure 2 shows that the heterogeneity among studies. I^2 of sensitivity and specificity for CT and MRI of detection in subsegmental level were 53.23%, 87.75%, 6.96%, and 84.43%, respectively. Consequently, a random-effect model was applied for data synthesis. The bivariate random-effects model for CT showed a pooled sensitivity of 0.90 (95% confidence interval [CI]=0.85–0.93), a pooled specificity of 0.88 (95%CI=0.77–0.95). The bivariate random-effects model for MRI showed a pooled sensitivity of 0.92 (95% CI=0.89–0.94) and a pooled specificity of 0.91 (95% CI=0.77–0.97). Forest plots of the pooled sensitivities and specificities derived from the model for MRI and CT are shown in Figure 2.

Table 2**Results of QUADAS-2 quality assessment for each trial.**

	Risk of bias					Concerns of applicability			
	Patient selection	Index test	Reference standard	Flow and time	Overall	Patient	Index test	Reference standard	Overall
Kluge et al (2006)	Yes	?	Yes	Yes	Low	Yes	Yes	Yes	Low
Yang and Yang (2012)	?	No	No	Yes	High	Yes	Yes	Yes	Low
Kanne (2004)	Yes	No	Yes	No	High	Yes	Yes	Yes	Low
Jianbo (2012)	?	?	Yes	No	Low	Yes	Yes	Yes	Low
Hu (2016)	Yes	?	Yes	?	Low	Yes	Yes	Yes	Low
Revel (2012)	Yes	No	Yes	Yes	Low	Yes	Yes	Yes	Low
Oudkerk et al (2002)	Yes	Yes	Yes	Yes	Low	Yes	Yes	Yes	Low
Ishiyama et al (2011)	?	Yes	Yes	No	Low	Yes	Yes	Yes	Low
Patrick et al (2003)	Yes	?	Yes	?	Low	Yes	Yes	Yes	Low
Tang (2013)	Yes	No	Yes	Yes	Low	Yes	Yes	Yes	Low

No = high risk, ? = unclear risk, QUADAS-2 = Quality Assessment Tool for Diagnostic Accuracy Studies, version 2, Yes = low risk.

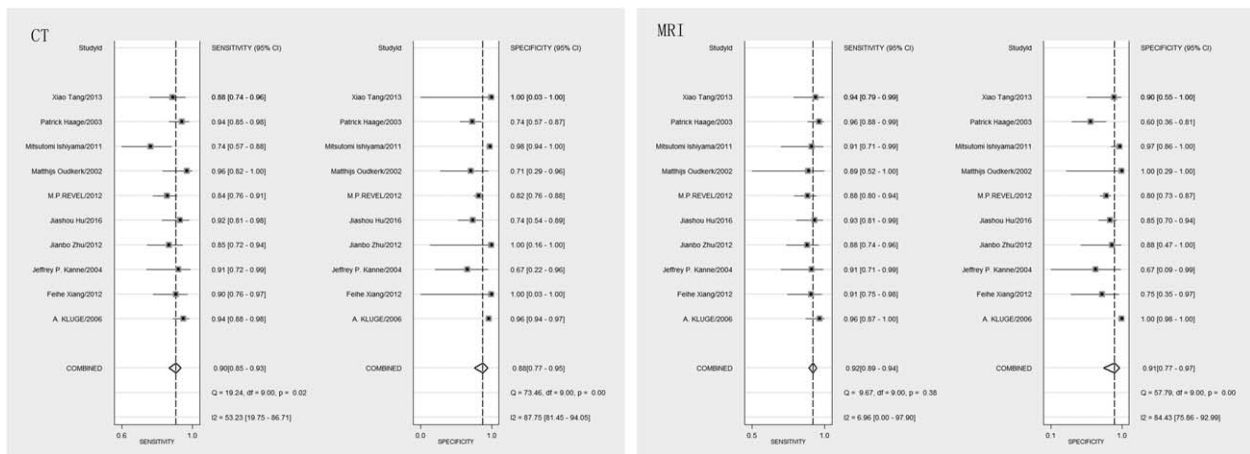


Figure 2. Forest plots of the sensitivities and specificities of CT versus MRI. CT = computed tomography, MRI = magnetic resonance imaging.

3.5. Results of meta-analysis

Figure 3 shows the summary receiver operating characteristic (SROC) curves. In Figure 3, the SROC curve, AUC of CT and MRI in subsegmental detection level were 0.94 (95% CI: 0.91–0.96) and 0.93 (95% CI: 0.91–0.95), respectively. The pooled estimate of the positive diagnostic likelihood ratio for CT was 7.68 (95% CI=3.71–15.92), with a Q statistic=71.38 and $I^2=80.85$. The pooled estimate of the negative diagnostic likelihood ratio for MRI was 0.12 (95% CI=0.08–0.16), with a Q statistic=19.67 and $I^2=54.24$. The pooled estimate of the positive diagnostic likelihood ratio for CT was 10.30 (95% CI=3.66–28.99), with a Q statistic=47.14 and $I^2=69.82$. The pooled estimate of the negative diagnostic likelihood ratio for CT was 0.09 (95% CI=0.06–0.13), with a Q statistic=12.35 and $I^2=27.13$. Using Fagan’s nomogram with a fixed pretest probability of 20%, the above positive and negative likelihood ratios were used to calculate the post-test probability (Fig. 4). The post-test probability after CT was 66% given the positive test result and was 3% given the negative test result. The post-test probability after MRI was 72% given the positive test result and was 2% given the negative test result.

3.6. Results of sensitivity analysis and publication bias

Publication bias was examined by funnel plot and Begg’s test. These provided referenced evidence of publication bias for the outcome of DOR (P value of Begg’s test for CT and MRI were .25 and .45 respectively). The funnel plot is shown in Figure 5.

4. Discussion

PE is pulmonary dysfunction syndrome caused by endogenous or exogenous embolus or its branch. Since its clinical manifestations varied, misdiagnosis or missed diagnosis often occur.^[26–28] Therefore, accurate and rapid detection technique is imperative for the treatment of PE. Pulmonary angiography is considered the “gold standard” for diagnosis of PE, and can make qualitative and quantitative diagnosis to PE. However, it has its shortages like relatively large trauma. CT has a good accuracy in the diagnosis of PE, and technique of CT is still improving. It can show clear image of PE and is convenient to build 3D model. As high-definition MRI applied, the detection of PE in early stage has a progress. MRI is a good choice for patients who do not accept contrast media or radioactive detection.^[29–32]

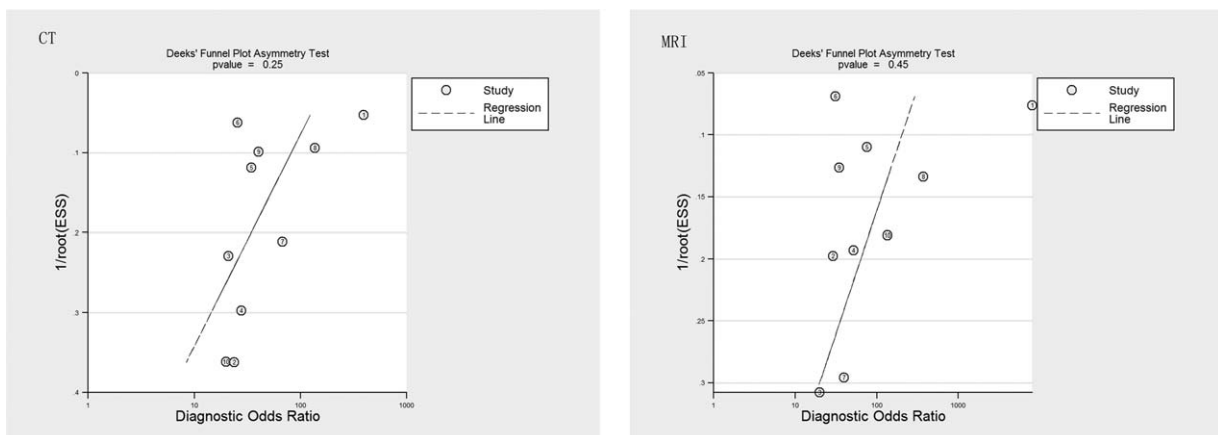


Figure 3. Summary of the ROC curves for CT versus MRI with prediction and confidence contours. CT = computed tomography, MRI = magnetic resonance imaging, ROC= receiver operating characteristic.

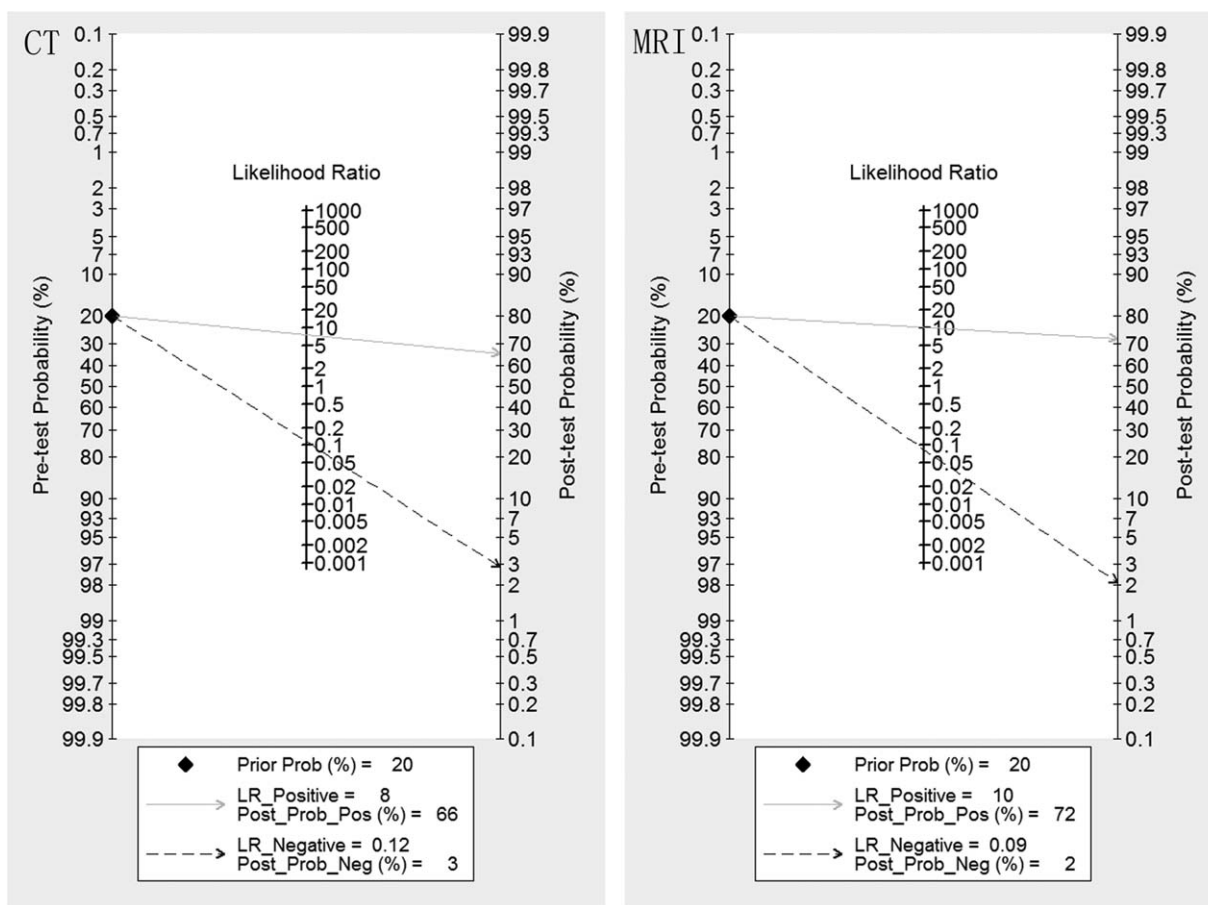


Figure 4. Fagan plot analysis of CT versus MRI for detecting pulmonary embolism. CT = computed tomography, MRI = magnetic resonance imaging.

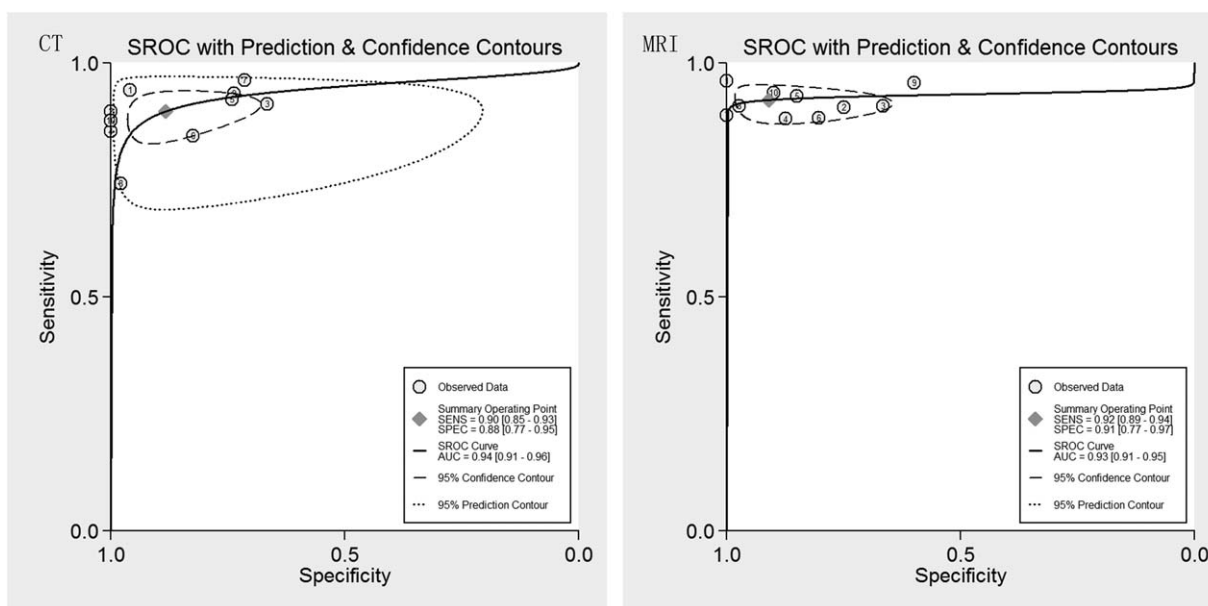


Figure 5. Funnel plot analysis of CT versus MRI. CT = computed tomography, MRI = magnetic resonance imaging.

In Figure 2, the contrast of sensitivity and specificity of CT were 0.90 (95% CI=0.85–0.93) and a pooled specificity of 0.88 (95% CI=0.77–0.95). The bivariate random-effects model for MRI showed a pooled sensitivity of 0.92 (95% CI=0.89–0.94) and a pooled specificity of 0.91 (95% CI=0.77–0.97). MRI had a relatively better values of these 2 parameters. Since both of them had their advantages, the difference between these 2 technologies was small. Chen reported that CT and MRI both are valuable detections for PE, and his results showed that sensitivity and specificity of CT were 0.78 (95% CI=0.74–0.82) and 0.90 (95% CI=0.87–0.92), respectively. Those of MRI were 0.86 (95% CI=0.79–0.92) and 0.97 (95% CI=0.94–0.99), respectively.^[33] The conclusion of his research is consistent with this article. Use of CT in detecting pulmonary trunk, interlobar, and segmental artery was greatly accurate. However, in diagnosing subsegmental and peripheral vessels proved more difficult. Compared with CT, MRI allowed for the acquisition of multidimensional images and was superior to CT in revealing smaller pulmonary vessels branches. Meanwhile, MRI was convenient and precise in examination of deep vein in pelvis and lower limbs.^[20,21]

In Figure 3, the SROC curve AUC of CT and MRI were 0.94 (95% CI: 0.91–0.96) and 0.93 (95% CI: 0.91–0.95), respectively. CT had a little better SROC curve AUC. This small difference between CT and MRI demonstrated that both ways for PE diagnosis were good choice for patients. The post-test probability after CT was 66% given the positive test result and was 3% given the negative test result. The post-test probability after MRI was 72% given the positive test result and was 2% given the negative test result. These proved that MRI is a relatively better way to detect PE in subsegmental artery. This consequence was in accord with Han's research.^[34] In his article, he emphasized the progress of MRI which help MRI to be a useful selection.

Taking publication bias into consideration, there still existed several limitations. First, the analysis could be more abundant if data was comprehensive. Second, the total sampling size was needed to be more since a big sampling capacity can provide a more trustworthy result.

5. Conclusion

Various imaging techniques, such as PGA, CT, and MRI were adopted in the detection of PE. Little research focused on the contrast between CT and MRI. In this meta-analysis, QUADAS-2, sensitivity-analysis, SROC, and bias-analysis were conducted. After the test of possible risk, the conclusion is that MRI is a relatively better technique to diagnose subsegmental artery PE.

References

- Gouveia M, Pinheiro L, Costa J, et al. Pulmonary embolism in Portugal: epidemiology and in-hospital mortality. *Acta Med Port* 2016;29:432–40.
- Rush B, Wiskar K, Berger L, et al. The use of thrombolysis for acute pulmonary embolism in the United States: national trends and patient characteristics from 2006 to 2011. *J Emerg Med* 2016;11:223–8.
- Flannery MT, Humphrey D. Deep venous thrombosis with pulmonary embolism related to IVIg treatment: a case report and literature review. *Case Rep Med* 2015;12:713–21.
- Goy J, Lee L, Levine O, et al. Sub-segmental pulmonary embolism in three academic teaching hospitals: a review of management and outcomes. *J Thromb Haemost* 2015;13:214–8.
- Byrne JP, Geerts W, Mason SA, et al. Effectiveness of low molecular weight heparin versus unfractionated heparin to prevent pulmonary embolism following major trauma: a propensity-matched analysis. *J Trauma Acute Care Surg* 2016;32:144–9.
- Aguilhon S, Vandenberghe D, Roubille F. A pulmonary embolism (PE) with an unexpected intracardiac mass but without shock: Should we use thrombolytic therapy? About a case of a 88year old man with suspicion of PE. *Int J Cardiol* 2016;45:323–8.
- Yue K. Diagnostic efficiency for pulmonary embolism using magnetic resonance imaging method: a meta-analysis. *Int J Clin Exp Med* 2015;8:14416–23.
- Wang L, Xu Y, Zhang W, et al. Early interventional therapy for acute massive pulmonary embolism guided by minimally invasive hemodynamic monitoring. *Int J Clin Exp Med* 2015;8:14011–7.
- Kumar N, Xie K, Mar W, et al. Software-based hybrid perfusion SPECT/CT provides diagnostic accuracy when other pulmonary embolism imaging is indeterminate. *Nucl Med Mol Imaging* 2015;49:303–11.
- Mazurek A, Dziuk M, Witkowska-Patena E, et al. The utility of hybrid SPECT/CT lung perfusion scintigraphy in pulmonary embolism diagnosis. *Respiration* 2015;90:393–401.
- Aviram G, Shmueli H, Adam SZ, et al. Pulmonary hypertension: a nomogram based on CT pulmonary angiographic data for prediction in patients without pulmonary embolism. *Radiology* 2015;27:236–46.
- Mudge CS, Healey TT, Atalay MK, et al. Feasibility of detecting pulmonary embolism using noncontrast MRI. *ISRN Radiol* 2013;33:729271.
- Hochegger B, Zanetti G, Marchiori E. MRI in acute pulmonary embolism: a valuable alternative in the assessment of suspected acute pulmonary embolism. *Chest* 2011;140:1391–2.
- Heredia V, Altun E, Ramalho M, et al. MRI of pregnant patients for suspected pulmonary embolism: steady-state free precession vs post-gadolinium 3D-GRE. *Acta Med Port* 2012;25:359–67.
- Vidmar J, Kralj E, Bajd F, et al. Multiparametric MRI in characterizing venous thrombi and pulmonary thromboemboli acquired from patients with pulmonary embolism. *J Magn Reson Imaging* 2015;42:354–61.
- Kluge A, Gerriets T, Stolz E, et al. Pulmonary perfusion in acute pulmonary embolism: agreement of MRI and SPECT for lobar, segmental and subsegmental perfusion defects. *Acta Radiol* 2006;47:933–40.
- Yang F, Yang L. The diagnosis value of spiral CT and MRI imaging in pulmonary embolism. *China Modern Doctor* 2012;99–100.
- Kanne JP, Lalani TA. Role of computed tomography and magnetic resonance imaging for deep venous thrombosis and pulmonary embolism. *Circulation* 2004;109(12 suppl 1):1015–21.
- Zhu J. Study of distribution feature and accuracy in pulmonary embolism diagnosing by CT and MRI. *China Med Herald* 2012;90–1.
- Hu J, Li Z, Qu Y, et al. Characteristics and clinical value of 3D MR imaging in the diagnosis of pulmonary embolism. *Exp Ther Med* 2016;12:1760–4.
- Revel MP, Sanchez O, Couchon S, et al. Diagnostic accuracy of magnetic resonance imaging for an acute pulmonary embolism: results of the 'IRM-EP' study. *J Thromb Haemostasis* 2012;10:743–50.
- Oudkerk M, van Beek EJ, Wielopolski P, et al. Comparison of contrast-enhanced magnetic resonance angiography and conventional pulmonary angiography for the diagnosis of pulmonary embolism: a prospective study. *Lancet* 2002;359:1643–7.
- Ishiyama M, Matsusako M, Oikado K, et al. Three-dimensional T2-weighted imaging using the dark blood method for detecting pulmonary embolisms: comparison with computed tomography angiography. *Jap J Radiol* 2011;29:667–72.
- Patrick H, Werner P, et al. Comparison of angiography with spiral computed tomography, magnetic resonance angiography, and real-time magnetic resonance imaging. *Am J Resp Crit Care Med* 2003;52:167.
- Tang X. The diagnostic value and image feature of Spiral CT and Mm imaging in pulmonary embolism. *Chin J Prim Med Pharm* 2013;20:172–3.
- Peiman S, Abbasi M, Allameh SF, et al. Subsegmental pulmonary embolism: a narrative review. *Thromb Res* 2016;138:55–60.
- Zhou M, Hu Y, Long X, et al. Diagnostic performance of magnetic resonance imaging for acute pulmonary embolism: a systematic review and meta-analysis. *J Thromb Haemost* 2015;13:1623–34.
- Hughes MJ, Stein PD, Matta F. Silent pulmonary embolism in patients with distal deep venous thrombosis: systematic review. *Thromb Res* 2014;134:1182–5.
- Den E, Parker L, et al. Thromboembolic resolution assessed by CT pulmonary angiography after treatment for acute pulmonary embolism. *Thromb Haemost* 2015;114:26–34.
- Atasoy M, Manny M, Levent E, et al. Nonsevere acute pulmonary embolism: prognostic CT pulmonary angiography findings. *J Comput Assist Tomogr* 2015;39:166–70.
- Revel MP, Sanchez O, Lefort C, et al. Diagnostic accuracy of unenhanced, contrast-enhanced perfusion and angiographic MRI

- sequences for pulmonary embolism diagnosis: results of independent sequence readings. *Eur Radiol* 2013;23:2374–82.
- [32] Poyraz N, Demirba S, Korkmaz C, et al. Pulmonary embolism originating from a hepatic hydatid cyst ruptured into the inferior vena cava: CT and MRI findings. *Case Rep Radiol* 2016;22:358–64.
- [33] Song C, Ruwu Y, Youmin G. Diagnostic value of CT angiography and MR angiography for acute pulmonary embolism based on Meta-analysis. *Radiol Pract* 2014;29:1409–14.
- [34] Han Z. Research about progress of CT and MR in pulmonary embolism. *China Med Herald* 2008;5:21–2.