

CASE REPORT

The Role of Chemotherapy and Prophylactic Bilateral Oophorectomy in a Case of Colorectal Adenocarcinoma with Ovarian Metastases

Eon K. Shin^a, Bayan T. Takizawa, Louise Masters, and Shohreh Shahabi

Department of Obstetrics and Gynecology, Yale University School of Medicine, New Haven, Connecticut

A 66-year-old female presented with a large abdominal mass and accompanying systemic complaints of abdominal pain, constipation, and fever. On exploratory laparotomy, the mass was found to be a moderately differentiated adenocarcinoma of the sigmoid colon with metastasis to the left ovary. A primary colorectal carcinoma that has metastasized to the ovaries can be difficult to distinguish clinically from an advanced primary ovarian tumor. Histology and tumor markers are currently the most useful tools available in making an accurate diagnosis. If the nature of the primary tumor is uncertain and the initial response to chemotherapy is poor, the patient's prognosis will also be poor. Though controversy exists regarding the role of prophylactic bilateral oophorectomy during resection for primary colorectal cancer, later confusion can be avoided by performing this procedure when the colorectal carcinoma is first diagnosed. However, the possibility of a concurrent primary ovarian tumor must not be overlooked.

INTRODUCTION

The etiology of tumors in the lower abdomen is sometimes difficult to establish, both clinically and after standard investigation. Both the origin of the primary tumor and the stage of the disease have considerable influence on the prognosis of patients [1]. For example, a diagnosis of ovarian carcinoma infiltrating the recto-sigmoid region would imply a fair prognosis following long-term aggressive

chemotherapy; an advanced colorectal carcinoma with ovarian metastasis, however, carries a poorer prognosis with little response to chemotherapy. While a number of papers have been published describing this diagnostic problem, a clear diagnostic approach and therapeutic policy are lacking. This case report involves a carcinoma of the sigmoid colon presenting as an ovarian tumor mass.

^a *To whom all correspondence should be addressed:* Eon K. Shin, 367 Cedar Street, New Haven, Connecticut 06510. Tel.: (203) 777-2312; Fax: (203) 777-2312; E-mail: Shinek@bio-med.med.yale.edu..

^b *Abbreviations:* CEA, carcinoembryonic antigen; MRI, magnetic resonance imaging; CT, computed tomography.

Received: May 24, 2000; Returned for revision: October 19, 2000; Accepted: December 5, 2000.

CASE REPORT

A 66-year-old Caucasian woman presented with abdominal pain, constipation, and fever of two weeks duration. She had a complicated medical history that included a subtotal hysterectomy for benign disease with conservation of the ovaries and a right mastectomy with axillary dissection and radiotherapy for breast cancer, which had been in remission for 10 years. On examination, a hypogastric mass extending into the left iliac fossa was palpated. The mass was fixed in the pelvis and measured 11 x 16 cm. Laboratory values were notable for an increased C-reactive protein level (16 mg/100ml, N 0-1 mg/100 ml) and CA-125 level (295 IU/l, N < 35 IU/l). The CEA^b level was found to be within normal limits. A pelvic MRI scan showed the mass to be irregular and partially solid. It did not appear to originate from either the cervix or the bladder, or to be invading the rectum or sigmoid colon (Figure 1). There was no evidence of ascites, but enlarged lymph nodes were detected in the left common iliac chain. A barium enema revealed an irregular stenosis in a 6 cm

region of the sigmoid colon, representing either a primary tumor or direct invasion from outside the lumen.

At laparotomy, a mass was found in the left adnexa measuring 11 x 11 x 7 cm and weighing 1050 grams. This mass was white and loculated in appearance, with both solid and necrotic areas. Examination of the colon confirmed an indurated zone at the level of the sigmoid stenosis. The operation was completed with simultaneous bilateral oophorectomy, lymphadenectomy, omentectomy, and partial colectomy (20 cm in length). Macroscopically, the sigmoid tumor was an ulcerated, stenotic mass of 3 cm diameter invading the entire thickness of the bowel wall. The resection margins were free of tumor. The final histopathology report suggested a moderately differentiated adenocarcinoma of the sigmoid colon with metastasis to the left ovary. The study of a number of immunohistochemical markers on a section of the excised left ovary confirmed the tumor to be of digestive origin.

After six courses of adjuvant chemotherapy with 5-fluorouracil and folinic acid rescue, the CA-125 level was

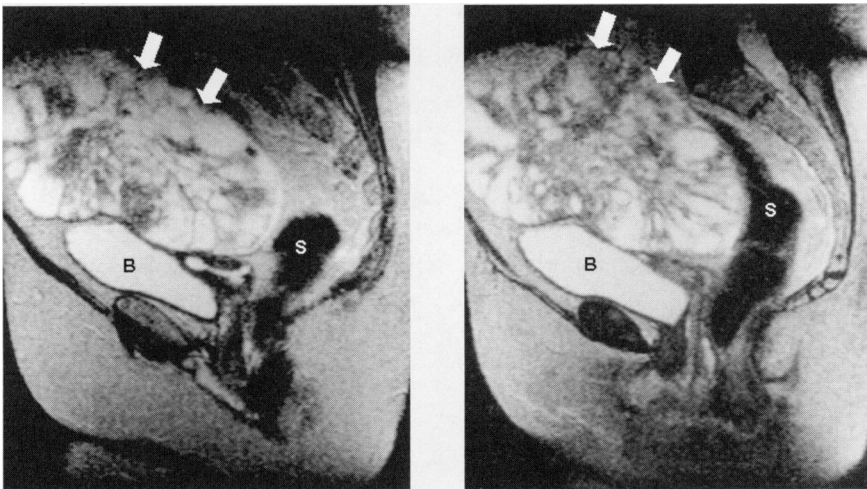


Figure 1. Sagittal pelvic MRI scans revealing a large, irregularly shaped pelvic mass (arrows) in close proximity to the bladder (B) and sigmoid colon.

found to be in normal range and no longer elevated. A follow-up MRI scan six months later, however, revealed two large pelvic masses compressing the right ureter. To cover the possibility of an ovarian primary, the patient was then treated with four doses of carboplatin and cyclophosphamide. A repeat MRI scan showed the masses to be larger and more heterogeneous than before, the largest measuring 10.7 x 12.4 x 11.4 cm, displacing and compressing the rectum and the bladder, and causing bilateral hydronephroses. The origin of these masses was still unclear. A nephrostomy tube was sited to drain the build-up of fluid in the kidneys, and the patient was started on a course of paclitaxel. After four courses, the masses continued to enlarge. At the patient's request, the treatment was continued, this time with weekly courses of high dose 5-fluorouracil. The patient died, however, after the sixth course of treatment.

DISCUSSION

Ovarian metastases represent up to 20 percent of malignant tumors of the ovary, are usually bilateral (50 to 70 percent of cases), and are often occult (6 to 25 percent) [1, 2, 3]. The primary tumor can originate in bowel (usually gastric or colonic), breast, thyroid, adrenal, or bladder tissue. Malignant melanoma can also metastasize to the ovary. Colorectal carcinoma metastasizes to the ovaries in up to 10 percent of cases [2, 4]. In these situations, the incidence of ovarian involvement does not appear to be dependent on the size, stage, or degree of differentiation of the primary tumor [5]. However, the risk significantly increases during the reproductive years [6], and the preferred route of spread appears to be hematogenous, although transcoelomic spread can also occur in some cases.

Ovarian metastases tend not to present as large masses, as in this case report.

When they do, however, they are easily confused with a primary ovarian tumor. The clinical symptoms of metastatic ovarian disease are similar to those of primary epithelial carcinomas of the ovary. If there are no specific symptoms from the primary site to alert the clinician, the presenting symptoms may be no more than a fever of unknown origin, chronic abdominal bloating, constipation, and vague lower abdominal pain, often described as a "dragging" sensation or a feeling of heaviness. Careful abdominal palpation and a bimanual pelvic examination may reveal a mass and give cause for further investigation.

The tumor marker CA-125 is raised in 80 to 90 percent of primary ovarian adenocarcinomas [7, 8], but is non-specific and can be elevated in a variety of benign diseases. As this case illustrates, it can also be raised in metastatic ovarian disease and is not reliable as a marker to follow treatment progress.

In this case, an MRI scan was performed without recourse to CT scan or ultrasound due to the acute nature of the patient's symptoms and the need for a rapid diagnosis. MRI scans [9] may be more accurate than CT scans in distinguishing primary ovarian tumors from metastases, but data are limited. The use of transvaginal ultrasound scanning with Doppler studies have also proven to be useful in the evaluation of ovarian masses [8, 10, 11]. Krukenberg tumors have been shown to have ultrasonographic features that distinguish them from ovarian primaries [11], but there are no other studies which focus on other types of ovarian metastases. If it is suspected that the primary tumor is colonic, a barium enema should be performed promptly, with other imaging techniques kept in reserve. Often the final diagnosis can only be made with authority by the histopathology department. Cytokeratin immunohistochemical staining is also a useful adjunct in the differential diagnosis.

There appears to be a definite trend toward routine bilateral oophorectomy as part of the treatment for colorectal tumors [6, 12, 13, 14] as the high frequency of these insidious metastases is recognized, but this is still a point of contention. It is known that macroscopic ovarian metastases found at the time of operation for colorectal carcinoma carry a poor prognosis [15]; however, the evidence for prophylactic oophorectomy in the absence of macroscopic disease is conflicting [16, 17], especially in the pre-menopausal patient. The median survival for a patient with an ovarian metastasis is 18 months. Some series report a five-year survival rate of 33 percent with prophylactic oophorectomy [18], which might justify the more aggressive approach of removing the ovaries in a curative attempt. Results from larger prospective studies are expected to address this controversial issue [19]. Some authors claim that the only real benefit to prophylactic oophorectomy lies in the prevention of a primary ovarian tumor in the post-menopausal group [5, 20], but other studies contend that menopausal status has no effect on patient outcomes [15, 17].

A retrospective study on women with a history of colorectal carcinoma undergoing oophorectomy for a new tumor revealed an ovarian metastasis in 57 percent of cases and primary ovarian neoplasms in only 13 percent. The prognosis for an ovarian carcinoma which has not responded to first- and second-line chemotherapy is as poor as that for a primary colorectal tumor with ovarian metastasis [21]. Thus, there seems to be little benefit to the patient in pursuing further chemotherapeutic options in cases where the nature of the primary is still in doubt.

CONCLUSION

The possibility of an ovarian metastasis must be considered early to avoid confusion in more advanced disease, to guide

the choice of treatment, and to improve the accuracy of prognostic prediction. We consider no malignant ovarian tumor to be fully investigated until the gastrointestinal system has been fully assessed. Conversely, we recommend careful examination with or without biopsy of both ovaries whenever a colectomy is carried out for malignant disease. Such patients should also receive gynecologic follow-up including transvaginal ultrasound scans.

REFERENCES

1. Ayhan, A., Tuncer, Z.S., and Bukulmez, O. Malignant tumors metastatic to the ovaries. *J. Surg. Oncol.* 60:268-276, 1995.
2. Bedo, E. Primary and secondary ovarian tumors in patients with colorectal carcinoma. Thoughts on preventive oophorectomy. *Orvosi Hetilap* 137:2249-2251, 1996.
3. Fujiwara, K., Ohishi, Y., Koike, H., Sawada, S., Moriya, T., and Kohno, I. Clinical implications of metastases to the ovary. *Gynecol. Oncol.* 59:124-128, 1995.
4. Abu-Rustum, N., Barakat, R.R., and Curtin, J.P. Ovarian and uterine disease in women with colorectal cancer. *Obstet. Gynecol.* 89:85-87, 1997.
5. Perdomo, J.A., Hizuta, A., Iwagaki, H., Takasu, S., Nonaka, Y., Kimura, T., Takada, S., Moreira, L.F., Tanaka, N., and Orita, K. Ovarian metastasis in patients with colorectal carcinoma. *Acta Med. Okayama* 48:43-46, 1994.
6. Rodier, J. F., Janser, J. C., and Rodier, D. Métastases ovariennes des cancers colorectaux. *Ann. Chir.* 46:932-935, 1992.
7. Hasholzner, U., Baumgartner, L., Stieber, P., Meier, W., Hofmann, K., and Fateh-Moghadam, A. Significance of the tumour markers CA 125 II, CA 72-4, CASA and CYFRA 21-1 in ovarian carcinoma. *Anticancer Res.* 14:2743-2746, 1994.
8. Sengoku, K., Satoh, T., Saitoh, S., Abe, M., and Ishikawa, M. Evaluation of transvaginal color Doppler sonography, transvaginal sonography and CA-125 for prediction of ovarian malignancy. *Intern. J. Gynecol. Obstet.* 46:39-43, 1994.
9. Soberman, N., Leonidas, J.C., Davis, J., Cherrick, I., and Festa, R.S. Magnetic resonance imaging in the diagnosis of adolescent colorectal carcinoma. *Pediatr. Radiol.* 21:531-532, 1991.
10. Newman, J.S. and Adler, R.S. Metastatic colonic adenocarcinoma simulating primary ovarian neoplasm in transvaginal

- Doppler sonography. *J. Clin. Ultrasound* 22:121-125, 1994.
11. Shimizu, H., Yamasaki, M., Ohama, K., Nozaki, T., and Tanaka, Y. Characteristic ultrasonographic appearance of the Krukenberg tumor. *J. Clin. Ultrasound* 18:697-703, 1990.
 12. Antoniades, K., Spector, H.B., and Hecksher, R.H. Prophylactic oophorectomy in conjunction with large-bowel resection for cancer: report of two cases. *Dis. Colon Rectum* 20:506-510, 1977.
 13. Koves, I., Vamosi-Nagy, I., and Besznyak, I. Ovarian metastases of colorectal tumours. *Eur. J. Surg. Oncol.* 19:633-635, 1993.
 14. O'Brien, P.H., Newton, B.B., Metcalf, J.S., and Rittenbury, M.S. Oophorectomy in women with carcinoma of the colon and rectum. *Surg. Gynecol. Obstet.* 153:827-830, 1981.
 15. Huang, P.P., Weber, T.K., Mendoza, C., Rodriguez-Bigas, M.A., and Petrelli, N.J. Long-term survival in patients with ovarian metastases from colorectal carcinoma. *Ann. Surg. Oncol.* 5:695-698, 1998.
 16. Averette, H.E. and Nguyen, H.N. The role of prophylactic oophorectomy in cancer prevention. *Gynecol. Oncol.* 55:S38-S41, 1994.
 17. Sielezneff, I., Salle, E., Antoine, K., Thirion, X., Brunet, C., and Sastre, B. Simultaneous bilateral oophorectomy does not improve prognosis of postmenopausal women undergoing colorectal resection for cancer. *Dis. Colon Rectum* 40:1299-1302, 1997.
 18. Quan, S.H.Q. and Sendeum, K. Pelvic surgery concomitant with bowel resection for carcinoma. *Surg. Clin. North Am.* 54:881-887, 1974.
 19. Young-Fadok, T.M., Wolff, B.G., Nivatvongs, S., Metzger, P.P., and Ilstrup, D.M. Prophylactic oophorectomy in colorectal carcinoma: preliminary results of a randomized, prospective trial. *Dis. Colon Rectum* 41:277-283, 1998.
 20. Cutait, R., Lesser, M.L., and Enker, W.E. Prophylactic oophorectomy in surgery for large-bowel cancer. *Dis. Colon Rectum* 26:6-11, 1983.
 21. Taal, B.G., P.C., Delemarre, J.F. M., Bonfrère, J.M.G., and den Hartog Jager, F.C.A. Metastatic ovarian or colonic cancer: a clinical challenge. *Eur. J. Cancer* 28:394-399, 1992.