



Case report

Topiramate-induced macular neurosensory retinal detachment

Kevin Rosenberg, MD ^{a,*}, Joseph Maguire, MD ^b, Joseph Benevento, MD ^c^a Retina Vitreous Surgeons of Central New York, 3107 East Genesee Street, Syracuse, NY 13066, USA^b Wills Eye Hospital, 840 Walnut Street, Suite 1020, Philadelphia, PA 19107, USA^c Ochsner Medical Center, 1514 Jefferson Highway, New Orleans, LA 70121, USA

ARTICLE INFO

Article history:

Received 2 February 2017

Accepted 16 May 2017

Available online 19 May 2017

Keywords:

Medication toxicity

Glaucoma

Macular detachment

ABSTRACT

Purpose: To present a previously unreported retinal side-effect from topiramate use in two cases.**Observations:** Macular neurosensory retinal detachments were seen in two patients shortly after beginning oral topiramate. The macular detachments resolved shortly after discontinuing this medication.**Conclusions and importance:** As these two cases represent the first reports of topiramate-induced macular neurosensory retinal detachment, clinicians should be aware of this potential ocular side effect when administering this medication.© 2017 The Authors. Published by Elsevier Inc. This is an open access article under the CC BY-NC-ND license (<http://creativecommons.org/licenses/by-nc-nd/4.0/>).

1. Introduction

We present the first two cases of presumed topiramate-induced macular neurosensory retinal detachment with optical coherence tomography (OCT) and fluorescein angiography (FA) documentation. Topiramate is a sulfa-derivative monosaccharide with protean clinical indications including infantile seizures, migraine prophylaxis, depression, obsessive compulsive disease, and appetite suppression.¹ Its mechanisms of action include sodium channel blockade, potentiation of γ -aminobutyric acid-mediated inhibition, antagonism of a subtype of *N*-methyl-D-aspartate-activated neuronal excitation, and carbonic anhydrase inhibition.² Topiramate has well documented ocular side-effects, including acute myopia, angle closure glaucoma, ciliochoroidal effusion, and retinal striae, whose precise underlying mechanism remain unknown.

2. Findings

2.1. Case 1

A 29 year old female presented to us upon referral by her local emergency department. The patient had presented with sudden onset painless blurry vision for three days with nausea and vomiting for one day. Her past medical history included depression, anxiety, obesity, and migraine headaches. She denied past ocular

issues. Her lone medication was oral topiramate (exact dose unknown) begun one week prior to presentation.

Upon review of the transfer note, ocular examination on presentation demonstrated closed angles with intraocular pressures of 40 mmHg. She was diagnosed with angle closure glaucoma and admitted for treatment with IV mannitol and solumedrol, an enoxaparin injection, and topical phenylephrine, timolol, apraclonidine, and prednisolone acetate 1%. The topiramate was discontinued.

Although intraocular pressures decreased to 22, visual acuity worsened to hand motions in each eye over 48 h. Bilateral laser iridotomies were performed and the next day vision improved to 20/60 bilaterally with open angles to the trabecular meshwork; intraocular pressures were 10. The topical aqueous suppressants were discontinued. Routine blood work obtained at admission revealed thrombocytopenia (platelets 38,000) and anemia (hemoglobin 10.5 gm/dl, hematocrit 31.2%).

The following day, she again experienced decreased vision with visual acuities of 20/400 and 20/320 respectively, with intraocular pressures of 6 mmHg. The anterior segments were normal excepting patent peripheral iridotomies in each eye. Although the vitreous cavities were quiet, there was edema of the nasal peripapillary nerve fibers, bilateral peripheral choroidal effusions, and macular folds with subretinal fluid bilaterally. The retinal vessels were of normal caliber, but with some dot-and-blot hemorrhages in each retinal periphery (Fig. 1). Fluorescein angiography showed peripheral leakage (Fig. 1). Optical Coherence Tomography demonstrated submacular fluid (Fig. 2). Ultrasound biomicroscopy demonstrated anterior rotation of the ciliary body with choroidal

* Corresponding author. Tel.: +1 248 894 0293.

E-mail address: krosenberg@rvscny.com (K. Rosenberg).

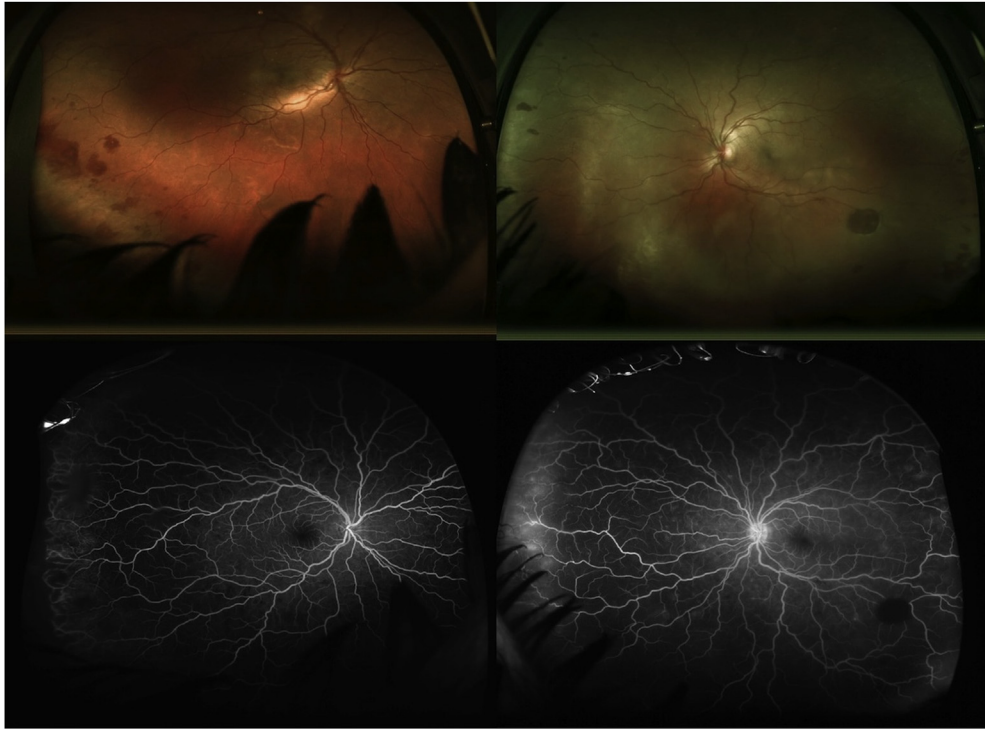


Fig. 1. Dot and blot hemorrhages seen in each retinal periphery with peripheral leakage.

effusion, but no ciliary body detachment (Fig. 3). No new intervention was initiated. The patient's platelets improved to 78,000 and the patient was discharged on topical steroids.

Three days later, vision improved to 20/70 and 20/60 respectively. The intraocular pressures were 9 and 12. The anterior chambers were deep, the macular sub-retinal fluid less (Fig. 4), and

High Definition Images: HD 5 Line Raster

OD ● ○ High Definition Images: HD 5 Line Raster

OD ○ ●

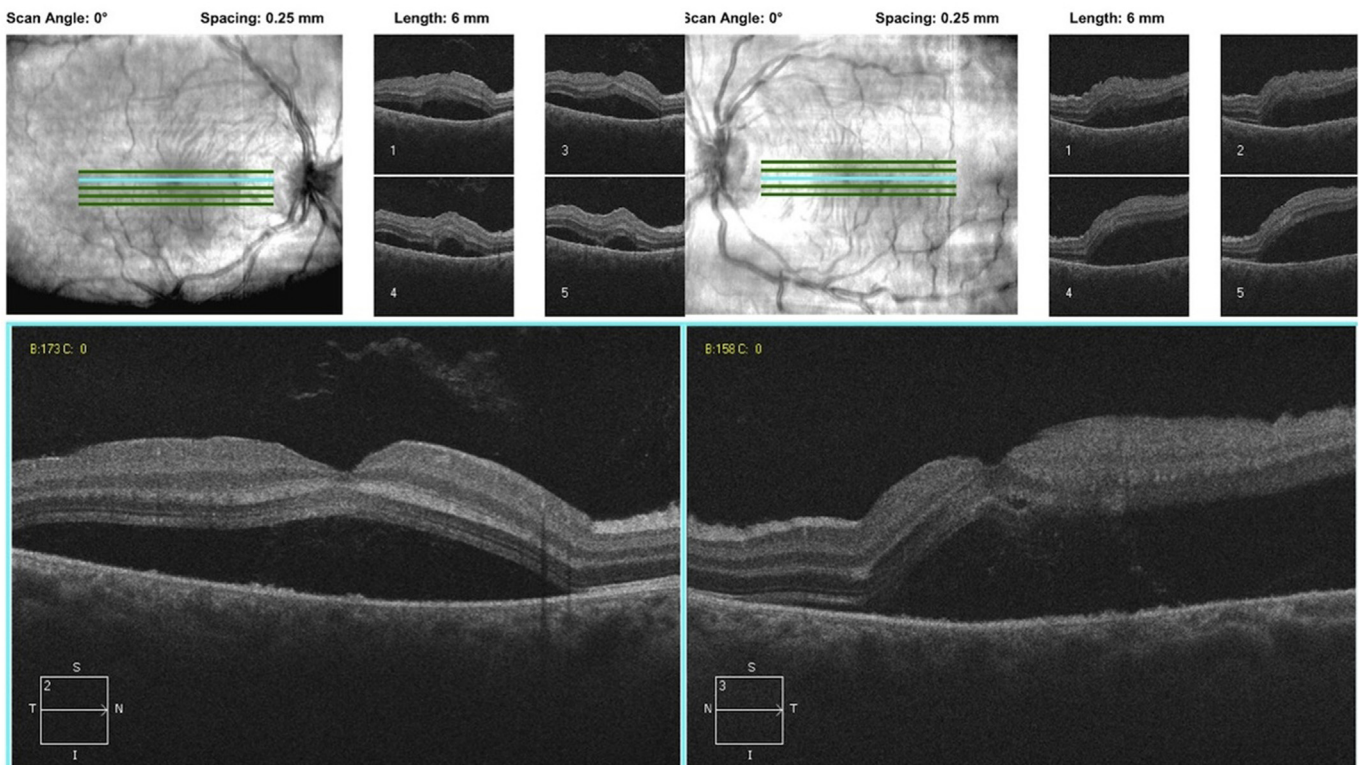


Fig. 2. Ocular Coherence Tomography demonstrates submacular fluid OU.

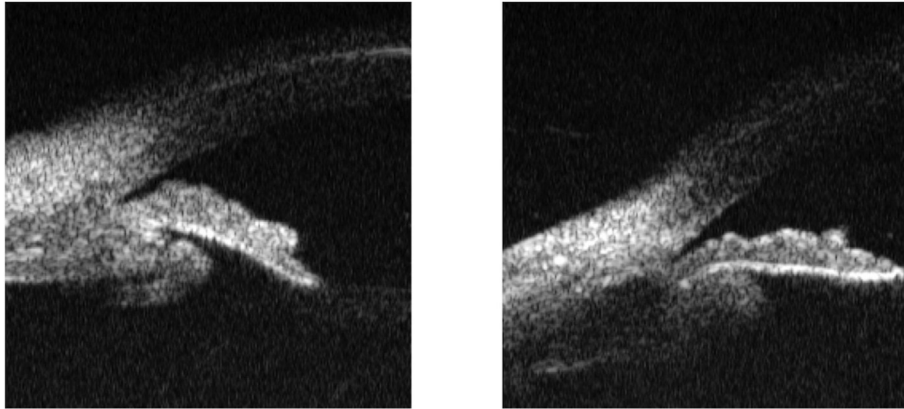


Fig. 3. Ultrasound Biomicroscopy was significant for anterior rotation of the ciliary body with choroidal effusion, but no ciliary body detachment.

the choroidal effusions decreasing in size (Fig. 5). Fluorescein angiography showed decreased peripheral pinpoint leakage (Fig. 6). The patient's platelets improved to 280,000, the hemoglobin to 12.0 gm/dl, and the hematocrit to 35.8%.

Two weeks later, the patient's vision improved to 20/40, with intraocular pressures of 14 in each eye; the anterior chambers were deep and quiet. The choroidal effusions and submacular fluid resolved and the retinal hemorrhages were clearing bilaterally (Figs. 7 and 8).

2.2. Case 2

A 38 year old Hispanic female presented with decreased vision in her left eye for 3 weeks associated with headaches, and neck stiffness. Her past medical history included migraine headaches,

hypothyroidism, hypertension, and vitiligo. There was no past ocular history. Medications included amlodipine, levothyroxine, occasional NSAIDs, and topiramate.

The visual acuities were 20/30 in the right eye and 20/100 in the left eye with intraocular pressures of 16 and 20. The anterior segments were normal, the vitreous cavities clear, and the optic nerve heads normal. The right macula was unremarkable, but the left macula had subretinal fluid (Fig. 9). Fluorescein angiography (Fig. 10) showed small areas of hyperfluorescence temporal to the macula static through recirculation frames; there was no disc hyperfluorescence. Optical coherence tomography documented a macular neurosensory detachment. (Fig. 11).

Although a presumptive diagnosis of Harada's disease was considered due to the patient's gender, age, ethnicity and vitiligo, the absence of increasing choroidal and optic nerve

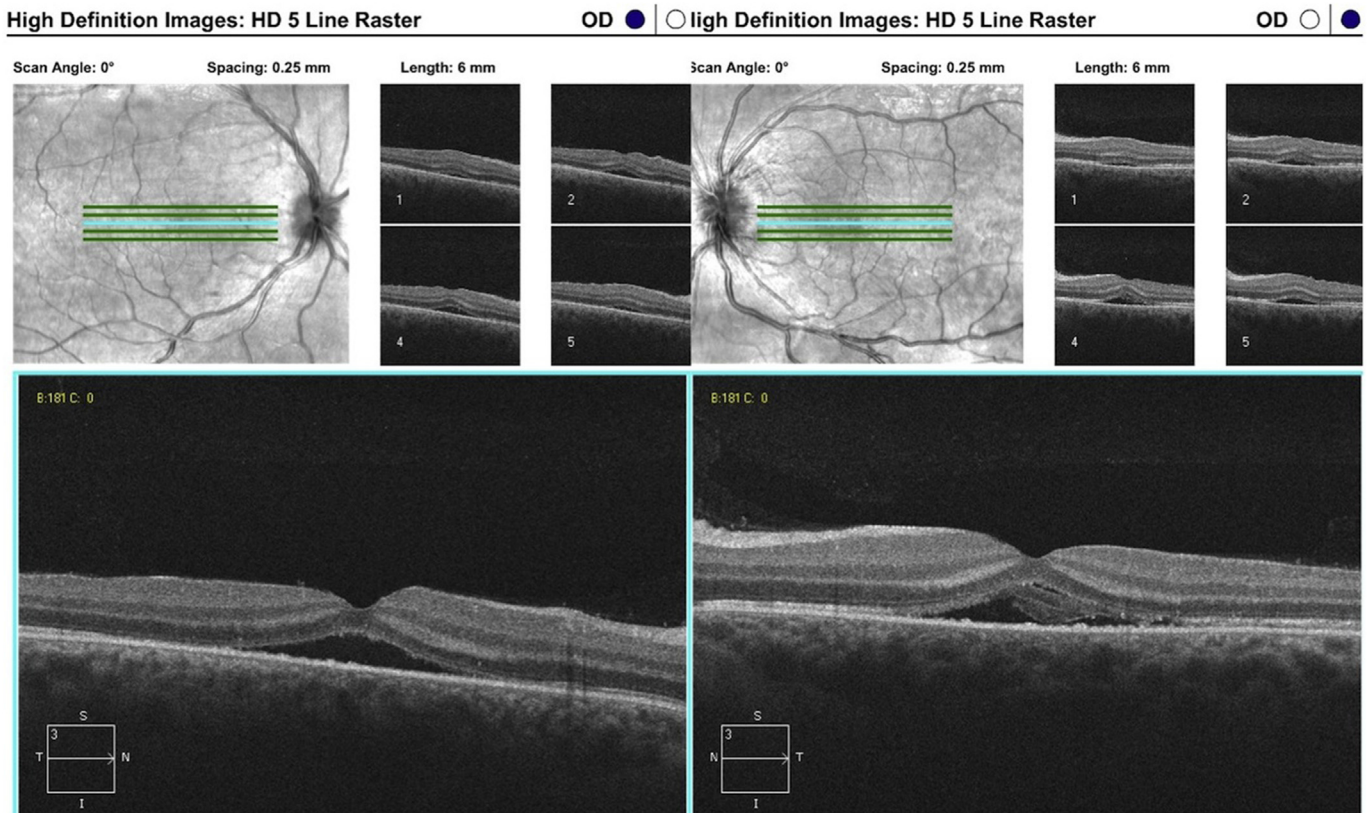


Fig. 4. Ocular Coherence Tomography shows decreased submacular fluid OU.

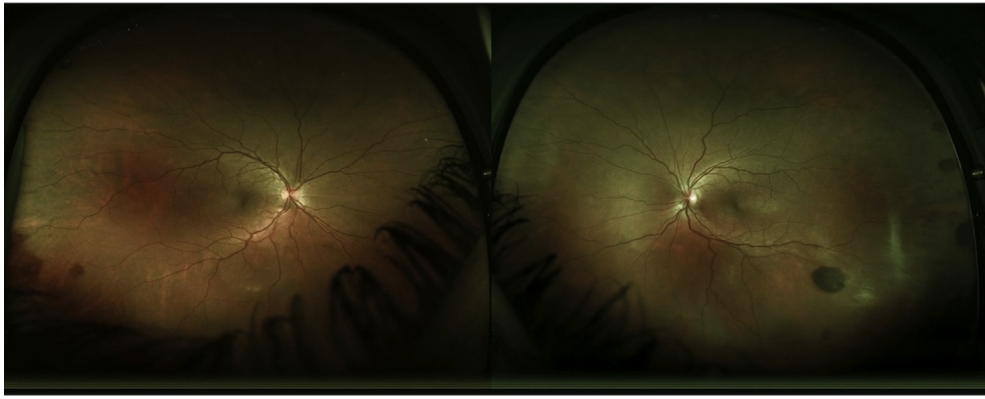


Fig. 5. Wide field fundus photographs show decreasing size of choroidal effusions OU.

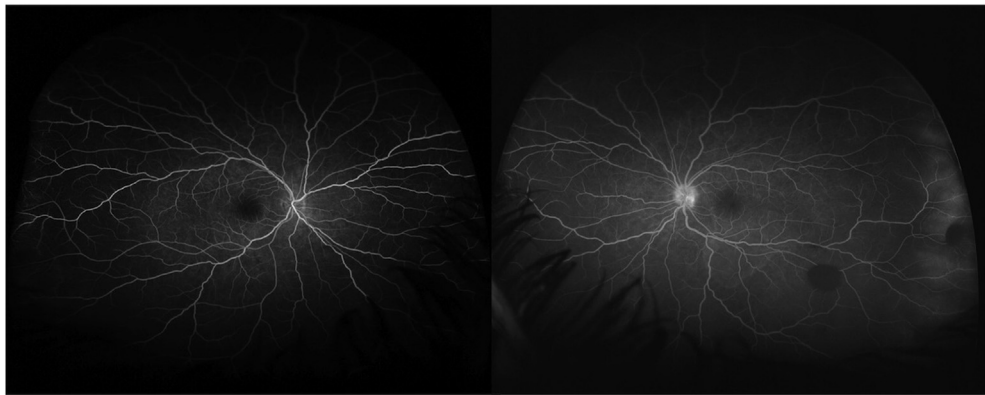


Fig. 6. Flourescein showed decreased peripheral, pinpoint leakage OU.

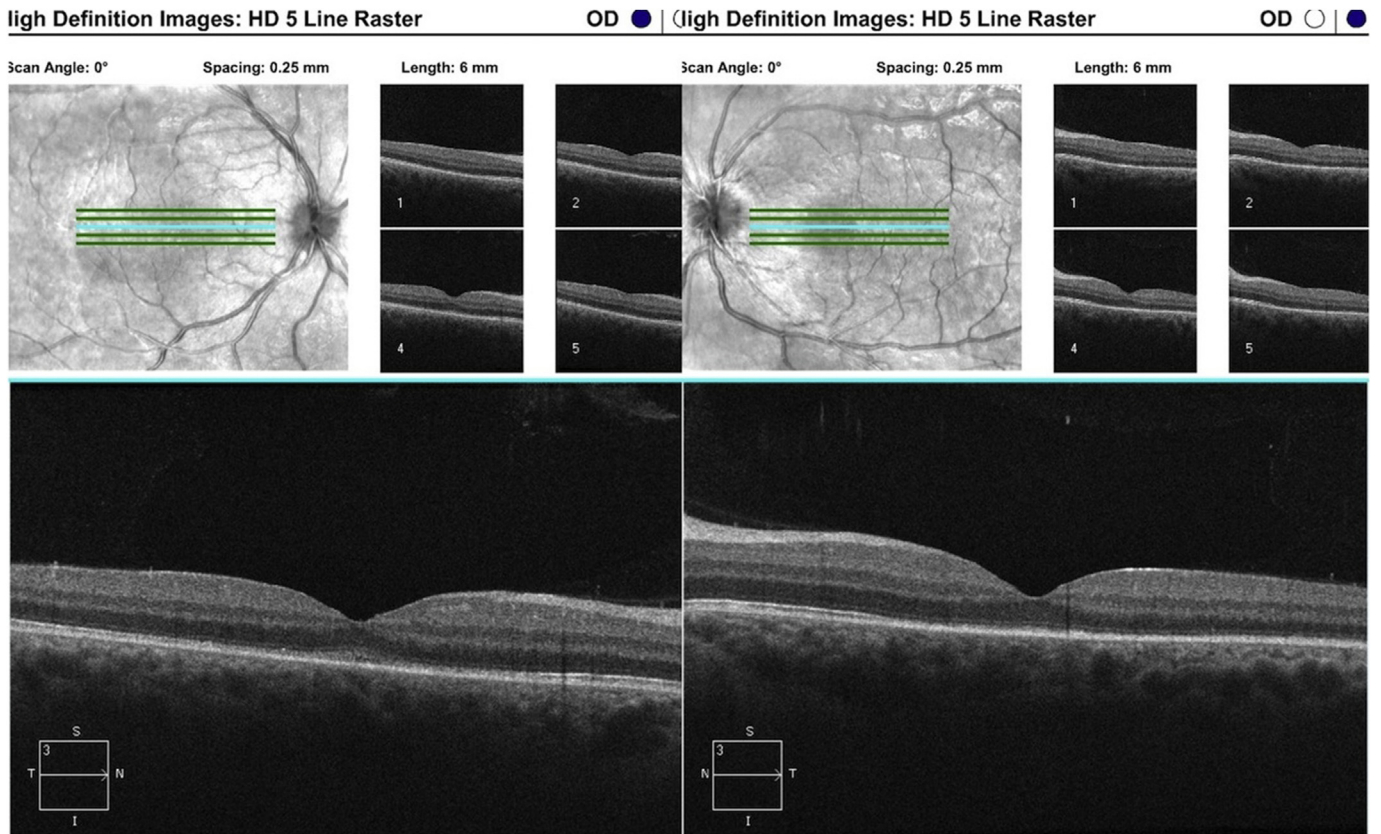


Fig. 7. The choroidal effusions had resolved and the retinal hemorrhages were clearing bilaterally.

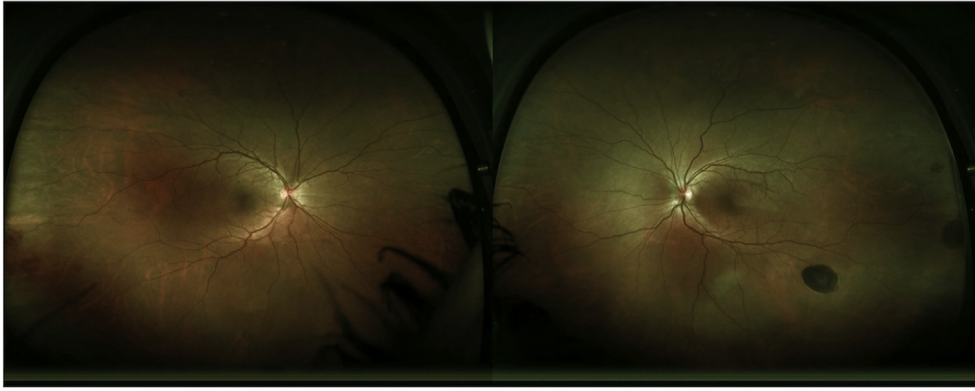


Fig. 8. Ocular Coherence Tomography shows maculas with no sub-retinal fluid in either eye, and intact, yet hazy inner segment/outer segment junctions.

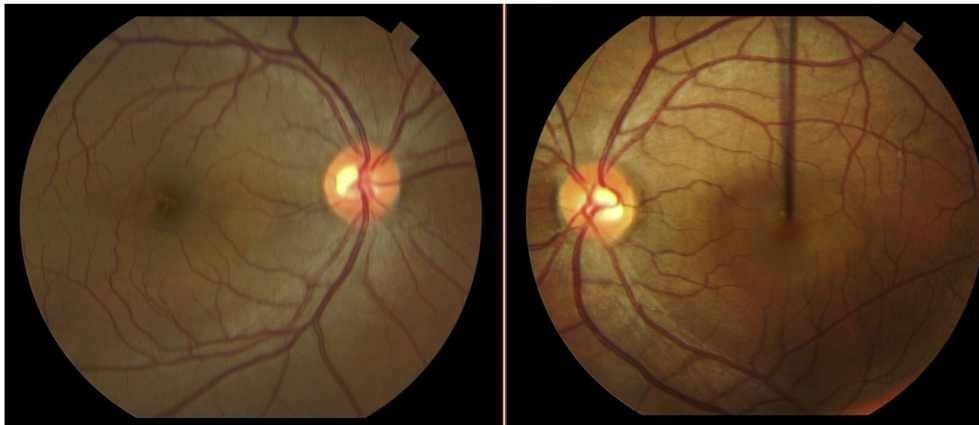


Fig. 9. Fundus photographs show normal right eye while left eye displays submacular fluid with folds.

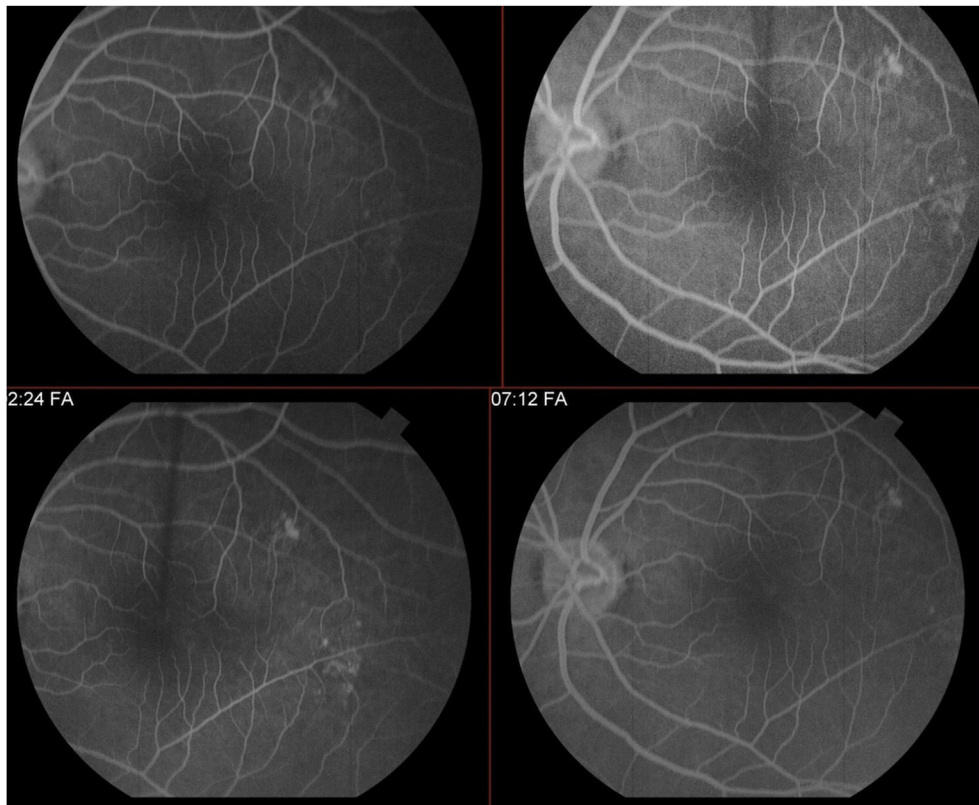


Fig. 10. Fluorescein angiography of the left eye shows small areas of hyperfluorescence temporal to the macula with some minimal increasing hyperfluorescence throughout the study.

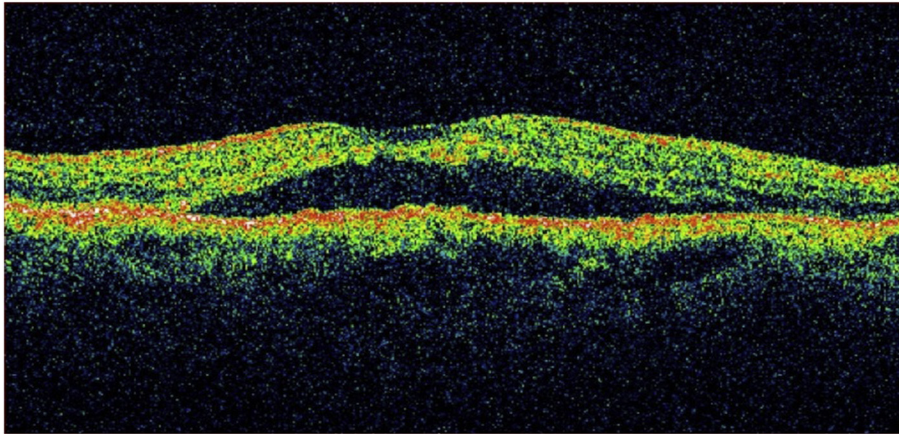


Fig. 11. Ocular Coherence Tomography confirms the macular neurosensory detachment OS.

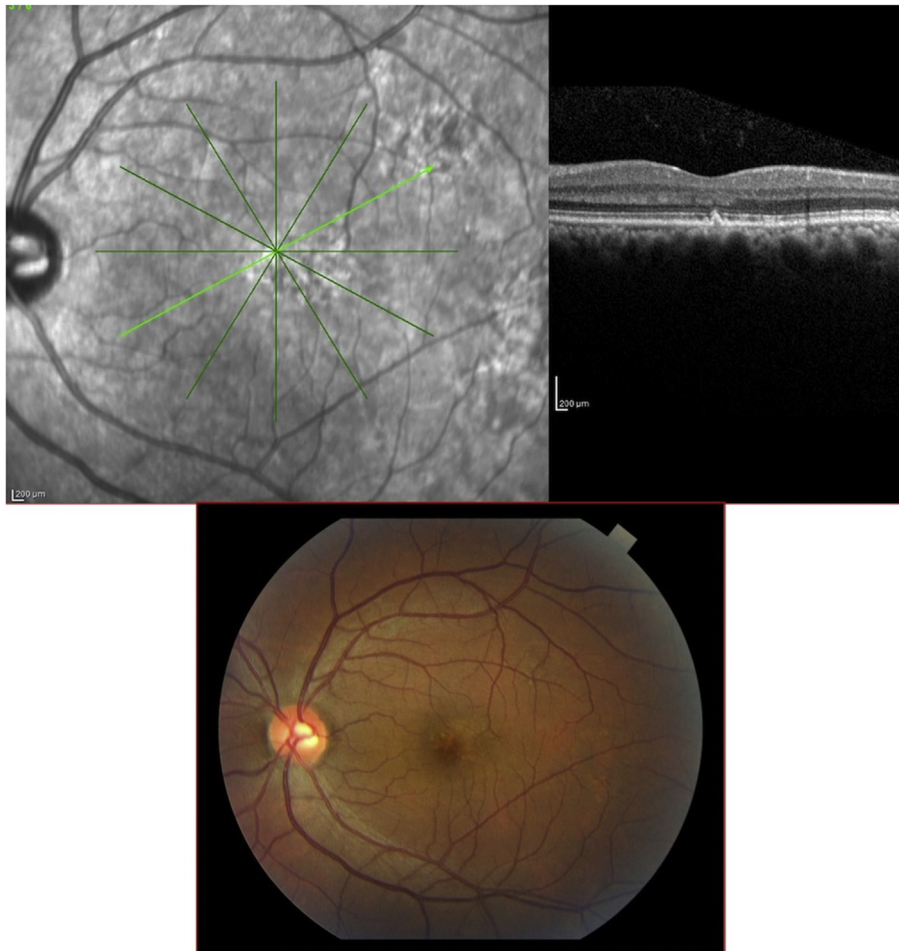


Fig. 12. Follow-up fundus photo and Ocular Coherence Tomography confirms resolution of submacular fluid OS.

hyperfluorescence with recent start of topiramate lead to discontinuation of the drug with resolution of the submacular fluid and improvement of visual acuity to 20/25 (Fig. 12).

3. Discussion

Although cases of topiramate-induced “ciliochoroidal effusion syndrome” -with uveal effusion, anterior rotation of the ciliary

body, induced myopia, and resultant acute angle closure glaucoma - have been previously reported in the literature,^{2–6} retinal side effects have been less commonly described. We present the first two cases of topiramate-associated macular neurosensory retinal detachments documented by OCT. In case 1, the retinal detachments were associated with bilateral acute angle closure glaucoma and choroidal effusion. In case 2, the retinal detachment was a unilateral solitary finding. In each case, the ocular signs and symptoms

began shortly after initial prescribing of topiramate, and resolved quickly after its cessation.

Two cases in the neurology literature report retinal detachments associated with the usage of topiramate for one year or more in two individuals.⁷ Each patient sought ophthalmic evaluation after the onset of symptoms of flashes. One patient was treated with laser retinopexy and the other with encircling scleral buckle. Although this report does not include any fundus description or documentation, the time course between the initiation of topiramate therapy and retinal detachment, the symptoms, and the choice of treatment would suggest that these are rhegmatogenous retinal detachments coincidentally found in people taking a commonly prescribed drug. The authors do not describe resolution of the retinal detachments with cessation of topiramate alone.

Our cases, on the other hand, likely share the same undefined pathophysiologic mechanism as the topiramate-induced ciliochoroidal effusion syndrome. Uveal effusions have been reported with various sulfa-derived drugs including acetazolamide, indapamide, chlorothiazide, and antibacterial sulfa derivatives². It has been postulated that topiramate's carbonic anhydrase antagonist property is responsible for choroidal detachments.⁸ Impedance of normal fluid movement in the retinal pigment epithelium and choroid could be an effect of drug-related membrane potential changes.⁵ Inflammation has also been cited as a potential etiology.⁹ Whatever the underlying mechanism, the same process may alter the fluid balance in the subretinal space by affecting the efficiency of the retinal pigment epithelial pump, the integrity of the blood-retinal barrier, or both.

Intraretinal hemorrhages, as found in Case 1, have not been reported with ocular topiramate toxicity. We believe that these findings were associated with the coincidental transient thrombocytopenia and anemia this patient experienced. These abnormal blood counts could have been secondary to the enoxaparin injection the patient received at her local hospital, associated with a mild Heparin-Induced Thrombocytopenia (HIT), or could be secondary to a topiramate-associated aplastic event. Thrombotic Thrombocytopenic Purpura (TTP) is unlikely based on a lack of thrombotic events and systemic symptoms, and Idiopathic Thrombocytopenic Purpura (ITP) is unlikely based on a lack of systemic signs.

The timing of the patient's decreased platelet levels, coupled with the lack of targeted thrombocytopenic therapy (except 1 dose of IV solumedrol prior to our observation) and its prompt resolution with discontinuation of topiramate most likely implicates topiramate as the inciting factor.

In both cases, following discontinuation of topiramate, the patients' clinical examinations improved, and vision returned to normal, implicating topiramate as the causal agent.

4. Conclusion

Herein, we present the first two cases of topiramate-induced macular neurosensory retinal detachment. Clinicians should be aware of this potential ocular side effect when administering this medication.

Patient consent

Consent to publish this case series of 2 cases was not obtained. This report does not contain any personal information that could lead to the identification of the patient.

Funding

No funding or grant support.

Authorship

All authors attest that they meet the current ICMJE criteria for Authorship.

Conflict of interest

The following authors have no financial disclosures: KR, JB, JM.

Acknowledgements

None.

References

1. Abtahi MA, Abtahi SH, Fazel F, et al. Topiramate and the vision: a systematic review. *Clin Ophthalmol*. 2012;6:117–131.
2. Medeiros FA, Ahang XY, Bernd AS, Weinreb RN. Angle-closure glaucoma associated with ciliary body detachment in patients using topiramate. *Arch Ophthalmol*. 2003;121(2):282–285.
3. Sankar PS, Pasquale LR, Grosskreutz CL. Uveal effusion and secondary angle-closure glaucoma associated with topiramate use. *Arch Ophthalmol*. 2001;119(8):1210–1211.
4. Rhee DJ, Goldberg MJ, Parrish RK. Bilateral angle-closure glaucoma and ciliary body swelling from topiramate. *Arch Ophthalmol*. 2001;119(11):1721–1723.
5. Sen HA, O'Halloran HS, Lee W, Ky L. Topiramate-induced acute myopia and retinal striae. *Arch Ophthalmol*. 2001;119(5):775–777.
6. Banta JT, Hoffman K, Budenz DL, et al. Presumed topiramate-induced bilateral acute angle-closure glaucoma. *Am J Ophthalmol*. 2001;132(1):112–114.
7. Dey KK, Das S, Mishra A, Guha G. Retinal detachment presumably associated with topiramate. *Neurol India*. 2008;56(2):204–205.
8. Dehghani A, Abtahi M-A, Abtahi S-H, et al. Massive bilateral choroidal detachment induced by administration of topiramate. *Case Rep Ophthalmol*. 2011;2(2):251–255.
9. Rhee DJ, Ramos-Esteban JC, Nipper KS. Rapid resolution of topiramate-induced angle-closure glaucoma with methylprednisolone and mannitol. *Am J Ophthalmol*. 2006;141(6):1133–1134.