

# Median facial dysplasia: A rare craniofacial syndrome and the surgical management of associated cleft lip

Department of Oral and Maxillofacial Surgery, <sup>2</sup>Department of Oral and Maxillofacial Prosthodontics, Maulana Azad Institute of Dental Sciences, New Delhi, <sup>3</sup>Department of Oral and Maxillofacial Surgery, Chartapati Sahuji Maharaj Dental College and Hospital, Lucknow, Uttar Pradesh, India

Rakesh Sharma, Sriram Krishnan, U. S. Pal<sup>1</sup>, Mahesh Verma<sup>2</sup>

## ABSTRACT

Median facial dysplasia (MFD) is a distinct and unique disorder of the craniofacial region that is characteristic of deficient mid facial structures with the addition of a unilateral or bilateral cleft lip with or without a cleft palate. A cleft lip which is associated with MFD whether it is unilateral or bilateral does not represent a typical cleft lip and poses some challenges in reconstruction. The management of such cleft lip has been rarely discussed in previous literatures; the main obstacle comes in identifying the anatomical landmarks to establish an esthetic reconstruction of the lip. However, reasonably good result can be achieved when the adjacent and distant anatomical structures are correlated to aid the reconstruction.

### Address for correspondence:

Dr. Sriram Krishnan,  
77, Pocket E, Mayur Vihar  
Phase 2, Delhi - 110 091, India.  
E-mail: Krishnan.sriram1982@gmail.com

**Key words:** Chelioplasty, cleft lip, craniofacial syndrome, median facial dysplasia

## INTRODUCTION

The face being the representation of an individual, any defects associated with it is amplified to affect the individual suffering in various aspects of life. In the various spectrums of defects affecting the maxillofacial region congenital defects are a group of disorders that affect the individual since birth and the afflicted person struggles with its sequel and its treatment phases almost all throughout their life.

Cleft lip and palate patients are such individuals who spend almost their entire childhood and a significant portion of their early adulthood in obtaining and undergoing treatment for their condition. These patients undergo a significant amount of physical and psychological difficulties during the course of their treatment.

A sub group of these cleft lip and palate patients is the median facial dysplasia (MFD), it has an incidence rate of 2% which was first described by Noordhoff and Cheng,<sup>[1]</sup> this incidence rate was stated by them in their extensive study, they also described this subgroup in detail as having a summation of characteristic craniofacial defects which include a short prolabium, absent cupid's bow, absent labial frenum, hypoplastic premaxilla, absent maxillary central and lateral incisor on cleft side, deficient septal cartilage, and nasal spine. A unique feature is the absence of any gross brain abnormalities, which is the distinguishing feature of this condition from holoprosencephaly sequence.

## CASE REPORT

A 9-month-old female baby presented with a false median cleft with hypotelorism, on further examination she had median cleft lip with rudimentary prolabium, poorly defined cupid's bow, lack of upper labial frenum, flattened nose with widened nostrils and deficient collumella. The pre-maxilla seemed to be rudimentary in this patient, hence a lack of anterior alveolus was seen, but with no evidence of a cleft palate or alveolus. The dental occlusion of the patient could not be assessed as the teeth had not erupted.

Access this article online	
<b>Quick Response Code:</b> 	<b>Website:</b> www.njms.in
	<b>DOI:</b> 10.4103/0975-5950.117877

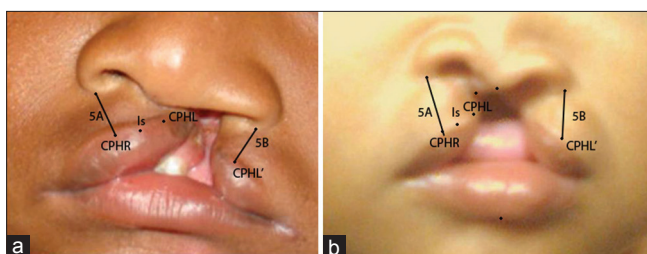
The patients' history revealed that she was a full-term normal delivery, with no known complications during pregnancy and no significant history of teratogenic exposure or familial history of cleft was present. The patient seemed to be of a normal intellect judging by the child's understanding and orientation of surroundings and had her normal milestones achieved with respect to the age. The diagnosis was made in the presence of the typical findings of deficient mid facial structures and absence of any clinically appreciable gross brain abnormalities.

The most important factor in reconstruction of the cleft lip in cases of MFD is the identification of the surgical reference points of chelioplasty [Figure 1a] which is a cumbersome process as the columella is deformed or poorly defined, hence the aid of adjacent midline structures such as the midpoint of nasal columella can be used as a guide to locate IS (Cupid bow summit point, Point 1), similarly the CPHR (Cleft Philtrum Horizontal Right, Point 2) is traced towards the non-cleft side, an equidistant point is marked as CPHL (Cleft Philtrum Horizontal Left, Point 3) on the cleft side based on the measurement between IS and CPHR. The CPHL' (Point 3') is marked based on the maximum thickness of the vermilion and verified by transferring the measurements of CHR (Cleft Horizontal Right point) -CPHR to CHL (Cleft Horizontal Left point) -CPHL' [Figure 1b]. The measurements of 5A and 5B are also noted for quantifying the shortening of the cleft side lip.

The incision using the reference points, C flap is developed till the midline of columella, and a back cut is given hence in that process developing a thick columella by dropping down a thick C flap, this provides the deformed or a poorly developed columella a structure. The reference points are further used as guide for dissection of the muscles and reorientation with its counterpart on the non-cleft side [Figure 2a and b].

## DISCUSSION

The middle third of the face is the most complex skeletally, composed partly of the skull base and



**Figure 1:** (a) Normal chelioplasty markings, (b) Markings for chelioplasty of median facial dysplasia

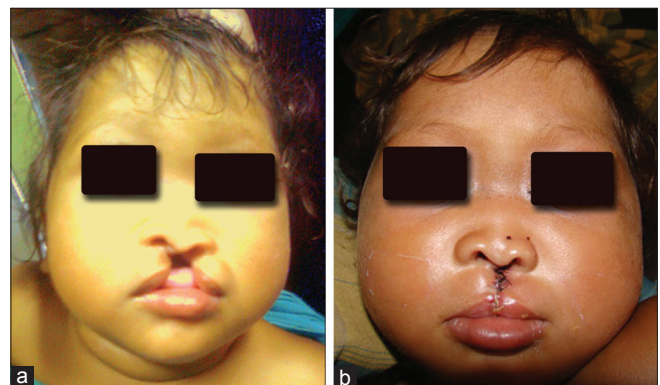incorporating both the nasal extension of the upper third and part of the masticator apparatus.<sup>[2]</sup>

MFD embryologically occurs due to defects in the development of the median portion of anterior neural plate. In the 3<sup>rd</sup> week of gestation, the primitive tissues of trilaminar embryo give rise to the notochord and pre-cordal mesoderm. At the same time rostral ectoderm, differentiate to form highly specialized neural crest cells. These tissues are responsible for the ultimate development of the brain and midline facial structures.<sup>[3]</sup> Pre-cordal mesoderm has a dual role, its first role is in formation of the median skeleton of face and second role is in induction and differentiation of rostral neural ectoderm and thereby prosencephalic development. Therefore, whenever pre-chordal mesoderm is defective mid facial and prosencephalic development may be arrested at any stage,<sup>[4]</sup> a developmental error at this phase results in holoprosencephaly and mid facial defects.

The etiology of MFD has not been identified, which is the case with any rare disorder a hypothesis has been suggested which could be mechanical, genetic or environmental teratogens that can cause defects in pre-chordal neural crest cells which can arrest development of midline structures and prevent organogenetic cleavages of the prosencephalon. These defects could be caused due to intrinsic or extrinsic factors.<sup>[5]</sup>

The diagnosis of MFD is established when a patient presents with mid facial deficiencies in a unilateral or a bilateral cleft lip with or without accompanying cleft palate, and without any clinically discernable cerebral anomalies. These patients should also be distinguished from individuals suffering from mid facial hypoplasia. These patients of MFD have a normal intelligence level but have poor potential for midface growth.

Noordhoff and Cheng initially coined the term median facial dysgenesis, this term was later changed



**Figure 2:** (a) Pre-operative left unilateral Median facial dysplasia cleft lip, (b) Post-operative view

to MFD because dysplasia means developmental malformation while dysgenesis suggests abnormal morphogenesis.<sup>[6]</sup> Van der Meulen classified these malformations based on embryology and the region involved, he also recommended that the term dysgenesis should be changed to dysplasia and the terms median and cerebro-facial were appropriate for regional orientation.<sup>[7]</sup>

Noordhoff and Cheng in their landmark series of more than 2900 patients of cleft lip and palate over a period of 14 years in the Taiwanese population had identified 59 patients with varying degree of MFD, following which the same population group were evaluated for maxillary growth pattern by Liao *et al.*<sup>[8]</sup> Amongst the various Indian literatures on cleft lip and palate only a single case report by Aggarwal identified a total of three cases of MFD, but with no further information on the management of the associated cleft lip/palate or other related facial defect in the report.<sup>[9]</sup>

The identification of this sub group of cleft lip and palate is important as they pose a problem in reconstruction; the role of the cheiloplasty procedure is very important and has to be performed with meticulous accuracy to properly approximate the sparse mid facial soft tissue structures.

## REFERENCES

1. Noordhoff MS, Cheng WS. Median facial dysgenesis in cleft lip and palate. *Ann Plast Surg* 1982;8:83-92.
2. Sperber GH. Early orofacial development. *Craniofacial Development*. Hamilton London: BC Decker Inc.; 2001. p. 31-49.
3. Elias DL, Kawamoto HK Jr, Wilson LF. Holoprosencephaly and midline facial anomalies: Redefining classification and management. *Plast Reconstr Surg* 1992;90:951-8.
4. Gruss JS, Matthews DN. Median cerebrofacial dysgenesis: The syndrome of median facial defects with hypotelorism. *Cleft Palate J* 1978;15:275-81.
5. Johnson MC, Bronsky PT, Millicovsky G. Embryogenesis of cleft lip and palate. In: McCarthy JG, editor. *Plastic Surgery*. Vol. 4. Philadelphia: Saunders; 1990. p. 2515.
6. Noordhoff MS, Huang CS, Lo LJ. Median facial dysplasia in unilateral and bilateral cleft lip and palate: A subgroup of median cerebrofacial malformations. *Plast Reconstr Surg* 1993;91:996-1005.
7. Van der Meulen JC, Mazzola R, Vermey-Keers C, Stricker M, Raphael B. A morphogenetic classification of craniofacial malformations. *Plast Reconstr Surg* 1983;71:560-72.
8. Liao YF, Numhom S, Lo LJ, Noordhoff MS. Craniofacial and dental dysmorphology in patients with median facial dysplasia: Long-term follow-up. *Int J Oral Maxillofac Surg* 2011;40:672-8.
9. Aggarwal P. Median facial dysplasia: A review. *Indian J Plastic Surg* 2003;36:126-30.

**How to cite this article:** Sharma R, Krishnan S, Pal US, Verma M. Median facial dysplasia: A rare craniofacial syndrome and the surgical management of associated cleft lip. *Natl J Maxillofac Surg* 2013;4:84-6.

**Source of Support:** Nil. **Conflict of Interest:** None declared.