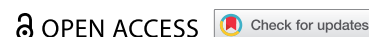

CASE REPORT



Non-Hodgkin lymphoma of the thyroid in a patient with hyperthyroidism

Theresa Lanham ^a, Erik Lanham^b, Abigail Sullivan ^c and Vasudev Magaji^c

^aCooper University Hospital, Camden, USA; Department of Endocrinology; ^bJefferson Health, Stratford, USA; Department of General Surgery; ^cReading Hospital, Reading, USA; Department of Internal Medicine

ABSTRACT

Primary thyroid lymphoma is incredibly rare with an annual incidence of approximately 2.1 per million persons, accounting for 2% of thyroid malignancies. One of the only known risk factors is autoimmune thyroid disease, specifically Hashimoto's, although there have been a few cases of thyroid lymphoma associated with Graves' disease.

Here, we present one such case of a patient with pre-existing hyperthyroidism who developed non-Hodgkin's lymphoma of the thyroid. The patient initially presented with rapidly progressing right-sided neck swelling. He was clinically and biochemically euthyroid with negative thyroid stimulating immunoglobulin, maintained on methimazole. Biopsy of the thyroid nodule with flow cytometry revealed non-Hodgkin lymphoma. Intervention included radiation therapy.

ARTICLE HISTORY

Received 31 May 2020
Accepted 22 September 2020

KEYWORDS

Hyperthyroidism; primary thyroid lymphoma; non-Hodgkin

1. Introduction

Primary thyroid lymphoma is incredibly rare with an annual incidence of approximately 2.1 per million persons [1], accounting for 2% of thyroid malignancies [2]. When it does occur, it is far more often non-Hodgkin type with one study reporting only 16 cases of Hodgkin lymphoma of the thyroid over a 43-year period [3]. Thyroid lymphoma has a strong female predominance and typically occurs between the ages of 65–75 years old [1]. One of the only reported risk factors includes autoimmune thyroid disease, specifically Hashimoto's [1,4] although per our literature review there have been a few cases of thyroid lymphoma associated with Graves' disease [5,6]. Here, we present one such case of a patient with pre-existing hyperthyroidism who developed non-Hodgkin lymphoma of the thyroid.

2. Case presentation


A 61-year-old male with longstanding, ten-year history of hyperthyroidism presented with two months of right-sided neck swelling. The patient had been taking methimazole 10 mg daily with previous unsuccessful attempts to taper. He was clinically and biochemically euthyroid with negative thyroid stimulating immunoglobulin. He denied any B-type symptoms, including fever, weight loss, or night sweats. Computer tomography (CT) neck revealed an enlarged homogeneously enhancing nodule under the right sternocleidomastoid concerning for pathologic lymph node, as well as a smaller satellite node. CT did not note any thyroid nodules. Biopsy of the lymph node showed low-grade B cell lymphoma consistent with

marginal zone lymphoma and involvement of the bone marrow. Positron emission tomography (PET) scan demonstrated diffuse asymmetric thyroid activity prominent in the isthmus to the right of midline (Figure 1), thought to possibly represent Hashimoto's thyroiditis. Subsequent thyroid ultrasound showed a heterogeneously enlarged thyroid with a 4 cm hypoechoic nodule within the lower pole of the right thyroid, as well as an 11 mm hyperechoic nodule in the lower left pole (Figure 2). Given the size and dark hypoechoic appearance of the thyroid nodule in the setting of known lymphoma, fine needle aspiration biopsy and flow cytometry of the right thyroid nodule was obtained (Figure 3). This revealed non-Hodgkin lymphoma of the thyroid. The patient was diagnosed with marginal zone lymphoma of thyroid and right cervical nodes, stage IIE and underwent radiation therapy. Given the negative TSI, the patient was tapered off of methimazole despite previous unsuccessful attempts. Thyroid function tests are being closely monitored.

3. Discussion

Primary thyroid lymphoma is incredibly rare with an annual incidence of approximately 2.1 per million persons, accounting for 2% of thyroid malignancies. It is primarily B-cell lineage with a majority being marginal zone type [1]. As noted above, the only known risk factor for primary thyroid lymphoma includes autoimmune thyroid disease. When it does occur, it is frequently in the setting of hypothyroidism, specifically Hashimoto's, more so than hyperthyroidism. Despite the well-established relationship between primary thyroid

CONTACT Theresa Lanham  T.lanham1228@gmail.com  Cooper University Hospital, Camden, USA

 Supplemental data for this article can be accessed [here](#).

© 2020 The Author(s). Published by Informa UK Limited, trading as Taylor & Francis Group on behalf of Greater Baltimore Medical Center.

This is an Open Access article distributed under the terms of the Creative Commons Attribution-NonCommercial License (<http://creativecommons.org/licenses/by-nc/4.0/>), which permits unrestricted non-commercial use, distribution, and reproduction in any medium, provided the original work is properly cited.

lymphoma and hypothyroidism, there are very few cases of hyperthyroidism and thyroid lymphoma reported [1,4–7]. Lymphoid tissue isn't native to the thyroid gland but it is theorized that chronic exposure to antigens, such as in Hashimoto's, causes lymphoid tissue to migrate to the thyroid which may explain why the disease is highly associated [8]. Similar physiology may occur with antigens in Graves' disease, although our patient had negative antibodies.

The classic thyroid lymphoma patient may present with an enlarging goiter, dysphagia, hoarseness, neck pain, and occasionally systemic symptoms such as fever, night sweats, weight loss [1,9]. These patients may have signs of either hypothyroidism or, less commonly, hyperthyroidism [5,6].

Fine needle aspiration cytology alone is not sufficient to diagnose thyroid lymphoma, given the common co-occurrence of Hashimoto's thyroiditis which can appear very similar histologically. Definitive diagnosis includes biopsy with flow cytometry [10–12]. As such, clinicians may not easily recognize the importance of certain clinical testing, such as flow cytometry.

Disease is mostly often limited to the thyroid (~50%) or the thyroid and local lymph nodes (~45%), although there is rarely distant metastasis making staging evaluation of the utmost importance [1,13,14]. Diagnosis is critical, because treatment does not include a thyroidectomy for primary thyroid lymphoma [13–15]. Treatment depends upon staging, but typically includes radiation, chemotherapy, or a combination of the two [10,11,13–15]. Prognosis for stage I or II disease is usually excellent with one study citing a five-year survival rate of 73% [16] and another with 91% [17], both on patients treated with combined therapy.

Based on our case, we would like to highlight the importance of considering the association between primary thyroid lymphoma and hyperthyroidism, instead of the more common seen association with hypothyroidism. We would also like to stress obtaining flow cytometry based upon clinical context and imaging characteristics of the thyroid nodule since diagnosis would greatly alter treatment plan.



Acknowledgments

Special acknowledgment to Dr. Mark Mentrikoski, MD. Reading Hospital, Department of Pathology for his assistance with histologic findings and imaging. An earlier version of this work was presented at the "88th Annual Meeting of the American Thyroid Association," Washington D.C., 2018. The authors declare that there is no conflict of interest regarding the publication of this article. There was no funding for this publication.

Disclosure statement

No potential conflict of interest was reported by the authors.

ORCID

Theresa Lanham  <http://orcid.org/0000-0002-7725-3634>
Abigail Sullivan  <http://orcid.org/0000-0002-0876-8132>

References

- [1] Pedersen R, Pedersen N. Primary non-Hodgkin's lymphoma of the thyroid gland: a population-based study. *Histopathology*. 1996 Jan;28(1):25–32.
- [2] Freeman C, Berg JW, Cutler SJ. Occurrence and prognosis of extranodal lymphomas. *Cancer*. 1972;29:252.
- [3] Wang SA, Rahemtullah A, Faquin WC, et al. Hodgkin's lymphoma of the thyroid: a clinicopathologic study of five cases and review of the literature. *Mod Pathol*. 2005;18:1577.
- [4] Hyjek E, Isaacson PG. Primary B cell lymphoma of the thyroid and its relationship to Hashimoto's thyroiditis. *Hum Pathol*. 1988;19:1315.
- [5] Zeki K, Eto S, Fujihira T, et al. Primary malignant lymphoma of the thyroid in a patient with long-standing Graves' disease. *Endocrinol Jpn*. 1985;32:435.
- [6] Jennings AS, Saberi M. Thyroid lymphoma in a patient with hyperthyroidism. *Am J Med*. 1984;76:551.
- [7] Noureldine S, Tufano R. Association of Hashimoto's thyroiditis and thyroid cancer. *Curr Opin Oncol*. 2015 Jan;27(1):21–25.
- [8] Doi Y, Goto A, Murakami T, et al. Primary thyroid lymphoma associated with graves' disease. *Thyroid*. 2004;14(9):772–776.
- [9] Skarsgard ED, Connors JM, Robins RE. A current analysis of primary lymphoma of the thyroid. *Arch Surg*. 1991;126:1199.
- [10] Sarinah B, Hisham AN. Primary lymphoma of the thyroid: diagnostic and therapeutic considerations. *Asian J Surg*. 2010;33:20–24.
- [11] Matsuzuka F, Miyauchi A, Katayama S. Clinical aspects of primary thyroid lymphoma: diagnosis and treatment based on our experience of 119 cases. *Thyroid*. 1993;3:93–99.
- [12] Cha C, Chen H, Westra WH, et al. Primary thyroid lymphoma: can the diagnosis be made solely by fine needle aspiration? *Ann Surg Oncol*. 2002;9:298–302.
- [13] Tsang RW, Gospodarowicz MK, Sutcliffe SB, et al. Non-Hodgkin's lymphoma of the thyroid gland: prognostic factors and treatment outcome. The Princess Margaret Hospital Lymphoma Group. *Int J Radiat Oncol Biol Phys*. 1993;27:599.
- [14] Tupchong L, Hughes F, Harmer CL. Primary lymphoma of the thyroid: clinical features, prognostic factors, and results of treatment. *Int J Radiat Oncol Biol Phys*. 1986;12:1813.
- [15] Junor EJ, Paul J, Reed NS. Primary non-Hodgkin's lymphoma of the thyroid. *Eur J Surg Oncol*. 1992;18:313.
- [16] Watanabe N, Noh JY, Narimatsu H, et al. Clinicopathological features of 171 cases of primary thyroid lymphoma: a long-term study involving 24553 patients with Hashimoto's disease. *Br J Haematol*. 2011;153:236.
- [17] Ha CS, Shadle KM, Medeiros LJ, et al. Localized non-Hodgkin lymphoma involving the thyroid gland. *Cancer*. 2001;91:629.