

Technical Note

Conversion technique from neuroendoscopy to microsurgery in ventricular tumors: Technical note

Pedro Henrique da C. F. Pinto¹, Flavio Nigri^{1,3}, Gabriel N. Gobbi¹, Egas M. Caparelli-Daquer^{2,3}

¹Department of Surgical Specialties, Neurosurgery Teaching and Assistance Unit, Pedro Ernesto University Hospital, Rio de Janeiro State University, ³Nervous System Electric Stimulation Laboratory (LabEEL) - Neurosurgery Teaching and Assistance Unit, Pedro Ernesto University Hospital, Rio de Janeiro State University, ²Department of Physiological Sciences, Roberto Alcântara Gomes Biology Institute, Rio de Janeiro State University, Rio de Janeiro, RJ, Brazil

E-mail: *Pedro H. da Costa F. Pinto - pedrohcfp@gmail.com; Flavio Nigri - flavionigri@gmail.com; Gabriel N. Gobbi - gabrielgobbi@hotmail.com; E. Moniz Caparelli-Daquer - egas.caparelli@gmail.com

*Corresponding author

Received: 18 April 16 Accepted: 26 April 16 Published: 11 November 16

Abstract

Background: Ventricular tumors represent a major neurosurgical challenge, making endoscopic approach an invaluable tool as it gained importance due to technological advances. Nevertheless, the method is not exempt of risk and limitations, sometimes requiring an open surgery. Thus, initial measurements must be adopted in order to simplify an eventual need for conversion to open craniotomy.

Methods: Here, we describe a series of 6 patients with ventricular tumors approached by neuroendoscopy where the conversion to microsurgery turned out to be necessary. Patients' average age was 59.5 years (39–75 years). Average tumoral size was 17.8 mm (15–21 mm). There were 2 cases of lateral ventricle subependymoma and 4 cases of third ventricle colloid cysts. A standard surgical incision was performed in the coronal direction, allowing lateral expansion to 10 cm. Moreover, the endoscopic burr hole was enlarged to a 5 cm craniotomy. A small enlargement of the endoscopic cortical access was performed to gain a transcortical microsurgical corridor to the ventricular cavity. The need for conversion arose due to high consistency of the tumor (3 cases), technical problems (2 cases), and cortical collapse (1 case).

Results: There was one case of cerebrospinal fluid fistula and infection and one case of transitory memory disturbance. In both the cases, we obtained a complete functional recovery. Clinical and radiological follow-up showed total tumor removal with no recurrences.

Conclusions: The technique herein described was easy to perform, promptly bypassed the endoscopic limitations, and gathered excellent surgical results. The possibility of adapting the method to other tumor locations may be considered.

Key Words: Conversion technique, microsurgery, neuroendoscopy, open craniotomy, ventricular tumors

Access this article online

Website:www.surgicalneurologyint.com**DOI:**

10.4103/2152-7806.193926

Quick Response Code:

This is an open access article distributed under the terms of the Creative Commons Attribution-NonCommercial-ShareAlike 3.0 License, which allows others to remix, tweak, and build upon the work non-commercially, as long as the author is credited and the new creations are licensed under the identical terms.

For reprints contact: reprints@medknow.com

How to cite this article: da C. F. Pinto PH, Nigri F, Gobbi GN, Caparelli-Daquer EM. Conversion technique from neuroendoscopy to microsurgery in ventricular tumors: Technical note. *Surg Neurol Int* 2016;7:S785-9.

<http://surgicalneurologyint.com/Conversion-technique-from-neuroendoscopy-to-microsurgery-in-ventricular-tumors:-Technical-note/>

INTRODUCTION

Ventricular tumors comprise a variety of benign and malignant mass lesions located within the ventricular cavity or arising from neural structures forming the ventricular system. These tumors are rare comprising less than 1% of all intracranial lesions.^[5] At present, endoscopic technique is broadly used for the treatment of tumor related hydrocephalus, ventricle tumor biopsy, and/or resection in a minimally invasive way, with minimal manipulation of normal brain tissue.^[2,4,6,12,14,21,22,24] Despite established as an option for ventricular tumor resection in selected cases, the method is not exempt of complications and limitations.^[8,14,22] Greenlee *et al.*^[16] described a conversion rate of 17% in the endoscopic treatment of colloid cyst. Thereby, an initial approach preparing for an eventual conversion to open craniotomy must be adopted. This eventuality has not been specifically addressed in the literature. Based on our own experience with endoscopic ventricular tumor treatment, here we report a series of patients where the conversion for open craniotomy was necessary, emphasizing the technique employed, the reasons for conversion, and the results obtained.

MATERIALS AND METHODS

Patients

From July 1995 to August 2015, 103 patients with ventricular tumors underwent endoscopic surgery for different purposes, e.g., hydrocephalus, biopsy,

septostomy, and tumor resection. In 6 patients, the procedure was converted to open craniotomy. There were 4 men and 2 women, ranging in age from 39 to 71 years (mean, 58.83 years). Clinical summary is presented in Table 1. Case 5 had a previous ischemic stroke and case 4 had a previous pilocytic astrocytoma resection and third ventricle-magna cistern shunt.

Operative technique

All patients followed the same surgical protocol of supine position, head 45° flexed. The entry point was chosen depending on the tumor side and location. For colloid cysts, the entry point was placed 4–5 cm anterior to the coronal suture and 3 cm lateral to the midline. For tumors located in the frontal horn of lateral ventricle, the Kocher's point was chosen [Figure 1]. We performed a coronal 5 cm skin incision centered by the endoscopy entry point with an extra lateral 2.5 cm skin mark to allow expansion. Decq rigid neuroendoscope (Karl Storz Co., Tuttlingen) or Lang rigid neuroendoscope (Lang Co., Rio de Janeiro) was used in these patients. The conversion was performed by extending the skin incision by 2.5 cm from each side. Then, a 5 cm diameter craniotomy was done advancing 2.5 cm lateral from the burr hole [Figure 1]. The dural opening was enlarged. The corticectomy was extended to 20–25 mm and the trajectory of the endoscope was explored with cerebral spatulas until reaching the ventricular cavity. One Layla brace was maintained fixed in the anterior direction with the posterior part of the trajectory gentle displaced using cotton pads and instruments.

Table 1: Summary of clinical characteristics of 6 patients undergoing conversion from neuroendoscopy to microsurgery for intraventricular lesions

Case no.	1	2	3	4	5	6
Age (years)	71	62	53	71	39	57
Sex	Male	Male	Male	Female	Female	Male
Clinical findings	Headache and memory loss	Confusion	Headache	Dementia	Headache	Headache, nausea and vomiting
Tumor location	3 rd ventricle	3 rd ventricle	Frontal horn	3 rd ventricle	Frontal horn	3 rd ventricle
Histological findings	Colloid cyst	Colloid cyst	Subependymoma	Colloid cyst	Subependymoma	Colloid cyst
Lesion size	17 mm	18 mm	21 mm	16 mm	15 mm	20 mm
Lesion aspect	Cystic	Cystic	Solid	Solid-cystic	Solid	Solid
Tumor consistency	Soft	Soft	Hard	Hard	Hard	Hard
Hydrocephalus	Yes	Yes	Yes	Yes	No	Yes
Previous shunt	No	No	No	Yes	No	Yes
Reasons for conversion	Cortical collapse	Technical problem with the scissor	Tumor consistency and technical problem with the bipolar	Tumor consistency	Broad implantation and high vascularization	Tumor consistency
Result	Complete resection	Complete resection	Complete resection	Complete resection	Complete resection	Complete resection
Outcome	No complaints	No complaints	No complaints	No complaints	CSF fistula and meningitis	Transient disorientation
Follow up (months)	216	160*	66	54	48	18

CSF: Cerebrospinal fluid. *Patient died of colorectal cancer 15 years after ventricle tumor surgical procedure

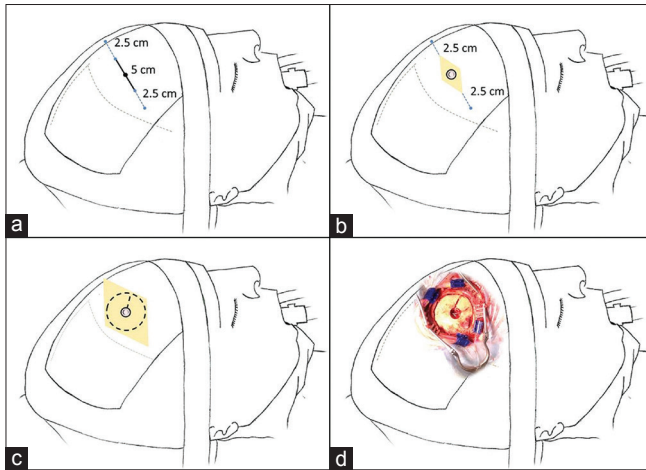


Figure 1: Description of the conversion technique. Patient in the supine position 45° angle head flexed. (a) 5 cm skin mark parallel to the coronal suture and an additional extension of 2.5 cm to each side to be prepared for conversion. (b) 5 cm skin incision and a burr hole to perform neuroendoscopy. (c) Expansion of the incision and a 5 cm diameter craniotomy extending from the endoscopic burr hole to perform microsurgery. (d) Operative aspect of incision and craniotomy

RESULTS

Total tumor removal was obtained in all patients as illustrated in case 3 [Figure 2]. Average time of hospitalization was 8 days (range, 4–12 days). There were one case of cerebrospinal fluid fistula and infection, and one case of transitory memory disturbance. In both the cases, we obtained a complete functional recovery. All patients except one remain shunt free. During the mean follow-up of 94 months (range, 18–216 months), no tumor recurrence was observed. Case 2 died of colorectal cancer 15 years after ventricle tumor surgery. Functionality could be considered satisfactory in as much as all regained cases previous social and employment condition.

DISCUSSION

Microsurgical resection is the standard technique for ventricular tumor treatment.^[1,4,5,17,25] The low incidence, deep location, and narrowness of the surgical field make this kind of tumor a constant challenge to neurosurgeons.^[4,25] There are two main options for open craniotomy microsurgical approach to the third ventricle and anterior lateral ventricle tumors, that is, the transcortical transventricular approach and the interhemispheric transcallosal approach.^[3,7,19,23] Which approach to adopt may depend on the location of the lesion within the ventricle, the goals of the operation, and the surgeon's experience.^[19] It does not seem to have any advantage to perform one over the other. To the best of our knowledge, there is no prospective randomized

trial comparing the results of these two microsurgical approaches. However, techniques to minimize the cortical damage in the transcortical approach are still being developed.^[9,18] Probably underreported, the section of the anterior part of the body of the corpus callosum may account for the deficits of memory, dysexecutive syndrome, and disturbances in interhemispheric transfer of learning.^[20] In this sense, when feasible, the endoscopic approach may represent the advantage of minimal cortical damage and preservation of the corpus callosum.

Applied by Dandy^[10] in the first half of the 20th century, neuroendoscopy regained its importance with technological and professional advances after the 1980s.^[4,10,11,13] The endoscopic approach is broadly used in ventricular tumors for the treatment of hydrocephalus, tumor biopsy, and tumor resection. It is a technique that reduces the manipulation of normal brain tissue in deep seated lesions.^[4,6,21,22] There are some ideal tumor characteristics that facilitate resection such as lesion size smaller than 20–30 mm diameter, soft consistency, cystic aspect, hydrocephalus association, and low to moderate vascularization.^[2,6] In some cases, conversion is necessary due to uncontrolled bleeding, solid and hardened tumor aspect, large base implantation size, as well as technical problems such as instrument malfunction.^[4,16] Our cases have shown that although considering ideal tumor characteristics for resection, some unexpected events can occur such as technical problems or an exceptional brain collapse. In two cases, a magnetic resonance imaging T2-weighted image showed a low intensity portion of the colloid cyst predicting the solid component of the lesion. In these cases, even considering that an open craniotomy would be necessary; a preliminary endoscopic approach allowed a better understanding of the tumor neighborhood anatomy and an easiest straightforward microsurgical resection of the lesion was obtained, as described by Gore *et al.*^[15] It is worth mentioning that ultrasonic aspiration was not available as an endoscopic instrument in our cases.

Considering that the endoscopic approach has the same cortical trajectory as the transcortical transventricular approach, the conversion is made just extending the size of the craniotomy. Instead of the classic incision parallel to the sagittal suture, commonly performed in neuroendoscopy, an incision parallel to the coronal suture is chosen. This allowed extending the incision without passing the anterior hairline in cases of conversion to open craniotomy in all patients of this series. There are no data in the literature defining the best conversion technique, however, the operative technique applied in our patients was satisfactory, easy, and fast to perform. Although simple and probably a logical choice for most neurosurgeons, here, we provide evidence that this surgical option is safe and effective.

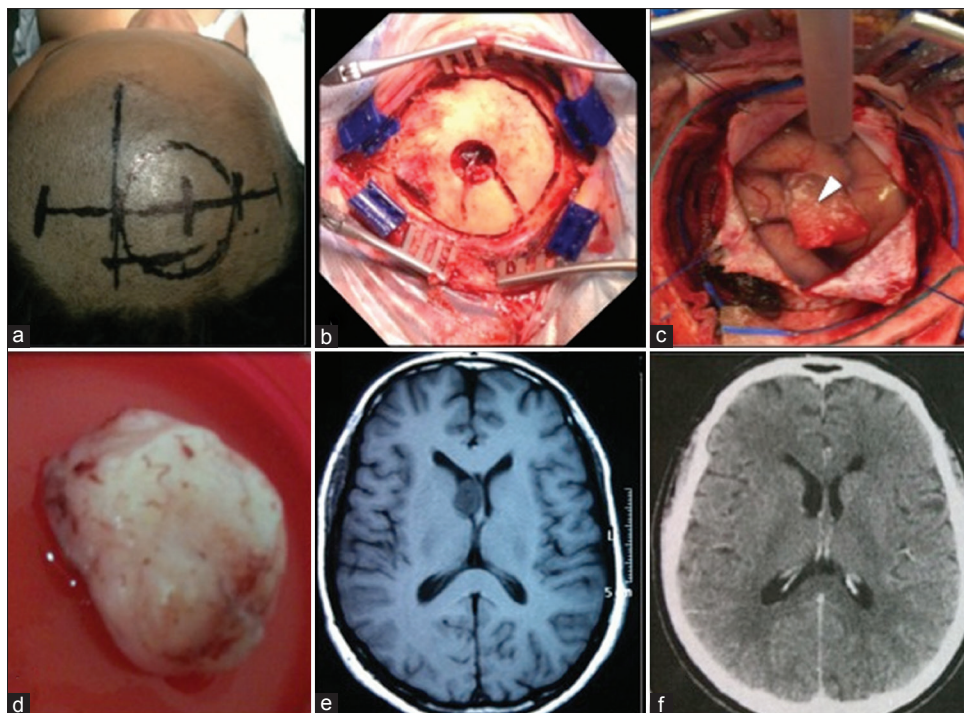


Figure 2: Case 3. (a) Routine surgical planning skin mark. (b) The craniotomy flap of 5 cm diameter. (c) Durotomy with exposure of the cortex and the hemostatic sponge sealing the endoscopic cortical access (arrowhead). Anterior positioning of the cerebral spatula fixed by the Layla brace for microsurgical exploration through the endoscopic path. (d) Subependymoma removed after conversion. (e) Axial T1-weighted magnetic resonance imaging obtained 2 months preoperative. (f) Axial computed tomography of the head obtained 3 months after the surgery

CONCLUSIONS

The standard conversion technique described in this series was easy to perform, showed excellent clinical and radiological results, bypassed endoscopic limitations, and made possible complete resection of ventricular lesions in all patients. There is little information about conversion technique in the literature, and therefore validation through further studies on the subject is necessary. The possibility of adapting the method according to ventricle locations other than the anterior horn of the lateral ventricle and the third ventricle roof may be considered.

Acknowledgments

We thank Diego Ramon Nigri for his assistance in preparing and drawing the figures.

Financial support and sponsorship

Authors received financial support from Fundação de Amparo à Pesquisa do Estado do Rio de Janeiro (FAPERJ).

Conflicts of interest

There are no conflicts of interest.

REFERENCES

1. Abdou MS, Cohen AR. Endoscopic treatment of colloid cysts of the third ventricle. *J Neurosurg* 1998;89:1062-8.
2. Ahmad F, Sandberg DI. Endoscopic management of intraventricular brain tumors in pediatric patients: A review of indications, techniques, and outcomes. *J Child Neurol* 2010;25:359-67.
3. Apuzzo MLJ, Chikovani OK, Gott PS, Teng EL, Zee CS, Giannotta SL, et al. Transcallosal, interforaminal approaches for lesions affecting the third ventricle: Surgical considerations and consequences. *Neurosurgery* 1982;10:547-54.
4. Barber SM, Rangel-Castilla L, Baskin D. Neuroendoscopic resection of intraventricular tumors: A systematic outcomes analysis. *Minim Invasive Surg* 2013;2013:898753.
5. Bertalanffy H, Krayenbuhl N, Wess C, Bozinov O. Ventricular Tumors. In: Winn HR, ed. *Youmans Neurological Surgery*. 6th ed. Philadelphia, PA: WB Saunders; 2011. p. 1534-5.
6. Cappabianca P, Cinalli G, Gangemi M, Brunori A, Cavallo LM, Divitiis E, et al. Application of neuroendoscopy to intraventricular lesions. *Neurosurgery* 2008;62 (2 Suppl):575-97.
7. Chamoun R, Couldwell WT. Transcortical-transforaminal microscopic approach for purely intraventricular craniopharyngioma. *Neurosurg Focus* 2013;34 (1 Suppl):Video.
8. Chowdhry SA, Cohen AR. Intraventricular neuroendoscopy: Complication avoidance and management. *World Neurosurg* 2013;79 (2 Suppl):S15.e1-10.
9. Cohen-Gadol AA. Minitubular transcortical microsurgical approach for gross total resection of third ventricular colloid cysts: Technique and assessment. *World Neurosurg* 2013;79:207.e7-10.
10. Dandy W. *Cerebral Ventriculotomy*. Bull Johns Hopkins Hosp 1922;33:189-90.
11. Davis L. *Neurological Surgery*. 1st Ed. Vol. 1. Philadelphia, PA: Lea & Febiger; 1936.
12. Decq P, Le Guerinel C, Brugières P, Djindjian M, Silva D, Kéravel Y, et al. Endoscopic Management of Colloid Cysts. *Neurosurgery* 1998;42:1288-94.
13. Enchev Y, Oi S. Historical trends of neuroendoscopic surgical techniques in the treatment of hydrocephalus. *Neurosurg Rev* 2008;31:249-61.
14. Gaab MR, Schroeder HW. Neuroendoscopic approach to intraventricular lesions. *J Neurosurg* 1998;88:496-505.

15. Gore PA, Nakaji P, Deshmukh V, Rekte HL. Synchronous endoscopy and microsurgery: A novel strategy to approach complex ventricular lesions. *J Neurosurg Pediatr* 2006;105:485-9.
16. Greenlee JD, Teo C, Ghahreman A, Kwok B. Purely endoscopic resection of colloid cysts. *Neurosurgery* 2008;62 (1 Suppl):51-5.
17. Grondin RT, Hader W, MacRae ME, Hamilton MG. Endoscopic versus microsurgical resection of third ventricle colloid cysts. *Can J Neurol Sci* 2007;34:197-207.
18. McLaughlin N, Prevedello DM, Engh J, Kelly DF, Kassam AB. Endoneurosurgical resection of intraventricular and intraparenchymal lesions using the port technique. *World Neurosurg* 2013;79 (2 Suppl):S18.e1-8.
19. Patel P, Cohen-Gadol AA, Boop F, Klimo P Jr. Technical strategies for the transcallosal transforaminal approach to third ventricle tumors: Expanding the operative corridor. *J Neurosurg Pediatr* 2014;14:365-71.
20. Peltier J, Roussel M, Gerard Y, Lassonde M, Deramond H, Le Gars D, et al. Functional consequences of a section of the anterior part of the body of the corpus callosum: Evidence from an interhemispheric transcallosal approach. *J Neurol* 2012;259:1860-7.
21. Schroeder HWS. General principles and intraventricular neuroendoscopy: Endoscopic Techniques. *World Neurosurg* 2013;79 (2 Suppl):S14.e23-28.
22. Schroeder HW. Intraventricular tumors. *World Neurosurg* 2013;79 (2 Suppl):S17.e15-9.
23. Symss NP, Ramamurthi R, Rao SM, Vasudevan MC, Jain PK, Pande A. Management outcome of the transcallosal, transforaminal approach to colloid cysts of the anterior third ventricle: An analysis of 78 cases. *Neurol India* 2011;59:542-7.
24. Teo C, Nakaji P. Neuro-oncologic applications of endoscopy. *Neurosurg Clin N Am* 2004;15:89-103.
25. Yasargil MG, Abdulrauf SI. Surgery of intraventricular tumors. *Neurosurgery* 2008;62 (6 Suppl 3):1029-40.