

A comparative ultrasonographic evaluation of intrarenal artery resistive index among hypertensive and normotensive adults in a black African population compared to a European population

George Madubueze¹ and Emmanuel Ugwa²

Acta Radiologica Open
7(1) 1–6
© The Foundation Acta Radiologica
2018
Reprints and permissions:
sagepub.co.uk/journalsPermissions.nav
DOI: 10.1177/2058460117752033
journals.sagepub.com/home/arr



Abstract

Background: Hypertensive nephropathy is an important medical problem among the black African population. Early detection of renovascular changes using ultrasonography can provide opportunity for immediate intervention towards preventing or at least delaying the irreversible hypertensive nephropathy.

Purpose: To compare intrarenal resistive index (RI) in healthy normotensive and hypertensive adults in Kano, Nigeria.

Material and Methods: A prospective comparative study of intrarenal RI using ultrasound in 150 hypertensives and 150 normotensive controls. The mean renal RI of the interlobar arteries of both kidneys were measured and recorded. The data were analyzed with the aid of computer-based SPSS 16.0 software for Windows.

Results: The age range of the study participants was 35–70 years. The mean interlobar artery RI values were 0.59 ± 0.04 and 0.59 ± 0.03 on the right and left sides, respectively, in normotensive control individuals while those of hypertensive individuals were 0.73 ± 0.03 and 0.73 ± 0.03 for the mean interlobar artery RI values on the right and left sides, respectively.

Conclusion: The intrarenal RIs were lower in normotensives when compared with the hypertensive participants, which were statistically significant. These showed that hypertension has significant effects on the kidneys, and with early detection and intervention, irreversible renal damage may be prevented.

Keywords

Doppler, ultrasound, intrarenal artery, essential hypertension

Date received: 5 July 2017; accepted: 8 December 2017

Introduction

Guidelines for diagnosis and when to commence treatment for hypertension, a sustained elevation of systolic blood pressure of ≥ 140 mmHg or diastolic blood pressure of ≥ 90 mmHg, have been extensively reviewed (1).

Although the kidneys play a central role in the control of high blood pressure, hypertension is a significant risk factor for renal injury and end-stage irreversible renal damage by inducing myointimal hyperplasia of the intrarenal arteries (2). Early detection of its effects

on the kidneys such as the renovascular changes using ultrasonography may prevent or at least delay irreversible renal damage through early treatment intervention.

¹Radiology Department, St Nicholas Hospital, Lagos, Nigeria

²Health Systems Development, Jhpiego-Affiliate of Johns Hopkins University, Abuja, Nigeria

Corresponding author:

Emmanuel Ugwa, Jhpiego-Affiliate of Johns Hopkins University, Plot 971, Reuben Okoya Crescent, Wuye District, Abuja, Nigeria.
Email: Emmanuel.Ugwa@jhpiego.org



Most studies in the UK and the United States reported not only a higher prevalence but also a higher awareness of hypertension in black people than in white people (3). The black population who are hypertensive have higher morbidity and mortality risks compared with their white counterparts (4). Africans have a higher prevalence and incidence of hypertension than Caucasians (5). Black men are at greater risk than white men for developing end-stage renal disease at every level of blood pressure, due to genetic variation in the renal epithelial sodium channels among the black people of African origin (6,7).

The overall prevalence of hypertension in Nigeria (2013) was 22.7% (8). It is more prevalent in the urban cities of Nigeria, with a rate of 32.7% than in the rural areas where a prevalence rate of 12.9% was noted probably due to modernization (8). A local survey showed that Kano has the highest prevalence of essential hypertension in Nigeria (9), making it important to study the effect on the kidneys.

Doppler ultrasonography of the renal vessels has been found useful in the diagnosis of renal artery stenosis in the face of equivocal angiogram and in differentiating real renal tumors from pseudo tumors such as a hypertrophied column of Bertin (10). The analysis of intrarenal arterial Doppler flow profile provides a non-invasive method of investigating renal medical diseases including hypertensive nephropathy. The intrarenal artery resistive index (RI) is one of the sonographic parameters used to assess hypertension-induced renovascular changes, because it quantifies the alterations in renal blood flow as a result of renal disease, making it more preferable in this study. Increase in renal arterial impedance is an early change in hypertensive nephropathy.

It is therefore important to detect this early renovascular change through routine surveillance since intervention at this stage may prevent or at least delay the renal damage. This study hopes to assess the value of renal RI in relation to the changes in renal hemodynamics among the hypertensives and normotensive subjects. The results from Nigerian participants will be discussed and compared with those observed in Caucasians.

Material and Methods

This was a prospective comparative study carried out over 12 months in Kano Northwestern Nigeria. Ethical approval for the study was obtained from the institution ethical review committee. Informed consent from the individuals was also obtained. To ensure adequate compliance with inclusion and exclusion criteria, brief clinical history (such as history of diabetes mellitus, sickle cell disease, end-stage renal disease, and

pregnancy) and physical examination (such as blood pressure and pulse rate) of the participants were taken. All the hypertensive individuals' hospital case files were cross-checked to ascertain their renal biochemistry status. Each of the participants was psychologically reassured and the procedure comprehensively explained. The ultrasonography was performed by one consultant radiologist with vast experience in Doppler ultrasound studies.

Individuals were scanned using a real-time/color-coded scanner (Mindray DC-6 Schenzhen, PR China) coupled with a 3.5-MHz transducer. The participant lay down supine on the examining couch. Scanning was done in supine and then prone positions. A global examination of the kidneys was performed (Fig. 1).

First, the main renal artery was assessed for exclusion of atherosclerosis before proceeding to the area of interest (interlobar arteries). Three Doppler waveforms were obtained from each kidney by sampling the interlobar artery (along the border of medullary pyramids) of the superior, middle, and inferior portions of the kidney and average value calculated manually, since intra-observer variability is a potential limitation in the measurement of renal RI. This variability was reduced to the minimum by taking the average of three measurements.

The flow velocity waveform was obtained at an optimal insinuating angle $< 30^\circ$ because small angle gives good Doppler curves with a good signal-to-noise ratio and accurate measurements. The Doppler tracing was also obtained and recorded by placing a gate of 2–4 mm (adjusted when necessary) over the interlobar artery; the lowest possible filter was utilized and the smallest scale that displayed the flow without aliasing was selected. The height of the Doppler waveforms was maximized to facilitate the measurements. A trend of three to five similar sequential Doppler waveforms were obtained during suspended respiration. Then the measurement of the RI was determined using the internal calipers and analytical software of the sonography unit. RIs from these waveforms were averaged to arrive at mean RI values for each kidney (Fig. 2). This was obtained by adding the RI from upper, mid, and lower pole intrarenal arteries and dividing by 3. The calculation $RI = PSV - EDV / PSV$ (11) was done automatically in the US device (RI = resistive index, PSV = peak systolic flow velocity, and EDV = end-diastolic flow velocity).

The inclusion criteria for hypertensive participants were: age ≥ 35 years; and consent to being recruited into this study. Exclusion criteria included: clinical or sonographic signs of end-stage renal disease; hypertensive patients who did not give informed consent for the study; those aged < 35 years (because essential

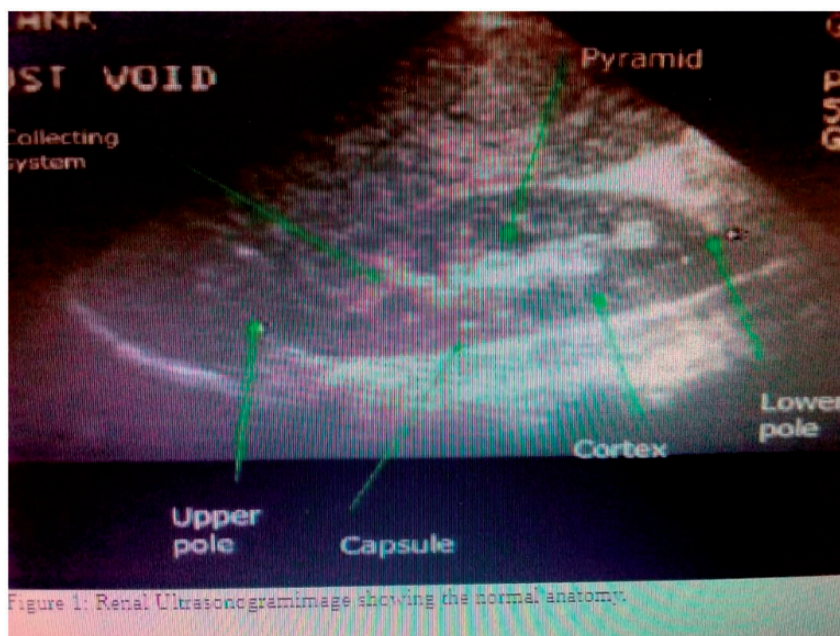


Fig. 1. Renal ultrasonogram showing the normal anatomy.

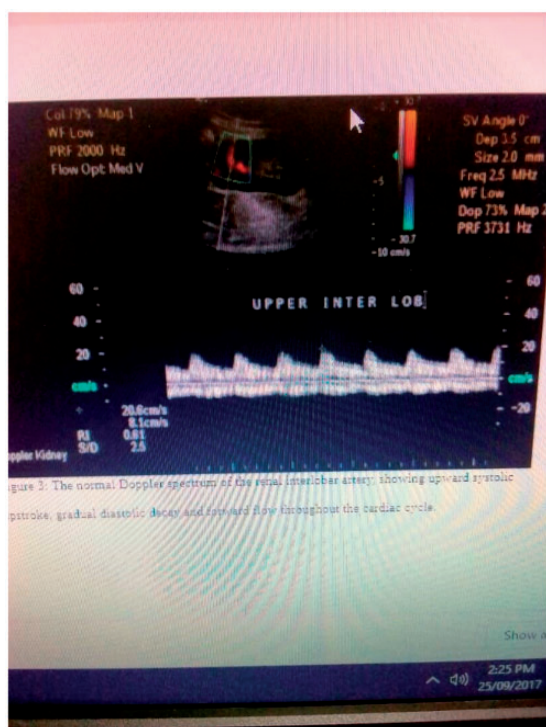


Fig. 2. The normal Doppler spectrum of the renal interlobar artery, showing upward systolic upstroke, gradual diastolic decay, and forward flow throughout the cardiac cycle.

hypertension most often occurs first during the middle-age years which begins at 35 years and ends around 68 years); hypertensive patients with diabetes mellitus, sickle cell disease, and ascites; and pregnancy.

For the control arm, the inclusion criteria were: healthy normotensive individuals (those with systolic blood pressure ≤ 140 mmHg or diastolic blood pressure ≤ 90 mmHg) matched for age coming to the radiology department for other investigations; and informed consent for the study. The exclusion criteria included: those aged < 35 years; individuals who did not provide consent; and normotensive individuals with have sickle cell disease, diabetes, renal disease, and ascites.

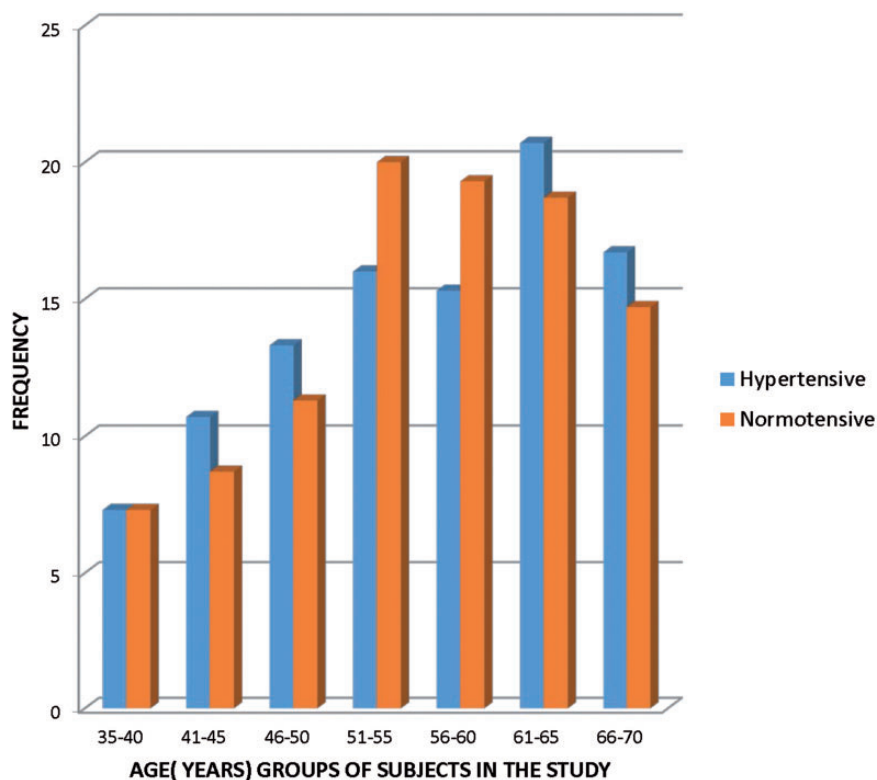
Results

A total of 300 participants (150 hypertensives and 150 normotensives) that fulfilled the inclusion criteria were recruited in this study (Table 1). The age range of the individuals (hypertensive and normotensive) in this study was 35–70 years. The control group (normotensive) was made up of 75 men and 75 women. The hypertensive group also consisted of 75 men and 75 women.

The majority of the hypertensive individuals (20.7%) in this study were aged 61–65 years, while the majority of the normotensive individuals (20%) were aged 51–55 years (Table 1). In both the hypertensives and normotensives, only 7.3% of the participants were within the lower limit of 35–40 years. The mean (\pm standard deviation [sd]) ages of both hypertensive and normotensive groups were 56.51 ± 8.71 years and 56.17 ± 7.86 years, respectively. This age difference was not statistically significant ($P=0.88$) (Table 1). The mean intrarenal (interlobar) artery RI was the same on the right and left sides in both

Table 1. Age distribution of participants in the study groups (n = 300)

Parameters	Frequency (%)		Mean \pm sd		P value
	Hypertensive (n = 150)	Normotensive (n = 150)	Hypertensive (n = 150)	Normotensive (n = 150)	
Age (years)			56.51 \pm 8.71	56.17 \pm 7.86	0.88
35–40	11 (7.3)	11 (7.3)			
41–45	16 (10.7)	13 (8.7)			
46–50	20 (13.3)	17 (11.3)			
51–55	24 (16)	30 (20)			
56–60	23 (15.3)	29 (19.3)			
61–65	31 (20.7)	28 (18.7)			
66–70	25 (16.7)	22 (14.7)			
Total	150 (100)	150 (100)			

**Fig. 3.** Histogram showing age distribution among hypertensive (n = 150) and normotensive (n = 150) individuals.

groups. In the normotensive group, the mean intrarenal (interlobar) artery RIs were 0.59 ± 0.04 and 0.59 ± 0.03 on the right and left sides, respectively, which were lower than that of the hypertensive participants with mean intrarenal (interlobar) RIs of 0.73 ± 0.03 and 0.73 ± 0.03 on the right and left sides, respectively. These differences were statistically significant with *P* values of < 0.001 on each side (Table 2).

Fig. 2 shows the normal Doppler spectrum of the renal interlobar artery, showing upward systolic upstroke, gradual diastolic decay, and forward flow throughout the cardiac cycle. A sample volume was placed within an intrarenal artery (interlobar) under color Doppler guidance and spectral analysis of the vascular signals was obtained. The measurement calipers were then set at the systolic peak and end diastole of a waveform. Fig. 3 shows age distribution among

Table 2. Ultrasonographic intrarenal (interlobar) artery RI for the normotensive and hypertensive groups (n = 300).

Renal parameters	Mean \pm sd		P value
	Normotensives	Hypertensives	
Right intrarenal (interlobar) artery RI	0.59 \pm 0.04	0.73 \pm 0.03	0.000
Left intrarenal (interlobar) artery RI	0.59 \pm 0.03	0.73 \pm 0.03	0.000

among the subjects. Proportion of subjects with hypertension is lowest among age group 35-40 years and highest among age group 61-65 years.

Discussion

The renal RI provides information about renal hemodynamic changes. In order to recognize abnormal renal Doppler findings in hypertensive individuals, the range of normal values of intrarenal artery Doppler parameters such as RI in the normotensive healthy group must be known, which is well established. As noted in this study, the mean renal RI of the normotensive participants was 0.59 ± 0.04 (range = 0.48–0.69) on the right and 0.59 ± 0.04 (range = 0.46–0.68) on the left. These findings were comparable to, although slightly higher than, that of Yusuf et al. (12) in south-western Nigeria, who reported 0.56 ± 0.04 (range = 0.48–0.67) and 0.56 ± 0.04 (range = 0.48–0.65) on the right and left sides, respectively. Viazzi et al. (13) in the United States showed that the average RI of 15 native kidneys from eight patients with no known renal abnormalities was 0.60, which is highly comparable with the findings of this study.

The findings of this study of the mean renal RI in the hypertensive group being 0.73 on each side were in concordance with that of Platt et al. (14) who reported that a mean RI value < 0.70 can be used as an indicator of normal renal vascular resistance in adults; while a mean RI value > 0.70 can be interpreted as a sign of elevated renal vascular resistance, which can be found in several renal parenchymal diseases such as essential hypertension. However, Mastorakou et al. (15) reported that higher values of RI > 0.70 can also be seen in elderly subjects (seventh decade and above) without renal dysfunction. This could be due to the fact that with aging there is a tendency of vascular compromise that may occur from atherosclerosis that may be responsible for elevation of renal RI (16). The abdominal aorta and the main renal arteries were first checked to identify possible plaques and stenosis, but normal findings do not rule out early atherosclerotic changes in the small intraparenchymal renal vessels.

Our study showed that, in the normotensive group, both the right and left kidneys had the same mean RI values of 0.59 on each side. This finding is in concordance with studies conducted by Mastorakou et al. (15) in the UK and Murat et al. (17) in Turkey, which reported that both sides had the same mean renal RI values in the normotensive healthy adults they studied.

The relatively higher mean renal RIs in the hypertensive group (0.73 ± 0.03 on each side) when compared with the normotensives (0.59 ± 0.04 on each side) is in concordance with the findings of Galesic et al. (18) who reported that the mean renal RI in hypertensive patients was 0.66 ± 0.05 , which is higher than that in healthy normotensive individuals (mean RI = 0.60 ± 0.03); however, this study, conducted by Galesic et al. in Europe, reported a RI that was significantly lower than that of the African counterpart, which may be attributed to genetic and environmental variations. According to Pontremoli et al. (19), this increase in mean renal RI value is an early sign seen in adults with essential hypertension as a result of hypertension-induced myointimal hyperplasia of the renal arterioles. RI may also be considered as a marker of systemic vascular changes and therefore a predictor of increased cardiovascular risk (20,21).

In conclusion, the RI values reported in our study are comparable with those reported in other regions of Nigeria. The values for the mean intrarenal RI were lower in normotensives when compared with the hypertensive individuals. The mean renal RIs in Nigerian hypertensives are slightly higher than those reported among Caucasians, presumably due to genetic and environmental variations. Therefore, hypertension has significant effects on the kidneys, especially in the black population, when compared with the European countries by causing renovascular changes.

Acknowledgements

The authors thank the management and staff of Aminu Kano Teaching Hospital, Kano for providing the facilities used in the study.

Declaration of conflicting interests

The author(s) declared no potential conflicts of interest with respect to the research, authorship, and/or publication of this article.

Funding

The author(s) received no financial support for the research, authorship, and/or publication of this article.

References

1. Hernandez-Vila EA. Review of the JNC 8 blood pressure guideline. *Tex Heart Inst J* 2015;42:226–228.

2. Khosla N, Kalaltzidis R, Bakris GL. The kidney, hypertension and remaining challenges. *Med Clin North Am* 2009;93:697–715.
3. Hertz RP, Unger AN, Cornell JA, et al. Racial disparities in hypertension prevalence, awareness and management. *Arch Intern Med* 2005;165:2098–2104.
4. Lackland DT. Racial differences in hypertension: implications for high blood pressure management. *Am J Med Sci* 2014;348:135–138.
5. Cooper RS, Wolf-maier K, Luke A, et al. An international comparative study of blood pressure in populations of European vs African descent. *BMC Med* 2005;3: 2–4.
6. Lindhorst J, Alexander N, Blignaut J, et al. Differences in hypertension between blacks and whites: an overview. *Cardiovasc J Afr* 2007;18:241–247.
7. Swift PA, Macgregor GA. Genetic variation in the epithelial sodium channel: a risk factor for hypertension in people of African origin. *Adv Ren Replace Ther* 2004;11: 76–86.
8. Adediran OS, Okpara IC, Adeniyi OS, et al. Hypertension prevalence in an urban and rural areas of Nigeria. *J Med Med Sci* 2013;4:149–154.
9. Akinkugbe OO. *Non-communicable diseases in Nigeria*, 4th ed. Abuja: Federal Ministry of Health, 1997.
10. Paul LA. The peripheral arteries. In : Paul LA, Paul AD, Myron AP, McDicken WN (eds). *Clinical Doppler Ultrasound*. London: Harcourt Publishers 2000; 81–82.
11. Knapp R, Plotzeneder A, Frauscher F. Variability of Doppler parameters in the healthy kidney. *J Ultrasound Med* 1995;14:427–429.
12. Yusuf BP, Atalabi OM. Renal resistive index in normal adults in Ibadan, South western Nigeria. *West Afr J Ultrasound* 2010;11:12–16.
13. Viazzi F, Leoncini G, Derchi LE, et al. Ultrasound Doppler renal resistive index: a useful tool for the management of the hypertensive patient. *J Hypertens* 2014;32: 149–153.
14. Platt JF, Ellis JH, Rubin JM. Examination of native kidney with duplex doppler ultrasound. *Semin Ultrasound CT MR* 1991;12:308–318.
15. Mastorakou I, Lindsell DRM, Piepoli M, et al. Pulsatility and resistance indices in intrarenal arteries of normal adults. *Abdom Imaging* 1994;19:369–373.
16. Pearce JD, Edward MS, Cravan TE, et al. Renal duplex parameters, blood pressure and renal function in elderly people. *Am J Kidney Dis* 2005;45:842–850.
17. Murat A, Akarsu S, Ozdemir H, et al. Renal resistive in healthy children. *Eur J Radiol* 2005;53:67–71.
18. Galesic K, Brkljacic B, Sabljari-Matovinovic M, et al. Renal vascular resistance in essential hypertension: duplex-doppler ultrasonographic evaluation. *Angiology* 2000;51:667–675.
19. Pontremoli R, Viazzi F, Martinoli C. Increased renal resistive index in patients with essential hypertension: a marker of target organ damage. *Nephrol Dial Transplant* 1999;14:360–365.
20. Geraci G, Mulè G, Geraci C, et al. Association of renal resistive index with aortic pulse wave velocity in hypertensive patients. *Eur J Prev Cardiol* 2015;22:415–422.
21. Bruno RM, Daghini E, Versari D, et al. Predictive role of renal resistive index for clinical outcome after revascularization in hypertensive patients with atherosclerotic renal artery stenosis: a monocentric observational study. *Cardiovasc Ultrasound* 2014;12:9.