



Case Report

Immune reconstitution inflammatory syndrome-associated disseminated Kaposi's sarcoma in a patient infected with human immunodeficiency virus: Report of an autopsy case

Chiu-Hsuan Cheng^a, Yung-Hsiang Hsu^{a,b*}

^aDepartment of Pathology, Buddhist Tzu Chi General Hospital and University, Taiwan, ^bSchool of Medicine, Tzu Chi University, Hualien, Taiwan

ABSTRACT

Immune reconstitution inflammatory syndrome is a collection of inflammatory disorders associated with paradoxical worsening of preexisting infectious processes following the initiation of highly active antiretroviral therapy (HAART) in individuals infected with human immunodeficiency virus (HIV). It involves a wide range of pathogens, neoplasms such as Kaposi's sarcoma (KS) and some autoimmune diseases. We describe an autopsy report of a 40-year-old man infected with HIV. He experienced a rapid dissemination of KS resulting in death within 6 months after starting HAART. His serum viral load had significantly decreased 4 log₁₀ within 32 days and his CD4+ T-cell count increased 4-fold. He presented with multiple skin lesions over the chin and anterior neck, which rapidly spread over the trunk, 4 extremities, perianal region, and penis. Finally, he developed acute dyspnea and a plain chest radiograph showed bilateral pulmonary infiltrations. Despite treatment, he died of acute respiratory failure. At autopsy, multiple KS lesions were noted in the bilateral lungs, liver, kidneys, and gastrointestinal tract. Increased inflammatory cytokines during immune reconstruction from HAART-reactive human herpes virus type-8 infection, linked to the tumorigenesis of KS, finally led to rapid dissemination and death.

KEYWORDS: *Acquired immune deficiency syndrome, Human immunodeficiency virus, Immune reconstitution inflammatory syndrome, Kaposi's sarcoma*

Received : 02-06-2016

Revised : 09-08-2016

Accepted : 11-08-2016

INTRODUCTION

The use of highly active antiretroviral therapy (HAART) has resulted in a dramatic reduction in the incidence of opportunistic infections, acquired immune deficiency syndrome (AIDS)-defining illnesses, and mortality in patients infected with human immunodeficiency virus (HIV) [1]. However, a small proportion of patients with HIV infection exhibit deterioration in their clinical status following HAART initiation despite control of virologic and immunologic parameters. This clinical condition is called immune reconstitution inflammatory syndrome (IRIS) [1]. Kaposi's sarcoma (KS), one of the most common AIDS-related neoplasms associated with human herpesvirus type-8 (HHV-8), can also be reactivated in an IRIS-related process. We report an autopsy case of a

40-year-old man infected with HIV who experienced rapid dissemination of KS resulting in death after HAART. The rapid progression in this patient could be explained by an IRIS-related process.

CASE REPORT

A 40-year-old man who had been generally healthy came to our hospital in June 1996, with chief complaints

*Address for correspondence:

Dr. Yung-Hsiang Hsu,
Department of Pathology, Buddhist Tzu Chi General Hospital,
707, Section 3, Chung-Yang Road,
Hualien, Taiwan.
E-mail: yhhsu@mail.tcu.edu.tw

This is an open access article distributed under the terms of the Creative Commons Attribution-NonCommercial-ShareAlike 3.0 License, which allows others to remix, tweak, and build upon the work non-commercially, as long as the author is credited and the new creations are licensed under the identical terms.

For reprints contact: reprints@medknow.com

How to cite this article: Cheng CH, Hsu YH. Immune reconstitution inflammatory syndrome-associated disseminated Kaposi's sarcoma in a patient infected with human immunodeficiency virus: Report of an autopsy case. Tzu Chi Med J 2017;29:41-5.

Access this article online

Quick Response Code:



Website: www.tcmjmed.com

DOI: 10.4103/tcmj.tcmj_9_17

of fever with chills and malaise for 2 months. He also had a weight loss of 8 kg within 1 month. Physical examination showed right cervical lymphadenopathy and a posterior pharyngeal tumor. The cervical lymph node proved to be tuberculosis on biopsy and acid-fast stain and the posterior pharyngeal tumor showed KS on histology. An abdomen to pelvic computed tomography (CT) scan did not show any abnormal lesion in the liver, spleen, and bilateral kidneys. Both HIV enzyme-linked immunosorbent assay and western blot were positive for HIV-1. The serologic test for syphilis was positive. He was treated with a combination of three antituberculosis drugs (ethambutol, pyrazinamide, isoniazid), acyclovir for herpes simplex virus infection, ceftriaxone, amikacin, and trimethoprim-sulfamethoxazole. He began receiving zidovudine in October in 1996. This was replaced by didanosine (ddI) 1 month later because of refractory bone marrow suppression.

At his second admission to our hospital in December 1996, multiple skin lesions were found over his chin and anterior neck. Excisional biopsies of those lesions revealed cutaneous KS. The CD4+ T-cell absolute count was only 18 cells/ μ L. Tuberculosis, syphilis, candidiasis, and cytomegalovirus retinitis were diagnosed and treated. The antiretroviral drug ddI was discontinued in January 1997. Bilateral pulmonary infiltrations were observed in chest radiographs. Pneumocystic pneumonia was impressed and treated with trimethoprim-sulfamethoxazole. The symptoms had improved at the time of hospital discharge.

The patient was admitted again 1 month later for dyspnea and cough with sputum production for 2 weeks. More immunosuppression was noted with a CD4+ T-cell absolute count of 10 cells/ μ L. HAART was initiated in April 1997 with zalcitabine, lamivudine, and saquinavir. The pre-HAART serum HIV RNA level was 313.1×10^3 copies/mL.

The HIV viral load decreased to 20.93 copies/mL (4 log₁₀ drop) at 32 days after initiation of HAART. Meanwhile, the CD4+ T-cell count increased to 41 cells/ μ L (4-fold rise). However, the patient's skin lesions progressed to involve the trunk, all extremities, the perianal region, and foreskin of the penis. He received amputation of the right big toe because of KS following a biopsy.

After 5 months, the patient developed fever with dyspnea. Bilateral diffuse pulmonary infiltrations were observed again in plain chest radiographs. Despite treatment with antituberculosis drugs, HAART, trimethoprim-sulfamethoxazole, cephapirin, and gentamycin, he died approximately 6 months after starting HAART.

At autopsy, multiple KS lesions were seen over the chin, neck, left flank, four extremities, perianal area, and prepuce of the penis, mostly presenting as nodular or ulcerative lesions. Two tumor masses were seen between the tonsils and between the tongue base and oropharynx. No pleural effusion was seen in the thoracic cavity. The right and left lungs weighed 750 and 780 g, respectively, and had thickened pleurae and foci of adhesions. Some hemorrhagic nodules were seen on the pleural surfaces. On cutting, hemorrhagic, yellowish nodules involving all segments of all lobes were found [Figure 1a]. The hilar nodes and paratracheal nodes were also involved by tumors. Serous ascitic fluid 300 mL was obtained from the abdominal cavity. Some foci of KS lesions were observed in the liver appearing as small nodules [Figure 1b]. The kidneys weighed 120 g each and were also involved by KS, especially in the cortical areas [Figure 1c]. In the gastrointestinal (GI) tract, many KS nodules were observed in the mucosa of the stomach (especially at the lesser curvature), duodenum, jejunum, ileum, colon, and anal canal. Those tumors presented with polypoid, nodular, and/or ulcerative patterns [Figure 1d-g].

Microscopically, all representative tumor nodules were composed of spindle cells in fascicles or bundles or storiform, vascular channels filled with erythrocytes lined by flat endothelial cells and extravasated erythrocytes [Figure 2a], with HHV-8 antigen positivity [Figure 2b], diagnostic of KS. Multiple disseminated KS nodules involving the lungs surrounded the bronchioles and vessels (bronchocentric and angiocentric patterns), which were the cause of death in this patient [Figure 2c].

The patient had no lesions in the liver, kidneys, or GI tract in the abdomen to pelvic CT scans taken in June 1996. Multiple disseminated KS was observed in several visceral organs at autopsy. Skin KS progression was noted 1 month after HAART in spite of a rise in the CD4+ T-cell count and a significant reduction in the viral load. Thus, his rapid progression before death could be explained as a consequence of IRIS.

DISCUSSION

KS was first described by Hungarian dermatologist, Moritz Kaposi, in 1872. It is the most common neoplasm in patients with AIDS. There are four epidemiological-clinical types of KS. The classic type occurs in the lower legs of elderly men of Mediterranean and East European descent and has a good prognosis. The endemic type, seen in Equatorial Africa, is aggressive in children, with frequent lymph node involvement. Posttransplant immunosuppressed patients may experience iatrogenic KS. AIDS-related KS is the most aggressive type and

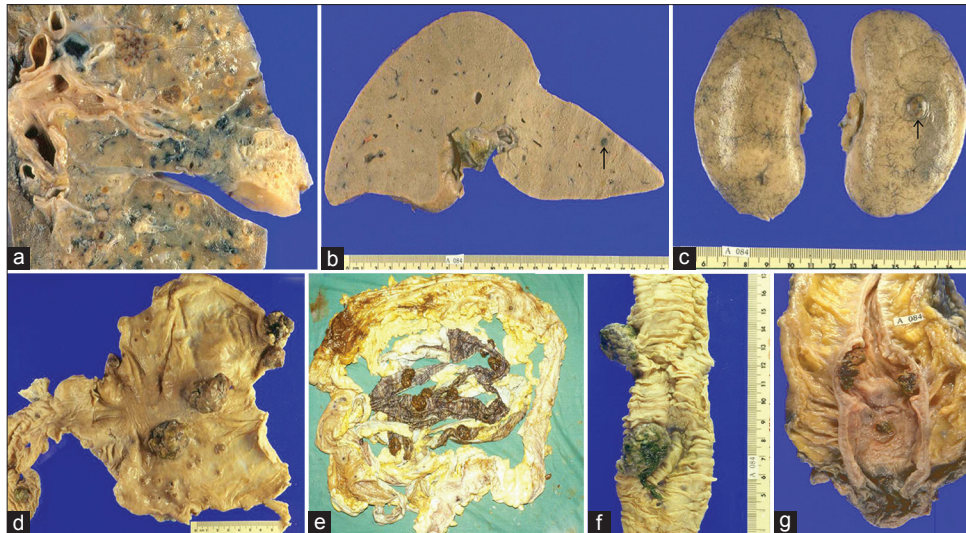


Figure 1: Gross appearance of Kaposi's sarcoma in various organs. (a) Multiple yellowish nodules surrounding the bronchovascular structures of the left lung. (b) A well-circumscribed lesion (arrow) 0.5 cm in diameter in the liver. (c) One nodular tumor (arrow) in the left kidney. (d) Two solid nodules at the lesser curvature surrounded by smaller lesions over the gastric mucosa. (e-g) Multiple polypoid or nodular lesions found throughout the entire alimentary tract

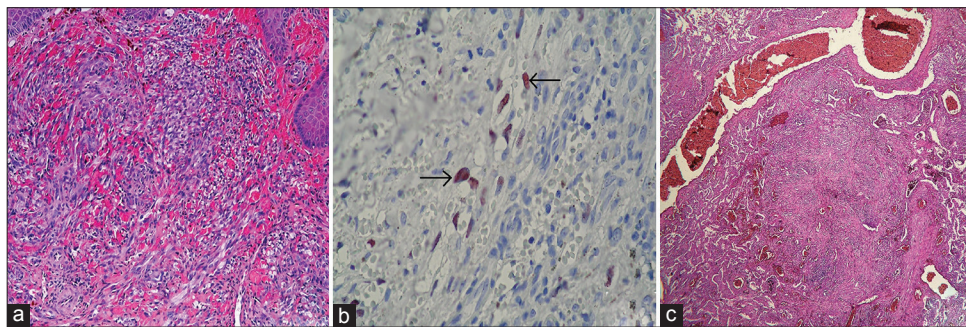


Figure 2: Histological findings of Kaposi's sarcoma. (a) Skin: proliferating spindle cells and split-like vessels in the dermis (H and E, $\times 200$). (b) Skin: human herpes virus type-8 positive (arrows) spindle cells (IHC, $\times 400$). (c) Lung: Bronchocentric and angiocentric patterns (H and E, $\times 40$)

affects young homo- or bi-sexual men with frequent visceral organ involvement [2].

Typically, KS involves the skin of the trunk, penis, legs, and feet and mucosa of the mouth and nose and less frequently affects visceral organs. Common extracutaneous sites of involvement are the GI tract, lung, liver, and lymph nodes. The incidence of pulmonary KS is approximately 10% in patients with AIDS and 6%–32% in patients with cutaneous KS. Pulmonary disease is seldom found without a concomitant extrapulmonary presentation [3]. The clinical presentation of pulmonary KS is nonspecific. The most common symptoms are cough, shortness of breath, and fever. The radiographic findings typically show reticulonodular infiltrations or diffuse interstitial infiltrations [4]. Pathologic findings consist of loosely aggregated spindle cells with atypical nuclei and occasional mitotic figures, often displaying angiocentric and lymphangitic distribution as in our case. Pulmonary lesions are typically less cellular than cutaneous lesions. Split-like spaces filled

with erythrocytes are lined by flat endothelial cells. Extravasated erythrocytes and hemosiderin between the spindle cells are present [2].

Widespread use of combined antiretroviral therapy and HAART has dramatically reduced the incidence and improved the prognosis of AIDS-associated KS. However, a small proportion of patients with HIV infection experience deterioration in their clinical status following initiation of HAART despite control of virologic and immunologic parameters. This clinical response, known as IRIS, has been related to a growing number of infectious, autoimmune, and neoplastic manifestations, including tuberculosis, nontuberculous mycobacteria, cryptococcus, herpesviruses, and KS [5].

The criteria proposed by French *et al.* define IRIS-associated KS as an abrupt clinical worsening of a previously existing KS (paradoxical IRIS-KS) or a new presentation of a previously unknown KS (unmasking IRIS-KS) in temporal association with initiation or reinitiation of HAART or change to a more active

regimen, either with a concomitant reduction of at least 1 log₁₀ in the HIV-1 RNA levels at the time of the IRIS event or with 2 of the following 3 minor criteria: (a) a 2-fold increase in the CD4+ T-cell count after HAART, (b) an increase in the immune response (HHV-8 antibodies), and (c) a spontaneous resolution of disease without specific chemotherapy with continuation of HAART [5].

IRIS results from the rapid expansion of antigen-specific CD4+ and CD8+ lymphocytes following initiation of HAART [6]. Recovery of the CD4 T lymphocyte count following HAART is normally biphasic. The first phase is associated with an increase in the numbers of CD45RO+ memory T-cells redistributed from lymphoid tissue to the peripheral circulation. Thereafter, a slower secondary increase of predominately naive CD4+ T-cells (CD45RA+, CD62 L+) occurs [7]. Interferon gamma (IFN-γ)-secreting CD4+ cells and an excess of T-helper 1 cytokines with a concomitant suppression of interleukin-10, a physiological suppressor of IFN-γ production, lead to an imbalance between pro- and anti-inflammatory immune responses during the immune reconstitution phase characterized by IRIS [6]. HAART can increase the absolute number of lymphocytes secreting tumor necrosis factor alpha, IFN-γ, and interleukin-1-beta, which are linked to the tumorigenesis of KS. These inflammatory cytokines both reactivate latent HHV-8 infection, and upregulate the expression of integrins, matrix metalloproteinases, and vascular endothelial growth factor receptors by endothelial cells [6]. In addition, most HIV-infected patients with KS have low or undetectable HHV-8-specific cytotoxic T lymphocytes. After the initiation of HAART, CD8+ T-cells specific for HHV-8 antigens are detectable. Thus, the recovery of this cell population is also thought to be partly responsible for IRIS [6].

A prospective study in Mozambique identified 4 independent predictors of IRIS-KS, including clinical pretreatment of KS, detectable plasma HHV-8 DNA, hematocrit <30%, and a high plasma HIV viral load (≥50 copies/mL) [8]. Another study performed with the Chelsea and Westminster HIV cohort showed that IRIS-KS occurred in patients with higher CD4+ cell counts at the time of KS diagnosis, KS-associated edema, and whose receiving therapy with both protease inhibitors and nonnucleosides together [1].

Pulmonary KS is often fatal and almost always requires chemotherapy. Adding HAART to chemotherapy in patients with pulmonary KS significantly improved the median survival in a study conducted by

Holkova *et al.* [9]. However, HAART may rarely induce an immune system reconstitution and finally lead to death. Nonetheless, IRIS does not indicate failure of HAART or a need for changes in the antiretroviral regimen. Instead, chemotherapy in conjunction with HAART can effectively control the symptoms of IRIS and resolve KS [10].

CONCLUSION

In this case study and autopsy report, we present an unusually rapid dissemination of KS to various internal organs including pulmonary involvement, which was the cause of death, despite viral control and immunologic improvement by HAART. The pathogenesis was explained by an excess of inflammatory cytokines including KS tumorigenic ones during the IRIS-related process induced by treatment.

Financial support and sponsorship

Nil.

Conflicts of interest

There are no conflicts of interest.

Declaration of patient's consent

The authors certify that the patient have obtained appropriate patient consent form. In the form the patient has given his consent for his images and other clinical information to be reported in the journal. The patient understands that his name and initial will not be published and due efforts will be made to conceal their identity, but anonymity cannot be guaranteed.

REFERENCES

1. Bower M, Nelson M, Young AM, Thirlwell C, Newsom-Davis T, Mandalia S, et al. Immune reconstitution inflammatory syndrome associated with Kaposi's sarcoma. *J Clin Oncol* 2005;23:5224-8.
2. Fletcher CD, Bridge JA, Hogendoorn PC, Mertens F. WHO Classification of Tumours of Soft Tissue and Bone. 4th ed. Lyon: IRAS Press; 2013. p. 151-3.
3. Wang TH, Hsu YH, Hsu WL. Pulmonary Kaposi's sarcoma in patient with HIV infection: A case report. *Ther Radiol Oncol* 2010;17:153-9.
4. Garay SM, Belenko M, Fazzini E, Schinella R. Pulmonary manifestations of Kaposi's sarcoma. *Chest* 1987;91:39-43.
5. French MA, Price P, Stone SF. Immune restoration disease after antiretroviral therapy. *AIDS* 2004;18:1615-27.
6. Stover KR, Molitoris S, Swiatlo E, Muzny CA. A fatal case of Kaposi sarcoma due to immune reconstitution inflammatory syndrome. *Am J Med Sci* 2012;343:421-5.
7. Pakker NG, Notermans DW, de Boer RJ, Roos MT, de Wolf F, Hill A, et al. Biphasic kinetics of peripheral blood T cells after triple combination therapy in HIV-1 infection: A composite of redistribution and proliferation. *Nat Med* 1998;4:208-14.
8. Letang E, Almeida JM, Miró JM, Ayala E, White IE,

- Carrilho C, et al. Predictors of immune reconstitution inflammatory syndrome-associated with Kaposi sarcoma in mozambique: A prospective study. *J Acquir Immune Defic Syndr* 2010;53:589-97.
9. Holkova B, Takeshita K, Cheng DM, Volm M, Wasserheit C, Demopoulos R, et al. Effect of highly active antiretroviral therapy on survival in patients with AIDS-associated pulmonary Kaposi's sarcoma treated with chemotherapy. *J Clin Oncol* 2001;19:3848-51.
10. Odongo FC. Fatal disseminated Kaposi's sarcoma due to immune reconstitution inflammatory syndrome following HAART initiation. *Case Rep Infect Dis* 2013;2013:546578.