

Received: 2020.12.26

Accepted: 2021.02.12

Available online: 2021.02.24

Published: 2021.04.04

A Household *Microsporum canis* Dermatophytosis Suggested by Matrix-Assisted Laser Desorption/Ionization Time-Of-Flight Mass Spectrometry Analysis

Authors' Contribution:

Study Design A
Data Collection B
Statistical Analysis C
Data Interpretation D
Manuscript Preparation E
Literature Search F
Funds Collection G

ABCD 1,2 **Maya Hariu**
ABCF 1,2 **Yuji Watanabe**
CDEF 1 **Daishi Shimada**
CDEF 1 **Haruka Imai**
BCDE 1,2 **Kazuki Takano**
BCDF 1,3 **Yasuhiro Kamioka**
ABCDEFG 1 **Masafumi Seki**

1 Division of Infectious Diseases and Infection Control, Tohoku Medical and Pharmaceutical University Hospital, Sendai City, Miyagi, Japan
2 Laboratory for Clinical Microbiology, Tohoku Medical and Pharmaceutical University Hospital, Sendai City, Miyagi, Japan
3 Division of Pharmacy, Tohoku Medical and Pharmaceutical University Hospital, Sendai City, Miyagi, Japan


Corresponding Author: Masafumi Seki, e-mail: m-seki@tohoku-mpu.ac.jp, seki@hosp.tohoku-mpu.ac.jp
Conflict of interest: None declared

Case series**Patients:** Female, 4-year-old • her family (father, mother, sister)**Final Diagnosis:** *Microsporum canis* dermatophytosis**Symptoms:** Itching**Medication:** —**Clinical Procedure:** Time-of-flight mass spectrometry (TOF-MS)**Specialty:** Infectious Diseases**Objective:** Unknown etiology

Background: *Microsporum canis* is a pathogenic dermatophyte that usually colonizes animals, and secondary infection of humans comes from pets. The infected patients show hair loss with erythema and are diagnosed as having dermatophytosis, but the transmission routes of *M. canis* from animals to others are sometimes unclear, although they are critical to the treatment of patients and infection control. To identify the pathogens and the transmission routes, morphological observations by microscopes and conventional polymerase chain reaction (PCR) have been used; however, matrix-assisted laser desorption/ionization time-of-flight mass spectrometry (MALDI-TOF MS) has recently become a useful tool.

Case Reports: A 4-year-old girl presented with pruritic, erythematous lesions on the head with alopecia. The dermatologists diagnosed dermatophytosis caused by fungal infection, and *M. canis* was suspected as the pathogen because of the morphologic characteristics. All of her family members subsequently showed similar hair findings and symptoms. The growth of *M. canis* was also observed in serial cultures, and all strains were confirmed to be identical, but different from the standard strain on MALDI-TOF MS. In this household infection case, abandoned cats were considered to be the origin of *M. canis* transmission, and the family members finally improved following oral administration of antifungal agents.

Conclusions: *M. canis* should be carefully investigated as the causative pathogen of dermatophytosis secondary to household infection. MALDI-TOF MS appears to be an excellent tool to confirm the transmission routes of the fungal pathogens among infected patients.

Keywords: Mass Spectrometry • Mitosporic Fungi • ZoonosesFull-text PDF: <https://www.amjcaserep.com/abstract/index/idArt/930713>

1139



—



2



18



Background

Microsporum canis is a pathogenic and zoophilic dermatophyte that typically colonizes the outer surface of an animal's body. *M. canis* usually infects humans as a secondary infection from pets, including dogs and cats [1,2] *M. canis* infection of humans induces tinea capitis and tinea corporis, particularly in children, and its dermatophytosis is known as Celsus kerion [1-4]. In general, it shows the typical pathophysiological signs and symptoms, and *M. canis* invasion of hair and skin is sometimes observed on the head of the patients [5]. Therefore, infection with *M. canis* is usually associated with alopecia, and infection has been diagnosed by isolation of fungus, which has characteristic hyphae or arthroconidia, from the patients' hair lesions [6,7]. In asymptomatic cases, both Wood's lamp examination and microscopic analyses of suspected areas are highly recommended.

However, these microscopic identifications were affected by the skills and experiences of the microbiologists; therefore, molecular-based detection systems, such as polymerase chain reaction (PCR) and PCR-fingerprinting, have been developed to detect the fungal pathogens of dermatophytosis and their transmission routes [8,9].

Furthermore, in the present case, household infection by *M. canis* was confirmed by isolation of identical, but different from the standard strain, fungi from the father, mother, and sister by the more novel proteomic detection system, such as matrix-assisted laser desorption/ionization time-of-flight mass spectrometry (MALDI-TOF MS).

The analysis of this case was approved by the Committee for Clinical Scientific Research of Tohoku Medical and Pharmaceutical University Hospital on April 11, 2019 (No. ID 2019-2-014), and the patients provided written informed consent for use of their culture specimens, although the samples were collected as part of routine laboratory analyses.

Case Reports

A 4-year-old girl visited the dermatology clinic because of itching of the head, for which bacterial infection with some allergic reaction was suspected. She received oral antibiotics and anti-allergy drugs, but did not improve after 2 weeks of drug therapy. Her symptoms became severe, and erythema and slight hair loss appeared.

The patient consulted our hospital, where dermatophytosis as a result of fungal infection was suspected. Direct microscopy of her hair and purulent secretions showed morphological characteristics of septated hyphae and spindle-shaped macroconidia

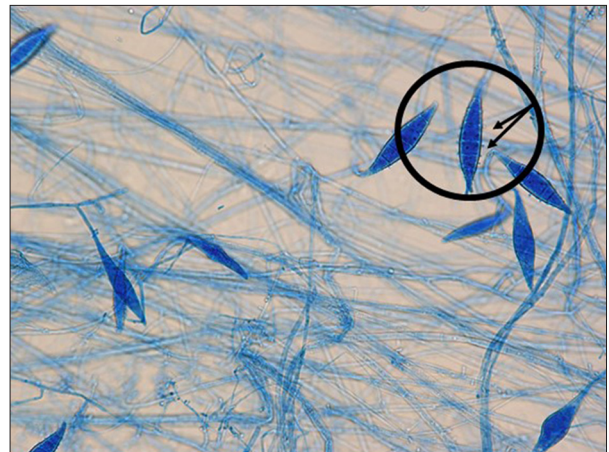


Figure 1. Light microscopy findings. Lactophenol-Cotton Blue staining of the species grown from the patient's skin. Characteristic ship-like and spindle-shaped macroconidia with granular spikes on the surface are found (arrows and circles, $\times 1000$).

with an asymmetrical apical knob (Figure 1). Based on these, *M. canis* was suspected as the pathogen, and the patient improved after being given the oral antifungal agent itraconazole 50 mg/day for 1 month.

However, within 1 week after her first visit to our hospital, her family members, including her father, mother, and 10-year-old older sister, developed similar symptoms and hair findings. All of these family members were asked to visit our hospital; the fungus in each case had similar characteristics that were suggestive of *M. canis* on a potato dextrose agar with Chloramphenicol Plate (Nissui Co. Ltd., Tokyo, Japan) developed after 10-14 days at 30°C. The fungi were different from the standard strain, but they were confirmed to be identical by MALDI-TOF MS (Figure 2). The family also received the appropriate amount of itraconazole dependent on body weight and subsequently improved.

This family had no pets, but the initial patient, the 4-year-old girl who first showed symptoms, would usually feed abandoned cats near the park. These abandoned cats were considered the origin of the *M. canis* transmission in this household infection case.

Discussion

Hair loss with erythema caused by *M. canis* may sometimes be associated with exposure to animals, but an outbreak with household transmission confirmed by MALDI-TOF MS was described in this report. The natural reservoir of *M. canis* is dogs and cats, and secondary infection in humans causes tinea capitis and tinea corporis. These hair and skin lesions have been

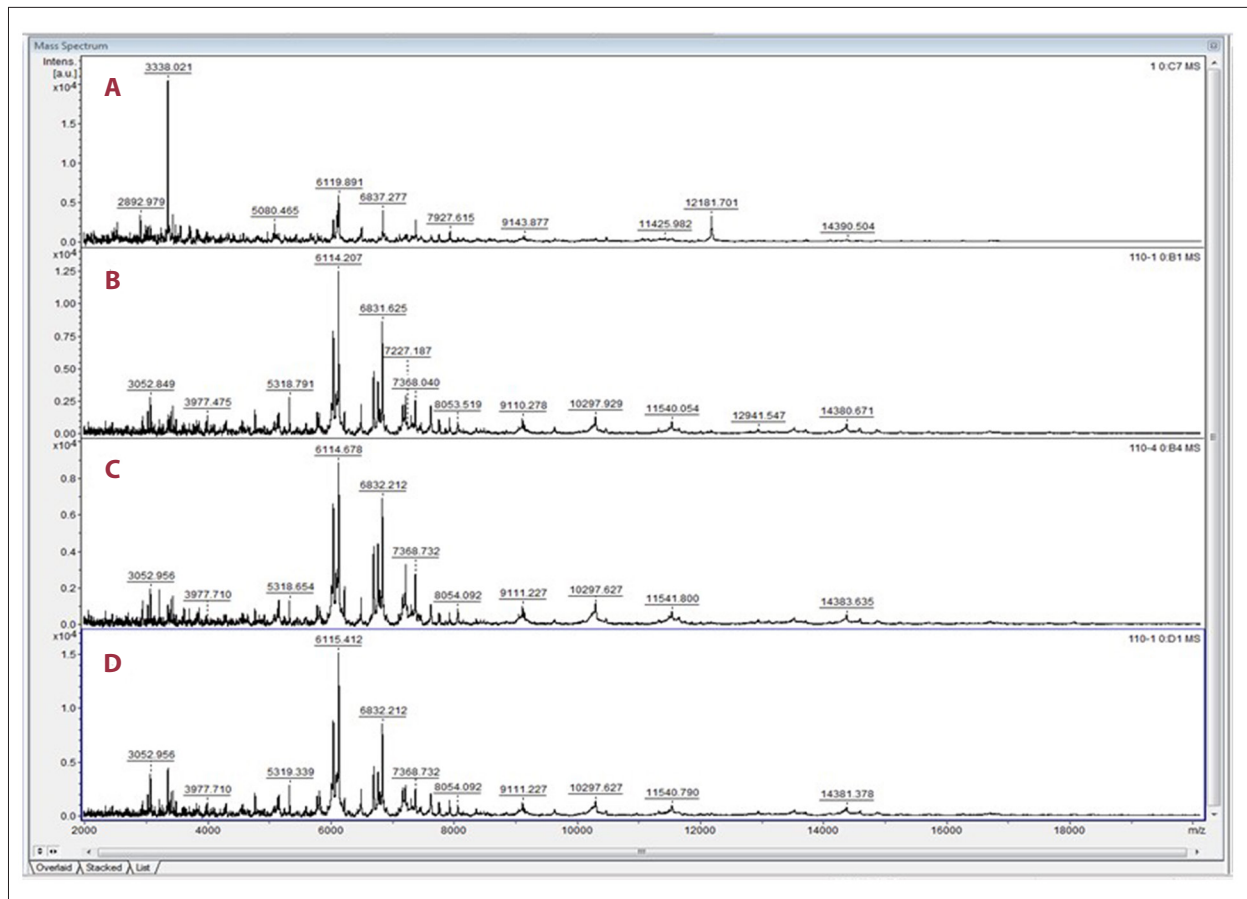


Figure 2. Mass spectral analysis findings. The findings for *Microsporium canis* ATCC standard strain (A) are different, but matched peaks are seen in the *M. canis* species isolated from the father (B), mother (C), and sister (D).

observed in severe cases when *M. canis* infects immunocompromised hosts [5-7]. However, *M. canis* has been reported as one of the transmitted pathogens in hospitals and some facilities, including military bases [10-12].

In a large outbreak that caused symptomatic infections in 53 of 502 staff members on a military base, logistic regression analysis showed that female sex and contact with cats on the base were risk factors. Multiple exposures to stray cats were suggested to have caused infection of mainly young female soldiers who assumed guard duties, whereas the other individuals were infected by person-to-person transmission. The genotype of the isolated *M. canis* was identical in 4 cats and 4 patients, but different in 2 patients [10]. Among the developing countries, local socio-economic conditions and poor cultural practices can influence the prevalence and outbreak of the particular infection in the given areas [11]. An outbreak of *M. canis* infection that affected 12 persons in 2 elementary schools was also reported, and the contact with adopted stray cats at a birthday party was suggested as the most probable source of the outbreak [12].

In this present case, the origin was not directly identified, but the history of the index case taking care of abandoned cats in a nearby park was likely the clue to the cause. These abandoned cats were very likely the reservoir of the *M. canis* and the origin of transmission to the family. *M. canis* has a characteristic morphology and produces septate hyphae and macroconidia that are spindle-shaped and have asymmetrical, apical knobs [3,4,6,7]. Morphological identification is straightforward for isolates that form the typical and characteristic features. However, accurate identification of these structures relies on the experience of the staff, and in daily practice the mycology laboratory is often confronted with strains that present with atypical colony morphology and physiological tests, conidia, or sterile growth. In comparison, molecular/proteomic methods are faster and less dependent on staff workload and expertise [3,9].

Recently, MALDI-TOF MS was suggested to be a reliable, rapid, and effective method for the routine identification of fungi, including dermatophytes, and 100% of *M. canis* were identified [13-15]. In addition, MALDI-TOF MS has been shown to be cost effective, with limited expenses for material and reagents, and

it has a considerably shorter turnaround time compared with that of routine culture or even molecular identification [16-18]. Some reports on dermatophytes showed that MALDI-TOF MS led to low consumable costs and results that can be provided within 3-4 days after culture, whereas molecular analyses, in particular DNA sequencing, were expensive and time consuming [8,14,17]. We expect that MALDI-TOF MS will become a very effective tool for not only identification of pathological fungi, but also for the investigation of fungus transmission in nosocomial and household settings.

References:

1. Yamada S, Anzawa K, Mochizuki T. An epidemiological study of feline and canine dermatophytoses in Japan. *Med Mycol J*. 2019;60:39-44
2. Thakur R, Kalsi AS. Outbreaks and epidemics of superficial dermatophytosis due to trichophyton mentagrophytes complex and microsporum canis: Global and Indian scenario. *Clin Cosmet Investig Dermatol*. 2019;12:887-93
3. Hubka V, Dobiašova, Dobiaš R, et al. *Microsporum aenigmaticum* sp. nov. from *M. gypseum* complex, isolated as a cause of tinea corporis. *Med Mycol*. 2014;52:387-96
4. Gräser Y, Scott J, Summerbell R. The new species concept in dermatophytes – a polyphasic approach. *Mycopathologia*. 2008;166:239-56
5. Mock M, Monod M, Baudraz-Rosset F, et al. Tinea capitis dermatophytes: Susceptibility to antifungal drugs tested in vitro and in vivo. *Dermatology*. 1998;197:361-67
6. Aste N, Pau M. Tinea capitis caused by *microsporum canis* treated with terbinafine mycoses. 2004;47:428-30
7. Hsiao YH, Chen C, Han HS, et al. The first report of terbinafine resistance *Microsporum canis* from a cat. *J Vet Med Sci*. 2018;80:898-900
8. Faggi E, Pint G, Campisi E, et al. Application of PCR to distinguish common species of dermatophytes. *J Clin Microbiol*. 2001;39:3382-85
9. Dobrowolska A, Debska J, Kozłowska M, et al. Strains differentiation of *Microsporum canis* by RAPD analysis using (GACA)₄ and (ACA)₅ primers. *Pol J Microbiol*. 2011;60:145-48
10. Brosh-Nissimov T, Ben-Ami R, Astman N, et al. An outbreak of *Microsporum canis* infection at a military base associated with stray cat exposure and person-to-person transmission. *Mycoses*. 2018;61:472-76
11. Havlickova B, Czaika VA, et al. Epidemiological trends in skin mycoses worldwide. *Mycoses*. 2008;51:2-15
12. Subelj M, Svetičič Marinko J, Učakar V. An outbreak of *Microsporum canis* in two elementary schools in a rural area around the capital city of Slovenia, 2012. *Epidemiol Infect*. 2014;142:2662-66
13. Cornut J, De Respinois S, Tonolla M, et al. Rapid characterization of aquatic hyphomycetes by matrix-assisted laser desorption/ionization time-of-flight mass spectrometry. *Mycologia*. 2019;111:177-89
14. de Respinois S, Tonollia M, Pranghofer S, et al. Identification of dermatophytes by matrix-assisted laser desorption/ionization time-of-flight mass spectrometry. *Med Mycol*. 2013;51:514-21
15. Lau AF, Walchak RC, Miller HB, et al. Multicenter study demonstrates standardization requirements for mold identification by MALDI-TOF MS. *Front Microbiol*. 2019;10:2098
16. Hariu M, Watanabe Y, Oikawa N, et al. Usefulness of matrix-assisted laser desorption ionization time-of-flight mass spectrometry to identify pathogens, including polymicrobial samples, directly from blood culture broths. *Infect Drug Resist*. 2017;10:115-20
17. Hariu M, Watanabe Y, Oikawa N, et al. Evaluation of blood culture broths with lysis buffer to directly identify specific pathogens by matrix-assisted laser desorption/ionization time-of-flight mass spectrometry methods. *Infect Drug Resist*. 2018;11:1573-79
18. Seki M, Hariu M, Watanabe Y. Critical points of direct pathogens identification by matrix-assisted laser desorption/ionization time-of-flight mass spectrometry methods. *J Infect Dis Ther*. 2020;8:1-4

Conclusions

In conclusion, a case of household infection of *M. canis* in a child who fed abandoned cats was described. *M. canis* should be carefully investigated and treated as a causative pathogen of dermatophytosis secondary to household infection. In the present case, MALDI-TOF MS was shown to be a very effective tool to identify the infection route to confirm the transmission of a pathological fungus among the infected patients and help select appropriate treatment for the affected family members.

Conflict of Interest

None.