

Systemic infection due to subcutaneous implantable cardioverter-defibrillator implantation: Importance of early recognition and treatment of device pocket-related complications



Patrick M. Looser, MD, Layth Saleh, MD, George Thomas, MD, Jim W. Cheung, MD, FHRS

From the Division of Cardiology, Department of Medicine, Weill Cornell Medical College, New York, New York.

Introduction

Implantable cardioverter-defibrillators (ICDs) are a mainstay of therapy for patients at risk for recurrent life-threatening ventricular arrhythmias. As increasing numbers of patients with ICDs are encountered in clinical practice, the rising morbidity, mortality, and costs linked to cardiac implantable electronic devices have been recognized.^{1,2} Without the presence of indwelling transvenous leads, subcutaneous ICDs (S-ICDs) offer a theoretical advantage over transvenous ICDs (TV-ICDs) by lowering the risk of systemic infection and endocarditis. In 2 large registry studies, rates of S-ICD-related infections over 2-year follow-up were 1.7% and 4%.^{3,4} No cases of systemic infection were reported in either study. Here, we report 2 separate cases of systemic infection associated with S-ICDs referred to our institution for further management within a 3-month period.

Case 1

A 55-year-old man with a history of ischemic cardiomyopathy with a left ventricular ejection fraction of 30%–35%, status post coronary artery bypass grafting, insulin-dependent diabetes mellitus, and end-stage renal disease (ESRD) on hemodialysis underwent S-ICD implantation at an outside institution for primary prevention ICD therapy. Perioperative intravenous vancomycin and cefazolin and postoperative oral cephalexin were given at the time of his procedure. He developed a postoperative pocket hematoma. During his follow-up 2 weeks later, he had continued swelling with no drainage. He was scheduled for continued

follow-up but was not seen until 7 months later when he noted wound dehiscence with purulent discharge. He also developed left eye pain, blurry vision, and conjunctival erythema. He returned to his implanting institution where he underwent successful S-ICD system explantation with pocket washout and packing. Wound cultures were positive for methicillin-resistant *Staphylococcus aureus*, and he was treated with vancomycin. Blood cultures were negative. Transthoracic and transesophageal echocardiograms did not demonstrate valvular vegetations. He presented to our institution with persistent eye symptoms. A slit lamp examination revealed a white mass extending through the retina into the vitreous humor consistent with bacterial or fungal endophthalmitis. Initially, he was given intravitreal vancomycin and ceftazidime and intravenous voriconazole. Visual acuity at that time was OS 20/200, and a repeat slit lamp examination showed local vitritis overlying a white retinal lesion. Despite the absence of vitreous cultures, it was felt that the patient likely had methicillin-resistant *S aureus* endophthalmitis. Voriconazole and ceftazidime were discontinued. Intravitreal antibiotics were changed to topical antibiotics, and his vision improved to OS 20/60. He was discharged on a 6-week course of vancomycin administered at hemodialysis. After his antibiotic course, he had return to normal OS 20/20 vision with normal slit lamp examination.

Case 2

A 35-year-old woman with a history of ischemic cardiomyopathy with a left ventricular ejection fraction of 34%, insulin-dependent diabetes mellitus, ESRD on hemodialysis, and ventricular tachycardia underwent S-ICD implantation at an outside institution for secondary prevention ICD therapy. The device was implanted in a submuscular pocket under the serratus anterior. The patient was treated with aspirin and clopidogrel at the time of the procedure. Perioperative intravenous cefazolin and postoperative oral cephalexin were given at the time of her procedure. During her follow-up visit

KEYWORDS Subcutaneous implantable cardioverter-defibrillator; Systemic infection; Hematoma (*Heart Rhythm Case Reports* 2017;3:40–42)

Dr Cheung has received speaker honoraria from Biotronik and Medtronic, research grant support from Biotronik, and fellowship grant support from Biotronik, Boston Scientific, and Medtronic. Dr Thomas has received research grant support from Biotronik. **Address reprint requests and correspondence:** Dr Jim W. Cheung, Division of Cardiology, Department of Medicine, Weill Cornell Medical College, 520 E 70th St, Starr 4, New York, NY 10021. E-mail address: jac9029@med.cornell.edu.

KEY TEACHING POINTS

- This case report describes 2 cases of systemic infections due to subcutaneous implantable cardioverter-defibrillator (S-ICD) implantation.
- Both cases involved patients with end-stage renal disease on hemodialysis and diabetes mellitus who had pocket swelling soon after device implantation.
- These cases highlight the importance of vigilance for pocket-related complications soon after S-ICD implantation. Early intervention for pocket hematomas and infection may prevent progression to systemic infection.

2 weeks after device implantation, the patient noted pain and swelling. This was managed with observation, with a plan for a follow-up visit if symptoms worsened. The swelling and pain improved but never completely resolved. Four months later, she presented to our institution with progressive pain and swelling around her device as well as by her subxiphoid and sub-suprasternal notch incisions. On physical examination, swelling and tenderness around the device pocket were noted. In addition, superficial ulceration with purulent discharge was noted at the prior subxiphoid incision site (Figure 1). Warmth was palpated along the entire tract of the S-ICD lead from the device pocket and along the sternal region. Empiric vancomycin and piperacillin-tazobactam were administered. Blood cultures drawn before the initiation of antibiotics were positive for methicillin-sensitive *S aureus*. The antibiotic regimen was changed to nafcillin. A computed tomographic scan of the chest demonstrated a rim-enhancing fluid collection (11.4 × 5.1 × 10.1 cm) surrounding the S-ICD generator suspicious for abscess with inflammatory changes tracking along the ICD lead (Figure 2). Transesophageal echocardiography did not reveal any valvular vegetations. She underwent device extraction,

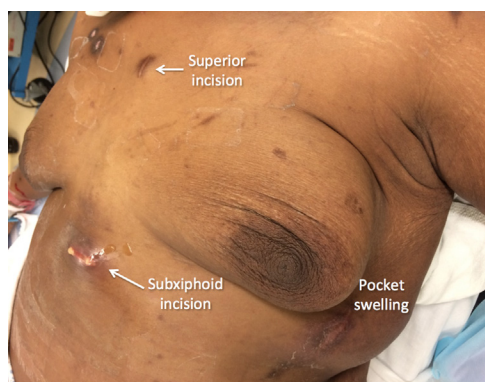


Figure 1 Physical appearance of the chest before subcutaneous implantable cardioverter-defibrillator system removal. Purulent drainage from the subxiphoid incision is shown. There is moderate swelling by the device pocket. The sub-suprasternal notch (superior) incision is intact, but erythema is noted.

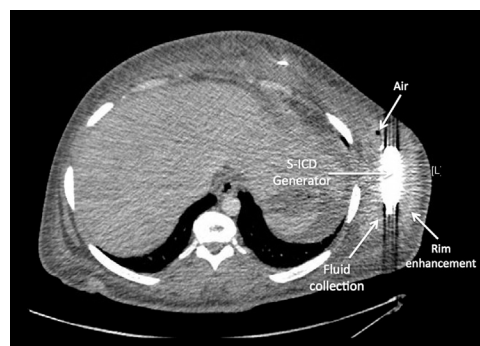


Figure 2 Computed tomographic scan of the chest showing device pocket infection. A rim-enhancing fluid collection (11.4 × 5.1 × 10.1 cm) surrounding the subcutaneous implantable cardioverter-defibrillator generator is shown. A small pocket of air within the fluid collection is also shown. S-ICD = subcutaneous implantable cardioverter-defibrillator.

debridement, and pocket irrigation with plastic surgery assistance. More than 200 cm³ of purulent fluid was removed and sent for culture, which eventually grew out methicillin-sensitive *S aureus* (Figure 3). All 3 wounds were left open and packed. After a week of adequate healing, a wound vacuum dressing was placed on the prior pocket incision. The patient was discharged to a rehabilitation center with a wearable external defibrillator (LifeVest, Zoll Medical, Chelmsford, MA) on 4 weeks of nafcillin therapy.

Discussion

Here, we present 2 patients who developed systemic infections as a complication of S-ICD implantation. One patient had bacterial endophthalmitis due to transient hematogenous spread from his ICD pocket infection, and another had documented bacteremia. Both patients had risk factors for device infection, including ESRD requiring hemodialysis as well as insulin-dependent diabetes mellitus. In addition, both patients had swelling of their device pocket soon after implantation consistent with pocket hematoma formation and presented with systemic infection more than 3 months after device implantation.

Without transvenous leads, S-ICDs offer potential advantages over TV-ICD with respect to possibly decreased risks of intravascular and systemic infections, lead dislodgment, and transvenous lead implantation-associated complications

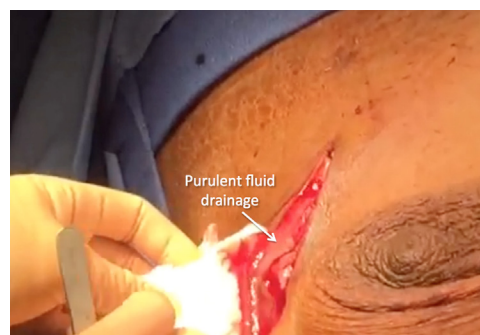

Figure 3 Still image from the video recording during device explantation. More than 200 cm³ of purulent fluid was drained upon incision of the device pocket site.

such as pneumothorax and cardiac perforation. Rates of S-ICD implantation–related infections have been reported in the range of 1.7%–4.1%.^{3,4} In comparison, rates of TV-ICD infection between 0.6% and 1.7% over variable follow-up have been reported.^{5–8} In the absence of prospective head-to-head study data, comparisons of S-ICD and TV-ICD infection rates using prospective and retrospective cohort data are limited by differences in implantation techniques, use of antibiotic prophylaxis, patient characteristics, and follow-up time.

We have shown that S-ICD pocket infections can progress to systemic infection. Both patients in our report had risk factors of pocket hematoma, ESRD, and diabetes that predisposed them for systemic infection. A meta-analysis on transvenous cardiac implantable electronic device infections found that pocket hematoma, ESRD, and diabetes were associated with 8.5-fold, 8.7-fold, and 2-fold increases in infection rates, respectively.⁹ The confluence of all these factors likely contributed to the systemic progression of infection in our 2 patients. In case 2, the patient underwent device implantation receiving dual antiplatelet therapy, which may have increased her likelihood of developing a hematoma. Moreover, she had a subserratus S-ICD implant, which may have led to a delay in the recognition of pocket hematoma and infection given its deep location. The cases raise the question of whether early intervention with hematoma evacuation could have prevented progression to pocket infection with subsequent systemic involvement. In our cases, the timing of diagnosis of systemic infection was 4 and 7 months after S-ICD implantation, which reflected the prolonged duration of indolent pocket infection before the onset of systemic infection. Given the clear link between pocket hematomas and the risk of device infection, strategies to reduce hematoma formation are critical.¹⁰ Given the size and location of the device pocket required for S-ICDs, careful attention to hemostasis is mandatory, especially when using a submuscular approach. In addition, in case 2, avoidance of clopidogrel (which was administered for a remote history of coronary stents) may have helped prevent pocket hematoma.

Of note, both patients in this report had ESRD requiring hemodialysis. The relationship between systemic infections in patients on hemodialysis with TV-ICDs has been well established.^{11,12} Given the absence of transvenous leads, S-ICDs have been suggested to be a preferable alternative to TV-ICDs for patients on hemodialysis on the basis of limited observational study data.¹³ It remains to be seen whether S-ICDs would have lower long-term infection rates in comparison to TV-ICDs in this high-risk population.

As more S-ICDs are implanted worldwide, especially in younger patients and patients at higher risk for intravascular infection, such as patients with ESRD, recognition of the range of complications associated with S-ICDs is of paramount importance. Earlier intervention for pocket hematomas found in the 2 patients described in this report may have led to

the avoidance of systemic infection. Although several reports from S-ICD registries have reported success with conservative management of suspected S-ICD infection without device explantation,^{14,15} we believe that such an approach should be considered with caution, especially in patients with significant comorbidities such as ESRD. Our report highlights the fact that the absence of transvenous leads does not eliminate the risk of systemic infection from S-ICD implantation. The results of prospective randomized trials will be critical for assessing the superiority of S-ICDs in reducing the long-term risks of serious systemic infection. Improvements in operative technique, in operator experience, and in the recognition and management of S-ICD implantation–related complications may result in better long-term outcomes.

References

- Sohail MR, Henrikson CA, Braid-Forbes MJ, Forbes KF, Lerner DJ. Mortality and cost associated with cardiovascular implantable electronic device infections. *Arch Int Med* 2011;171:1821–1828.
- Rizwan Sohail M, Henrikson CA, Jo Braid-Forbes M, Forbes KF, Lerner DJ. Increased long-term mortality in patients with cardiovascular implantable electronic device infections. *Pacing Clin Electrophysiol* 2015;38:231–239.
- Burke MC, Gold MR, Knight BP, et al. Safety and efficacy of the totally subcutaneous implantable defibrillator: 2-year results from a pooled analysis of the IDE Study and Effortless Registry. *J Am Coll Cardiol* 2015;65:1605–1615.
- Brouwer TFDA, Olde Nordkamp LRA, Kooiman KM, de Groot JR, Wilde AAM, Knops RE. Surgical management of implantation related complications of the subcutaneous implantable cardiac defibrillator. *JACC Electrophysiol* 2016;2: 89–96.
- Klug D, Wallet F, Marquie C, Polge AS, Fayad G, Courcol R, Kacet S. Pacemaker or implantable cardioverter-defibrillator related infection prospective evaluation of diagnosis criteria and of an algorithm of management. *Circulation* 2007;116:348–348.
- Krahn AD, Lee DS, Birnie D, et al. Predictors of short-term complications after implantable cardioverter-defibrillator replacement results from the Ontario ICD Database. *Circ Arrhythmia Electrophysiol* 2011;4:U136–U153.
- Prutkin JM, Reynolds MR, Bao HK, Curtis JP, Al-Khatib SM, Aggarwal S, Uslan DZ. Rates of and factors associated with infection in 200 909 Medicare implantable cardioverter-defibrillator implants: results from the National Cardiovascular Data Registry. *Circulation* 2014;130:1037–1043.
- Gupta N, Kiley M, Anthony F, Young C, Brar S, Kwaku K. Multi-Center, Community-Based Cardiac Implantable Electronic Devices Registry: population, device utilization, and outcomes. *J Am Heart Assoc* 2016;5:e002798.
- Polyzos KA, Konstantelias AA, Falagas ME. Risk factors for cardiac implantable electronic device infection: a systematic review and meta-analysis. *Europace* 2015;17:767–777.
- Essebag V, Verma A, Healey JS, et al. Clinically significant pocket hematoma increases long-term risk of device infection: BRUISE CONTROL INFECTION Study. *J Am Coll Cardiol* 2016;67:1300–1308.
- Asif A, Salman L, Lopera G, Haqqie SS, Carrillo R. Transvenous cardiac implantable electronic devices and hemodialysis catheters: recommendations to curtail a potentially lethal combination. *Semin Dial* 2012;25:582–586.
- Tompkins C, McLean R, Cheng A, et al. End-stage renal disease predicts complications in pacemaker and ICD implants. *J Cardiovasc Electrophysiol* 2011;22:1099–1104.
- Koman E, Gupta A, Subzposh F, Saltzman H, Kutalek SP. Outcomes of subcutaneous implantable cardioverter-defibrillator implantation in patients on hemodialysis. *J Interv Card Electrophysiol* 2016;45:219–223.
- Lambiase PD, Barr C, Theuns DA, et al. Worldwide experience with a totally subcutaneous implantable defibrillator: early results from the EFFORTLESS S-ICD Registry. *Eur Heart J* 2014;35:1657–1665.
- Lambiase PD, Gold MR, Hood M, Boersma L, Theuns DA, Burke MC, Weiss R, Russo AM, Kaab S, Knight BP. Evaluation of subcutaneous ICD early performance in hypertrophic cardiomyopathy from the pooled EFFORTLESS and IDE cohorts. *Heart Rhythm* 2016;13:1066–1074.