

## CASE REPORT

# A novel imaging technique to evaluate airflow characteristics in the upper airway of an obstructive sleep apnea patient

Hui Chen<sup>1,2</sup>, Ghizlane Aarab<sup>2</sup>, Jian-wei Liu<sup>3</sup>, Yong-liang Yu<sup>4</sup>, Jing Guo<sup>3</sup>, Paul F. van der Stelt<sup>1</sup> & Frank Lobbezoo<sup>2</sup>

<sup>1</sup>Department of Oral Radiology, Academic Centre for Dentistry Amsterdam (ACTA), University of Amsterdam and VU University Amsterdam, Amsterdam, The Netherlands

<sup>2</sup>Department of Oral Kinesiology, Academic Centre for Dentistry Amsterdam (ACTA), MOVE Research Institute Amsterdam, University of Amsterdam and VU University Amsterdam, Amsterdam, The Netherlands

<sup>3</sup>Department of Orthodontics, School of Dentistry, Shandong University, Jinan, China

<sup>4</sup>Aerodynamics Laboratory, University of Chinese Academy of Science, Beijing, China

### Correspondence

Jing Guo, Department of Orthodontics, School of Dentistry, Shandong University, 44 Wenhua West Rd, Lixia, Jinan, Shandong, China.  
Tel: +86 0531 8838 2070; Fax: +86 0531 8838 2923; E-mail: guojing@sdu.edu.cn

### Funding Information

Scientific and technological project in Shandong Province, China (No.2012G0021834).

Received: 7 April 2016; Revised: 26 August 2016; Accepted: 8 September 2016

**Clinical Case Reports 2017; 5(7): 1084–1087**

doi: 10.1002/ccr3.716

The patient was recruited from the Department of Orthodontics, School of Dentistry, Shandong University, Jinan, China. The particle image velocimetry (PIV) was carried out at Aerodynamics Laboratory, University of Chinese Academy of Science, Beijing, China.

## Introduction

Obstructive sleep apnea (OSA) is a sleep-related breathing disorder, often associated with a compromised upper airway space and an increase in upper airway collapsibility [1]. Excessive daytime sleepiness, snoring, and reduction in cognitive functions are among the common symptoms of OSA [2]. The consequences of OSA are increased cardiovascular morbidity, neurocognitive impairment, and overall mortality [2].

## Key Clinical Message

We report about a novel imaging technique for airflow analysis, particle image velocimetry (PIV), used in a moderate obstructive sleep apnea (OSA) patient. By measuring the airflow characteristics in the upper airway at different protrusion positions, the effect of mandibular advancement device (MAD) on OSA was further understood.

## Keywords

Computed tomography, mandibular advancement, obstructive sleep apnea, oral appliance, velocimetry.

Mandibular advancement devices (MADs) have been recommended as a primary treatment option in mild-to-moderate OSA patients and in severe OSA patients who do not tolerate continuous positive airway pressure (CPAP) [3]. However, there is no definitive conclusion on the relation between the mandibular protrusion position and the improvement of the OSA symptoms. Ferguson et al. suggested that a large mandibular protrusion will lead to a large decrease in OSA events [4], while Aarab et al. found no significant difference in efficacy

between MADs set at 50% protrusion position and at 75% protrusion position [5]. In this case report, it is hypothesized that the airflow characteristics in the upper airway are different at different protrusion positions, viz, the larger the protrusion position, the better the ventilation of the upper airway. Particle image velocimetry (PIV) is a novel imaging technique, which can show the airflow characteristics in the upper airway. By investigating the airflow characteristics in the upper airway at different protrusion positions using PIV, the effect of MAD therapy on OSA can be further understood from the perspective of aerodynamics.

The aim of this case report was to evaluate the airflow characteristics in the upper airway of an OSA patient at different protrusion positions using PIV.

## Case Report

A 35-year-old male OSA patient with no medical history (body mass index = 25.4 kg/m<sup>2</sup>), whose main complaint was snoring at night, was treated with an adjustable MAD (Erkodent, Baden-Württemberg, Germany). There was no change in his weight and sleep habit during the treatment. Based on polysomnography (PSG) at baseline, apnea occurred during both REM sleep and non-REM sleep. The total apnea-hypopnea index (AHI) was 17 events/h, supine AHI was 28.7 events/h, and the oxygen desaturation index (ODI) was 4.9. Epworth Sleepiness Scale (ESS) score was 11. Computed tomography (Discovery CT 750, General Electric Healthcare, Milwaukee, USA) scans were taken both at baseline (without the MAD in situ) and with the MAD in situ at 50% and 75% of the maximal protrusion positions, while the patient was awake during free-breathing. The exposure settings were 120 kV, 30 mA, 0.516 pitch. Based on the CT images, three transparent air-filled acrylic upper airway models from the hard palate plane to the vocal cord plane were made by rapid prototyping as follows: (1) The solid upper airway models were based on one sagittal slice of the CT images at the midsagittal plane. This slice was expanded to a width of 10 mm to be a three-dimensional (3D) model; (2) then, these solid models were adjusted on the platform of a vacuum pressure molding machine (Biostar, Scheu-Dental, Iserlohn, Germany) and coated with a transparent acrylic sheet; (3) after the acrylic was hardened, the solid models were removed and the transparent acrylic models of the upper airway were created. Subsequently, airflow characteristics in these three upper airway models were visualized separately by PIV using the following procedure: (1) Spherical glass microparticles with a diameter of 0.5–5 μm were placed in the flow field (water) as tracing particles; (2) the rate of the flow (water) was set at 103 mL/sec, corresponding to an

airflow rate of 125 mL/sec [6]; (3) the trajectory of particles in the water was recorded by taking two photos of the upper airway models shortly after each other and exported to an image processing device; (4) from the known time difference and the measured displacement of the microparticles, the velocity is calculated [7]. Based on the velocity field and the formula,

$$\vec{\omega} = \nabla \times \vec{u}$$

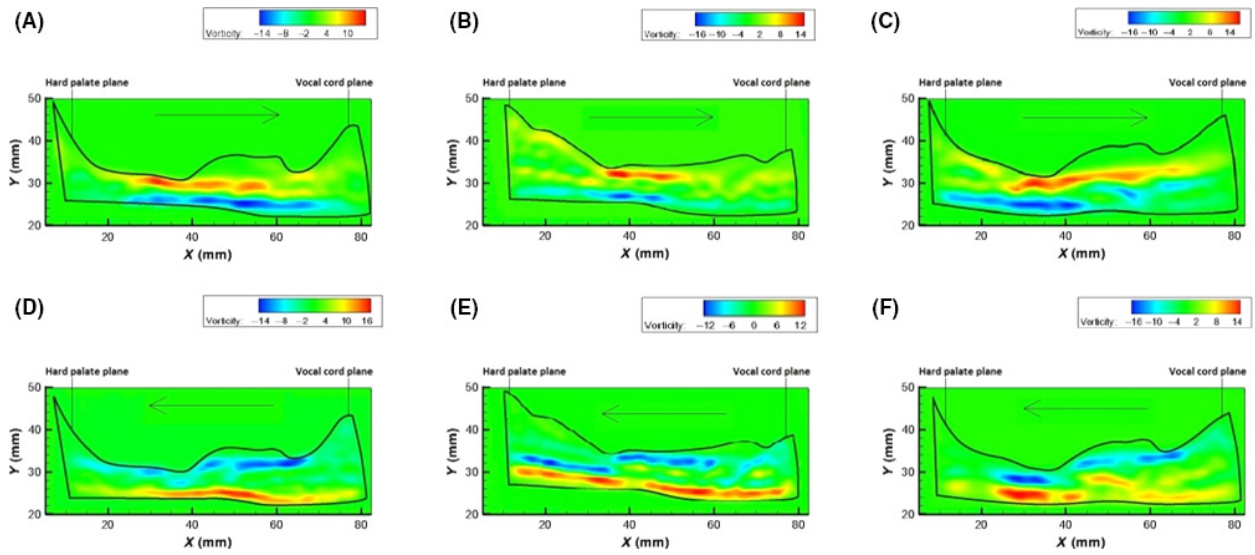
where  $\vec{\omega}$  is the vorticity,  $\nabla$  is the del operator, and  $\vec{u}$  is the velocity, the vorticity, which indicates the amount of turbulence in a fluid, is calculated. The inspiration phase is mimicked by allowing the flow (water) going through from the hard palate plane to the vocal cord plane, while the expiration phase is mimicked by allowing the flow (water) going through from the vocal cord plane to the hard palate plane (Fig. 1).

For this patient, the funnel-like upper airway at baseline was gradually changed into a cylinder-like one at 75% protrusion position. The airflow characteristics (vorticity profiles) in the upper airway of this OSA patient at different protrusion positions were shown in Figure 1. During inspiration, from baseline to 50% protrusion position, the maximum vorticity decreased from 16 to 14 per sec, while from 50 to 75% protrusion position, it remained the same (Fig. 2). During expiration, from baseline to 50% protrusion position, the maximum vorticity decreased from 16 to 12 per sec, and from 50 to 75% protrusion position, it increased from 12 to 14 per sec (Fig. 2). The clinical record of this patient was used to determine whether there is an improvement of the patient's symptoms. With the MAD in situ at 50 and 75% protrusion position, the main complaint of this patient, viz., snoring, was improved. However, with the MAD in situ at 75% protrusion position, this patient reported some side effects, such as tenderness in the temporomandibular joint region upon awakening. As his main sleep apnea symptom was improved to an acceptable level at 50% protrusion position, he was prescribed the MAD at 50% protrusion position. This patient was followed up 2 years after treatment by filling the ESS questionnaire, and his ESS score was 6.

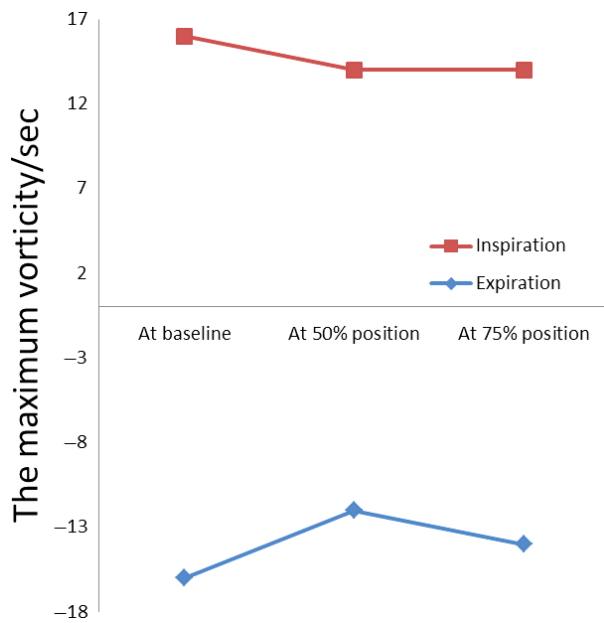
## Discussion

In our study, PIV was used to evaluate airflow characteristics (vorticity profiles) in the upper airway between the hard palate plane and the vocal cord plane at different mandibular protrusion positions.

For this patient, the funnel-like upper airway at baseline gradually changed into a cylinder-like one at 75% protrusion position. Compared with the cylinder-like upper airway, resistance of the funnel-like upper airway



**Figure 1.** Vorticity field of the upper airway models at baseline during inspiration (A), at 50% protrusion position during inspiration (B), and at 75% protrusion position during inspiration (C). Vorticity field of the upper airway models at baseline during expiration (D), at 50% protrusion position during expiration (E), and at 75% protrusion position during expiration (F). The arrows show the direction of the flow: → inspiration; ← expiration. X-axis: length of the model; Y-axis: width of the model.



**Figure 2.** The maximum vorticity in the upper airway models during inspiration and expiration at three different protrusion positions.

was greater, and more turbulence, quantified by the maximum vorticity, was observed (Fig. 1). The turbulence increases the air pressure on the upper airway wall, which could cause tissue edema [8]. Besides, it is hypothesized that as tissues surrounding the upper airway are exposed to the abnormal airflow, such as high negative inspiratory

pressure, in the long term, the anatomy of these tissues may change, for example, enlargement of the tongue or the soft palate. These adaptive changes make the upper airway narrower, which is unfavorable for air ventilation and causes a predisposition to OSA.

Vorticity is a mathematical concept used in fluid dynamics to describe the amount of turbulence in a fluid, which is equivalent to the curl of the fluid velocity [9]. The location of the maximum vorticity always occurs near the walls of the models and accompanies flow separations caused by sudden variations of the cross-sectional area perpendicular to the direction of the airflow. For OSA patients, the location of the maximum vorticity is the site where the axial cross-sectional area of upper airway changes significantly. Besides, vorticity is also a way to show the ventilation of the model, and by analyzing the distribution of vorticity contours, the ventilation of the upper airway can be determined in OSA patients [10]. During respiration, the maximum vorticity of the airflow was smaller with the MAD at 50% protrusion position in situ than without the MAD in situ, which indicates an improvement in ventilation of the upper airway with a MAD in situ. Compared to 50% protrusion position, the maximum vorticity at 75% protrusion position did not decrease during inspiration and it even increased during expiration. Therefore, the ventilation of the upper airway did not improve further (Fig. 2). Besides, the symptoms of this patient were improved at both 50 and 75% protrusion position, but this patient

reported more side effects with the MAD at 75% protrusion position in situ. These results corroborate the findings of a previous study by Aarab *et al.* that there was no significant difference between the MAD set at 50% of the maximal protrusion and 75% of the maximal protrusion in the reduction of the apnea–hypopnea indices [5].

Only without the MAD in situ, a polysomnography (PSG) of this patient was recorded, and not with the MAD in situ at 50% and 75% protrusion positions, which would have provided stronger evidence for the clinical application of this novel imaging technique. However, the patient reported improvement of the OSA symptoms with the MAD at 50 and 75% protrusion positions, which is consistent with the outcome of the PIV analysis. In this case report, there is a high radiation dose from the CT scans. For future study, it is recommended to use other imaging modalities such as cone beam computed tomography which has relatively lower radiation dose along with adequate contrast between the soft tissue and empty space to show the upper airway. The upper airway model used in the PIV analysis is made of rigid acrylic, which is different from the real upper airway. For future studies, it is suggested to set up upper airway models using specific materials that could mimic more closely the behavior of the upper airway. The upper airway is a complex 3D structure, and its airflow property is intricate. Another limitation of this case report is that only the airflow characteristics on the midsagittal plane of the upper airway were investigated. Modeling airflow properties within the complex 3D upper airway would require rather extensive computing resources, which could be incorporated in a future study. Notwithstanding those limitations, PIV is a promising tool to visualize the upper airway resistance, which is important in further understanding both the pathogenesis of OSA and the working mechanism of the MAD. For example, in clinical trials, this technique can be used to investigate the airflow characteristics between OSA patients and their controls or to compare the change of the airflow characteristic during different treatment modalities in OSA patients.

## Conclusion

The ventilation of the upper airway of this OSA patient was improved most with the MAD in situ at 50% protrusion position. PIV is a promising tool in evaluating

airflow characteristics in the upper airway of the OSA patients.

## Conflict of Interest

None declared.

## References

- Guilleminault, C., A. Tilkian, and W. C. Dement. 1976. The sleep apnea syndromes. *Annu. Rev. Med.* 27:465–484.
- Aarab, G., F. Lobbezoo, H. L. Hamburger, and M. Naeije. 2011. Oral appliance therapy versus nasal continuous positive airway pressure in obstructive sleep apnea: a randomized, placebo-controlled trial. *Respiration*. 81:411–419.
- Sutherland, K., S. A. Deane, A. S. Chan, R. J. Schwab, A. T. Ng, M. A. Darendeliler, *et al.* 2011. Comparative effects of two oral appliances on upper airway structure in obstructive sleep apnea. *Sleep*. 34:469–477.
- Ferguson, K. A., R. Cartwright, R. Rogers, and W. Schmidt-Nowara. 2006. Oral appliances for snoring and obstructive sleep apnea: a review. *Sleep* 29:244–262.
- Aarab, G., F. Lobbezoo, H. L. Hamburger, and M. Naeije. 2010. Effects of an oral appliance with different mandibular protrusion positions at a constant vertical dimension on obstructive sleep apnea. *Clin. Oral. Investig.* 14:339–345.
- Kim, J. K., J. H. Yoon, C. H. Kim, T. W. Nam, D. B. Shim, and H. A. Shin. 2006. Particle image velocimetry measurements for the study of nasal airflow. *Acta Otolaryngol.* 126:282–287.
- Mylavarapu, G., S. Murugappan, M. Mihaescu, M. Kalra, S. Khosla, and E. Gutmark. 2009. Validation of computational fluid dynamics methodology used for human upper airway flow simulations. *J. Biomech.* 42:1553–1559.
- Strollo, P. J. Jr, and R. M. Rogers. 1996. Obstructive sleep apnea. *N. Engl. J. Med.* 334:99–104.
- Nagels, M. A., and J. E. Cater. 2009. Large eddy simulation of high frequency oscillating flow in an asymmetric branching airway model. *Med. Eng. Phys.* 31:1148–1153.
- Ishikawa, S., T. Nakayama, M. Watanabe, and T. Matsuzawa. 2006. Visualization of flow resistance in physiological nasal respiration: analysis of velocity and vorticities using numerical simulation. *Arch. Otolaryngol. Head Neck Surg.* 132:1203–1209.