



Flow diverter embolization device for endovascular treatment of ruptured blister and wide necked very small aneurysms



Mohammad Ghorbani^{a,*}, Christoph J. Griessenauer^{b,c}, Christoph Wipplinger^d, Maziar Azar^e, Hamidreza Shojaei^a, Karan Bavand^a, Darya Khosravi^f

^a Division of Vascular and Endovascular Neurosurgery, Firoozgar Hospital, Iran University of Medical Sciences, Tehran, Iran

^b Department of Neurosurgery, Geisinger Health System, Danville, PA, USA

^c Research Institute of Neurointervention, Paracelsus Medical University, Salzburg, Austria

^d Department of Neurological Surgery, Weill Cornell Medicine, New York, NY, USA

^e Department of Neurosurgery, School of Medicine, Rasoul-e-Akram Hospital, Iran University of Medical Sciences, Tehran, Iran

^f Razi Hospital, Tehran University of Medical Sciences, Iran

ARTICLE INFO

Keywords:

Neurology
Surgery
Medicine
Neurosurgery
Medical imaging
Radiology
Very small aneurysms
Blood blister aneurysms
Flow diverter devices

ABSTRACT

Purpose: Ruptured blood blisters (BBA) and very small, wide necked aneurysms (VSA) remain challenging lesions to treat due to their small size, wide necks, and thin, fragile walls. In the present study, we reviewed our experience with these aneurysms treated by flow diversion.

Methods: A total of 18 patients with hemorrhage due to a ruptured BBAs and VSAs, treated with flow diversion between July 2014 and March 2016 were included in this study. We analyzed clinical and radiographic outcomes.

Results: A total of 12 (66.7%) VSAs and 6 (33.3%) BBAs were treated with flow diversion. Fifteen (83.3%) and three (16.7%) aneurysms were located on the internal carotid artery and the basilar artery, respectively. On admission, a GCS score of 15 and WFNS grade 1 were found in 14 (77.7%) patients, 3 patients had an admission GCS of 13 and WFNS grade 2, one had an admission GCS of 8 and WFNS of 4. Fisher CT grades 2, 3, and 4 were observed in 11 (61.1%), 1 (5.6%), and 6 (33.3%) patients, respectively. Flow diversion was performed on average 5.6 days after onset of hemorrhage. 6 months post-intervention angiography showed complete obliteration of the aneurysms in all patients.

Conclusion: Our findings indicate that flow diversion in the acute and subacute phase of hemorrhage is a reliable treatment for reducing complications in patients with BBAs and VSAs. In patients with poor clinical presentation it might be reasonable to delay treatment until the first signs of recovery become apparent.

1. Introduction

A blood blister aneurysm (BBA) is a small, fragile, and broad-based outpouching of a non-branching segment of an intracranial artery. Histologically, these lesions are composed of a thin layer of adventitia covering a defect of the intima and media layers [1, 2, 3]. The pathophysiology of how BBAs form is unclear, but some evidence suggests that these aneurysms arise due to hemodynamic stress causing a focal injury to the vascular lumen. They comprise about 1–2% of all intracranial aneurysms [1, 4]. Although BBAs are most common in the supraclinoid portion of the internal carotid artery, they can occur on any intracranial artery [3, 5]. Since they are particularly fragile and small in size, diagnosis and treatment remain a serious challenge.

Very small aneurysms (VSAs) are defined as saccular aneurysms ≤ 3 mm in maximum diameter. Endovascular coil embolization of ruptured cerebral VSAs or BBAs is known to be 5 times more likely to result in procedure-related rupture compared to larger aneurysms [1, 6].

Apart from histopathological differences between, BBAs and wide necked VSAs, both face a similar treatment dilemma. While various open-surgical and endovascular techniques have been suggested as possible treatment, the incidence of intra-operative rupture, and subsequent risk for morbidity and mortality is still high [2, 6, 7]. Endoluminal reconstruction using flow diversion represents a recently suggested safe treatment alternative for both BBAs and wide necked VSA as it does not require direct manipulation of the aneurysm [8]. Current data on flow diversion for this application, however, are limited [2, 6, 8, 9]. Here, we

* Corresponding author.

E-mail address: ghorbani.m@iums.ac.ir (M. Ghorbani).

<https://doi.org/10.1016/j.heliyon.2019.e02241>

Received 24 April 2019; Received in revised form 3 June 2019; Accepted 2 August 2019

2405-8440/© 2019 Published by Elsevier Ltd. This is an open access article under the CC BY-NC-ND license (<http://creativecommons.org/licenses/by-nc-nd/4.0/>).

report a single center retrospective case series of flow diversion for BBAs and wide necked VSAs and evaluate safety and efficacy.

2. Materials & methods

Records of patients with blood blister aneurysms and wide necked VSAs presenting with subarachnoid hemorrhage (SAH) between July 2014 to March 2016 were retrospectively reviewed. Small, broad based, wide necked fragile aneurysms size ≤ 3 mm with similar properties as BBAs were considered as VSAs. Blood blister aneurysms or VSAs were identified as the source of bleeding in all included patients. WFNS grade, GCS score, and Fisher CT grading were recorded in all patients. The study was approved by the local institutional review board and investigations were conducted in accordance with the principles of the declaration of Helsinki.

2.1. Timing of treatment

Patients were treated within 48 h of the onset of the hemorrhage if they did not require an external ventricular drainage (EVD) and if their Fisher CT grade was favorable (Fisher grade 1 and 2). Patients with poor clinical presentation defined as GCS of ≤ 8 or Fisher grade >2 , were treated in a delayed fashion. This was also true for patients requiring an EVD followed by a permanent ventriculoperitoneal (VP) shunt after they had shown signs of recovery.

2.2. Procedural details

Flow diversion was performed under general anesthesia. Nasogastric or orogastric intubation was performed in all cases. A 90 cm femoral long sheath was introduced into the right or left common femoral artery up to the respective internal carotid or vertebral artery. Either a 5F or a 6F Navien (Medtronic, Irvine, CA, USA) intracranial support catheter was then inserted in the involved vessel proximal to the aneurysm using a hydrophilic guiding wire. A microcatheter, either a Marksman for Pipeline (Medtronic, Irvine, CA, USA) or Vasco 27 for Silk (Balt Extrusion, Montmorency, France), was navigated past the aneurysm and, the flow diverter was positioned in the aneurysmal segment of the affected artery. Surpass (Stryker, Neurovascular Fremont, CA, USA) was directly positioned over a microwire at the proper site without need for microcatheter access. Thereafter, 650 mg of aspirin were administered via a gastric tube. After 20 min as well as prior to stent deployment, a systemic anticoagulant was administered with an initial IV bolus of heparin 60–70 units/kg (maximum 5000 units) targeted to an activated clotting time of 250–300 s followed by an IV infusion of 1000 units/hr, and the aneurysm was covered with the flow diverter. After successful placement, all patients received 600 mg of Clopidogrel as loading doses through a nasogastric or orogastric tube, and continued with 75 mg of Clopidogrel and 325 mg of aspirin daily until 6 month and continued only with Clopidogrel to 1 year. Systemic heparin infusion was maintained for 24 h. Heparin infusion was monitored by repeated measurements of the activated partial thromboplastin time (aPTT) to keep it between 1.5 and 2.5 times of baseline. Follow-up digital subtraction angiography (DSA) was performed 6 months after the procedure. Outcomes were reviewed by an experienced endovascular neurosurgeon. Functional outcome was assessed using the GCS at discharge and modified Rankin Scale (mRS) at 6 months.

3. Results

Eighteen patients diagnosed with SAH from a blister or wide necked VSA were included in this study. This included 12 (66.7%) VSAs and 6 (33.3%) BBAs. The median age of patients was 52.5 years. Of the 18 patients, 10 (55.6%) were female and 8 (44.4%) were male. On admission, Glasgow Coma Scale (GCS), World Federation of Neurosurgery (WFNS) grading and Fisher CT-Score were evaluated. A GCS score of 15

and WFNS grade 1 were found in 14 (77.7%) patients, 3 patients had GCS score of 13 and WFNS grade 2, and 1 patient had an admission GCS score of 8 and WFNS grade of 4 that was due to post SAH hydrocephalus and managed by EVD followed by permanent ventriculoperitoneal shunt. Of the 18 patients, 11 (61.1%) had a grade 2, 1 (5.6%) had a grade 3, and 6 (33.3%) had a grade 4 on the Fisher CT scale (Table 1). A total of 15 aneurysms (83.3%) were located on the ICA (all of them in the paraclinoid part), and 3 (17.7%) were located on the basilar artery (Figs. 1 and 2). The mean duration between the onset of SAH and the endovascular procedure was 5.61 ± 5.1 days (range 2–18 days). Two patients (11.1%) developed a hydrocephalus prior to endovascular treatment, 1 was treated with an EVD without the need of a permanent VP shunt, while the other required a permanent VP shunt. Both patients were successfully implanted with single flow diverters. Flow diversion was performed with a Pipeline embolization device (Medtronic, Irvine, CA, USA) in 11 (61.1%) patients, Surpass streamline (Stryker Neurovascular, Fremont, CA, USA) in 4 (22.2%) and SILK plus (Balt Extrusion, Montmorency, France) was used in 3 (16.7%) patients (Fig. 3). The type of flow diverter used was selected based on availability of the appropriate size. During hospitalization and follow-up, no complications requiring surgical or medical interventions were observed. At the 6 months follow-up visit no patient had new neurological deficits. Except for 1 patient (mRS = 2), all had an mRS score of 0 or 1. Follow-up DSA showed complete obliteration of the aneurysms in all patients at 6 months. No in-stent stenosis in the parent vessels was detected. There were no significant differences in functional outcome as assessed by GCS at discharge and mRS scores at 6 months.

4. Discussion

4.1. Anatomical considerations

Blood blister aneurysms are a rare subgroup of intracranial aneurysms that have aggressive behavior and limited treatment options [10]. These lesions are shallow outpouchings of non-branching arteries, commonly located in the distal ICAs. However, BBAs located in areas other than the distal ICA have been described more recently [11]. Blister-like aneurysms are dangerous lesions with greater re-rupture risk than saccular aneurysms [12, 13]. Within these lesions, the arterial wall is fragile and lacks the internal elastic lamina and media layers. Thus, these lesions impose considerable diagnostic and therapeutic challenges [2, 14].

Despite the number of surgical approaches that have been described for these type of aneurysms, the risk of intra-operative rupture is significantly elevated due to the small size, fragility, and broad base without an obvious neck [12, 15].

4.2. Technical considerations

Due to the aneurysm's wide neck and weak walls, patients with BBAs are poor candidates for conventional endovascular treatments such as coiling. Many attempts have been made to improve endovascular techniques for the treatment of blister aneurysms.

In a study by Ezaki et al. it was reported that despite successful placement of coils could be performed in one case of a blister aneurysm, follow-up evaluation indicated progressive growth and transformation into a saccular aneurysm [16]. Park et al. reported about seven patients with blister aneurysms who were treated with coil embolization. Subsequently, all patients in their study exhibited regrowth of the aneurysms [17]. McNeely et al. described a blister aneurysm that was treated with detachable coil embolization. In their study, follow-up angiography showed significant regrowth of the aneurysm [18].

Stent-assisted coiling is associated with a high risk of aneurysm rupture during either catheterization or subsequent coil placement [14, 19]. Sim et al. reported a case of blister aneurysm treated with stent-assisted coiling which showed progressive aneurysm growth during follow-up [20].

Table 1
Patient characteristics.

Case No.	Gender	Age	WFNS	Fisher CT	GCS at admission	Aneurysm type	Aneurysm size (mm)	Aneurysm location	Time to treatment (days)	Stent type	GCS at discharge	mRS at 6 months
1	Male	54	1	2	15	BBA	1.6	Anteromedial ICA	2	Pipeline	15	0
2	Male	58	1	2	15	VSA	2	Paraclinoid ICA	9	Surpass	15	1
3	Female	23	1	2	15	VSA	1.9	Paraclinoid ICA	3	Surpass	15	0
4	Female	49	1	2	15	BBA	1.3	Anteromedial ICA	2	Pipeline	15	0
5	Male	52	1	2	15	VSA	2.2	Paraclinoid ICA	5	Pipeline	15	1
6	Male	39	1	2	15	BBA	1.7	Anteromedial ICA	2	Silk plus	15	0
7	Male	59	1	2	15	VSA	2.8	Paraclinoid ICA	7	Silk plus	15	1
8	Female	64	1	2	15	VSA	2.2	Paraclinoid ICA	2	Surpass	15	0
9	Female	52	1	2	15	VSA	2.9	Basilar artery	2	Surpass	15	0
10	Female	50	1	2	15	VSA	2	Basilar artery	2	Pipeline	15	0
11	Female	54	1	2	15	VSA	2.3	Basilar artery	3	Pipeline	15	0
12	Male	28	1	4	15	BBA	1.9	Anteromedial ICA	2	Silk plus	15	1
13	Male	55	1	4	15	BBA	1.6	Anteromedial ICA	2	Pipeline	15	1
14	Female	44	1	4	15	VSA	2.2	Paraclinoid ICA	2	Pipeline	15	1
15	Male	60	4	3	8	BBA	1.3	Anteromedial ICA	18	Pipeline	14	2
16	Female	47	2	4	13	VSA	2.3	Paraclinoid ICA	14	Pipeline	15	0
17	Female	53	2	4	13	VSA	1.9	Paraclinoid ICA	11	Pipeline	15	1
18	Female	63	2	4	13	VSA	2.2	Paraclinoid ICA	13	Pipeline	15	1

GCS: Glasgow coma scale; WFNS: World Federation of Neurological Surgeons; Surpass: surpass streamline flow diverter device; Pipeline: Pipeline flow diverter device; Silk plus: Silk plus flow diverter device.

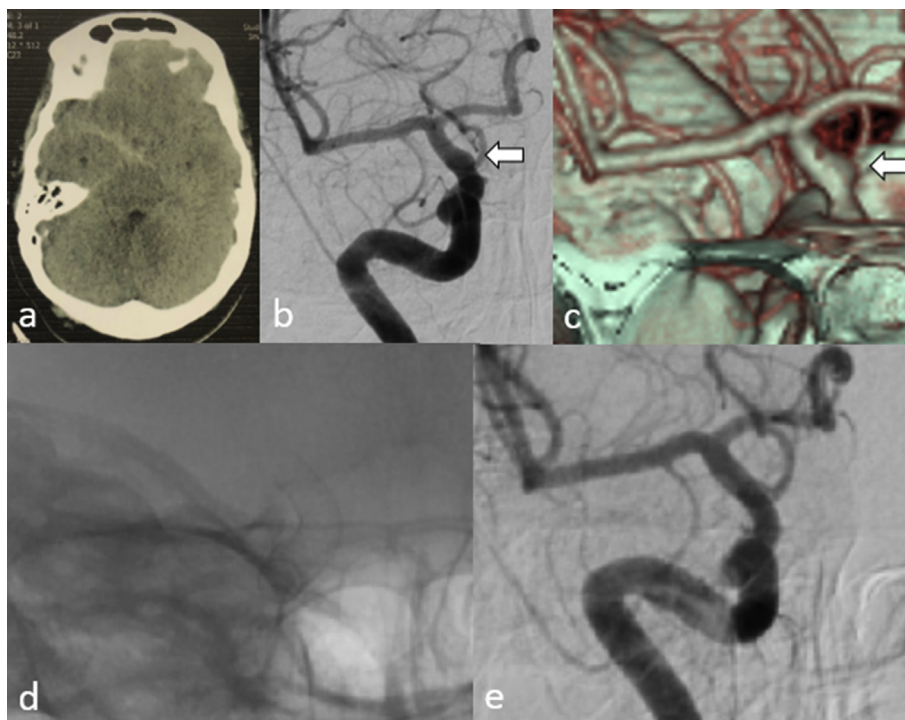


Fig. 1. Case 1. (a) Axial brain CT scan showing subarachnoid hemorrhage primarily in the right carotid cistern. (b & c) DSA and CTA showing a blood blister aneurysm (white arrows) on the anteromedial surface of the right internal carotid artery (1.6 mm). (d) A Pipeline flow diverter is placed to cover the aneurysm. (e) DSA after 6 months shows complete occlusion of the aneurysm.

4.3. Advantages of flow diversion

Flow diversion offers a new alternative for the treatment of aneurysm with difficult morphologies, including giant, wide-necked, fusiform, and blister types [21]. This technology has a significant impact on outcomes as it can redirect blood flow away from aneurysms and reconstruct the

parent vessel [11]. Currently, flow diverters seem to be the most promising technique for stabilizing the arterial wall and minimizing procedural trauma of fragile aneurysms [14]. In a study by Aydin et al., 11 patients with ruptured carotid blister aneurysm were treated with the SILK flow diverter. The procedures were successful in all cases, and control angiographies revealed a complete occlusion of aneurysms in 9

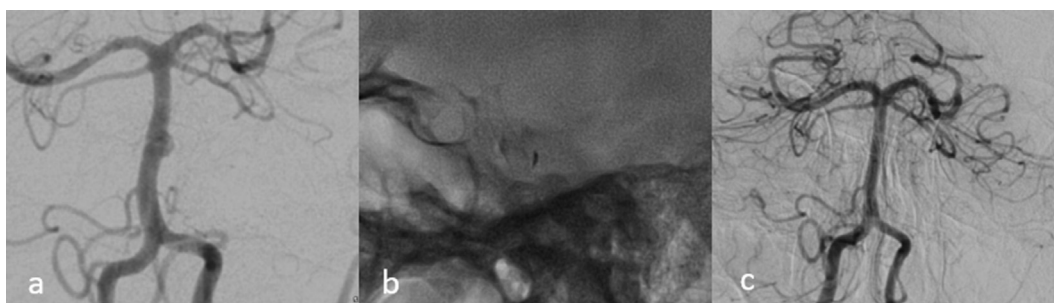


Fig. 2. Case 9. (a) Anteroposterior view of basilar artery shows a wide necked very small aneurysm (maximum diameter = 2.9 mm) on the midbasilar artery. (b) Unsubtracted images after Pipeline deployment showing the flow diverter covering the aneurysm and contrast stagnation in sac of the aneurysm. (c) DSA after 6 month shows complete occlusion of the aneurysm.

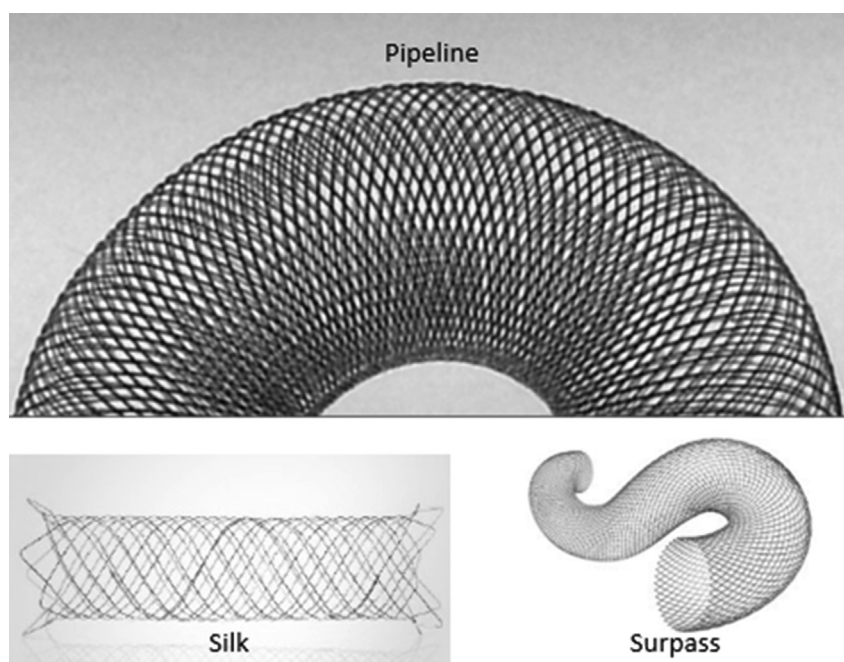


Fig. 3. Representative images of Pipeline, Silk, and Surpass flow diverters.

(82%) patients [2]. Also, we had a positive experience with FDDs for treatment of traumatic and iatrogenic internal carotid artery injuries showing that flow diversion is effective in healing vessel wall damages [22].

Although flow diverter implantation creates an immediate hemodynamic effect in the parent artery and aneurysmal sac, progressive thrombosis and complete occlusion of the aneurysm only occurs within weeks after the procedure [23]. During this ‘latency period’, there is a risk of re-rupture or re-bleeding [14]. The use of flow diverters is associated with favorable outcomes. However, dual antiplatelet requirement limits their application in ruptured aneurysms [10]. Rouchaud et al. performed a meta-analysis of BBAs and showed that flow diversion had a distinct advantage over endovascular reconstructive techniques (i.e. coiling, stenting or stent-assisted coiling), with lower retreatment rates, better mid- to long-term complete occlusion, with similar mid- to long term advantageous clinical outcomes [9].

4.4. Technical challenges of flow diverters

Even though the rupture of a blister aneurysm after treatment with a

single flow diverting stent has been reported [24], efficacy of single device deployment was been shown in a number of case series [9, 25, 26]. On the other hand, multiple overlapping flow diverters may not guarantee prevention of recurrent bleeding [27]. In addition, deployment of multiple flow diverters may increase the risk of thromboembolic events or occlusion of perforators or side branches such as the ophthalmic artery [25]. It will also increase procedure duration. As such, a single flow diverter is preferable unless there is persistent filling on follow-up or the aneurysm is covered incompletely, which did not occur in the present series. Whether flow diverters with higher mesh density like “Surpass” have a therapeutic advantage remains open to question and should be subject to further investigation.

4.5. Peri-procedural hemorrhage management

Invasive procedures such as EVDs or VP shunts for patients under dual antiplatelet therapy increase the risk of bleeding 8–9 times [23]. To date, no safe guidelines were established for the management of antiplatelet therapy in these patients. There are numerous reports of hemorrhagic complications due to antiplatelet therapy after endovascular procedures

[9, 28]. In the current study, despite the use of dual antiplatelet therapy, no patient had post-stenting hemorrhage. In a study by Tumialán et al., six patients with ruptured aneurysms were treated with endovascular procedures, which were associated with high hemorrhagic complication rates. The authors reported 6 hemorrhagic complications, of which 3 were fatal [29]. In our series, we ensured that all patients were in ideal clinical condition at the time of their flow diverter placement and did not require concomitant invasive procedures such as EVD placement. This approach caused up to 18 days delay to treatment in some cases. None of those patients experienced a re-bleed during that time.

4.6. Strategies for favorable functional outcomes

We achieved favorable results in all treated patients except for one (mRS = 2), demonstrating mRS scores of 0 or 1 in the latest clinical follow-up. In our opinion, this was due to ideal clinical conditions at the time of treatment as well as favorable vascular anatomy of the patients selected for FDD. All procedures were performed by neuro-interventionalists with extensive experience in flow diverter deployment. Moreover, we were highly selective in terms of timing and choice of the right treatment for each individual case. Complete obliteration of the aneurysm was also achieved in 100% of patients at 6 months. The utility of flow diverters was traditionally limited to patients with unruptured aneurysms. This limitation is most likely explained by the requirement of anticoagulant and antiplatelet drugs. The current study indicates that flow diverter use may be appropriate even in the acute or subacute phase of SAH if anticoagulants and antiplatelets are administered immediately after stenting and no other invasive procedures are indicated.

4.7. Limitations

The main limitation is the small sample size and the retrospective nature of the study. Outcome measures were reported from a single center, self-adjudicated, and not compared to a control group, which may invoke the risk of selection bias. Given the rarity of those lesions along with novel treatment technologies applied here, however, we believe this study is a welcome addition to the current literature. Also, we faced limitations regarding availability of sizes for the individual flow diverters requiring the use of 3 different flow diverters at various time points.

5. Conclusions

The current study indicates that flow diversion is a promising and safe treatment option in patients with BBAs and VSAs in the acute phase of SAH. In selected patients with poor clinical presentation, delaying the treatment until signs of recovery become apparent may be a reasonable strategy. In our study, careful selection of treatment choice and timing was associated with excellent clinical outcomes.

Declarations

Author contribution statement

Mohammad Ghorbani: Conceived and designed the experiments; Performed the experiments; Analyzed and interpreted the data; Wrote the paper.

Christoph J. Griessenauer, Karan Bavand: Conceived and designed the experiments; Contributed reagents, materials, analysis tools or data.

Christoph Wipplinger: Contributed reagents, materials, analysis tools or data; Wrote the paper.

Maziar Azar: Conceived and designed the experiments; Performed the experiments.

Hamidreza Shojaei: Analyzed and interpreted the data; Contributed reagents, materials, analysis tools or data.

Darya Khosravi: Analyzed and interpreted the data; Contributed reagents, materials, analysis tools or data; Wrote the paper.

Funding statement

This research did not receive any specific grant from funding agencies in the public, commercial, or not-for-profit sectors.

Competing interest statement

The authors declare no conflict of interest.

Additional information

No additional information is available for this paper.

References

- [1] F.H. Pahl, M.F. de Oliveira, MdQ. Teles Gomes, A.C. Capel Cardoso, J.M. Rotta, Blister-like aneurysms: report of successful surgical treatment of consecutive cases and review of the literature, *World Neurosurg.* 89 (2016) 376–381.
- [2] K. Aydin, A. Arat, S. Sencer, et al., Treatment of ruptured blood blister-like aneurysms with flow diverter SILK stents, *J. Neurointerventional Surg.* 7 (3) (2015) 202.
- [3] A.P. Mitha, R.F. Spetzler, Blister-like aneurysms: an enigma of cerebrovascular surgery, *World Neurosurg.* 74 (4-5) (2010) 444–445.
- [4] A. Kawashima, Y. Okada, T. Kawamata, H. Onda, O. Kubo, T. Hori, Successful treatment of a blood blister-like aneurysm of the internal carotid artery by trapping with a high-flow bypass, *J. Clin. Neurosci.* : official journal of the Neurosurgical Society of Australasia 15 (7) (2008) 797–800.
- [5] W.J. van Rooij, R.S. Bechan, J.P. Peluso, M. Sluzewski, Endovascular treatment of intracranial aneurysms in the flow diverter era: frequency of use and results in a consecutive series of 550 treatments in a single centre, *Interv. Neuroradiol. : journal of peritherapeutic neuroradiology, surgical procedures and related neurosciences* 20 (4) (2014) 428–435.
- [6] I. Ioannidis, S. Lalloo, R. Corkill, W. Kuker, J.V. Byrne, Endovascular treatment of very small intracranial aneurysms, *J. Neurosurg.* 112 (3) (2010) 551–556.
- [7] Y.W. Kim, I.S. Park, M.W. Baik, K.W. Jo, Endovascular treatment of blood blister-like aneurysms using multiple self-expanding stents, *J. Korean Neurosurg. Soc.* 49 (2) (2011) 116–119.
- [8] D. Zhu, Y. Yan, P. Zhao, et al., Safety and efficacy of flow diverter treatment for blood blister-like aneurysm: a systematic review and meta-analysis, *World Neurosurg.* 118 (2018) e79–e86.
- [9] A. Rouchaud, W. Brinjikji, H.J. Cloft, D.F. Kallmes, Endovascular treatment of ruptured blister-like aneurysms: a systematic review and meta-analysis with focus on deconstructive versus reconstructive and flow-diverter treatments, *Am. J. Neuroradiol.* 36 (12) (2015) 2331.
- [10] M.Y. Kalani, J.M. Zabramski, L.J. Kim, et al., Long-term follow-up of blister aneurysms of the internal carotid artery, *Neurosurgery* 73 (6) (2013) 1026–1033, discussion 1033.
- [11] S. Peschillo, M. Miscusi, A. Caporlingua, et al., Blister-like aneurysms in atypical locations: a single-center experience and comprehensive literature review, *World Neurosurg.* 84 (4) (2015) 1070–1079.
- [12] J.R. Gaughen Jr., D. Hasan, A.S. Dumont, M.E. Jensen, J. McKenzie, A.J. Evans, The efficacy of endovascular stenting in the treatment of supraclinoid internal carotid artery blister aneurysms using a stent-in-stent technique, *AJNR Am. J. Neuroradiol.* 31 (6) (2010) 1132–1138.
- [13] J. Song, S. Oh, M.J. Kim, et al., Endovascular treatment of ruptured blood blister-like aneurysms with multiple (>/=3) overlapping Enterprise stents and coiling, *Acta Neurochir.* 158 (4) (2016) 803–809.
- [14] J. Regelsberger, J. Matschke, U. Grzyska, et al., Blister-like aneurysms—a diagnostic and therapeutic challenge, *Neurosurg. Rev.* 34 (4) (2011) 409–416.
- [15] J.W. Lee, H.G. Choi, J.Y. Jung, S.K. Huh, K.C. Lee, Surgical strategies for ruptured blister-like aneurysms arising from the internal carotid artery: a clinical analysis of 18 consecutive patients, *Acta Neurochir.* 151 (2) (2009) 125–130.
- [16] Y. Ezaki, H. Takahata, K. Kamada, S. Baba, M. Kaminogo, Aneurysmal embolization of a blisterlike aneurysm of the internal carotid artery: a case report and review of the literature, *Surg. Neurol.* 65 (6) (2006) 628–630, discussion 630.
- [17] J.H. Park, I.S. Park, D.H. Han, et al., Endovascular treatment of blood blister-like aneurysms of the internal carotid artery, *J. Neurosurg.* 106 (5) (2007) 812–819.
- [18] P.D. McNeely, D.B. Clarke, B. Baxter, R.A. Vandorpe, I. Mendez, Endovascular treatment of a “blister-like” aneurysm of the internal carotid artery, *Can. J. Neurological Sci. Le journal canadien des sciences neurologiques* 27 (3) (2000) 247–250.
- [19] J.Y. Ahn, J.H. Cho, J.Y. Jung, B.H. Lee, P.H. Yoon, Blister-like aneurysms of the supraclinoid internal carotid artery: challenging endovascular treatment with stent-assisted coiling, *J. Clin. Neurosci.* : official journal of the Neurosurgical Society of Australasia 15 (9) (2008) 1058–1061.
- [20] S.Y. Sim, Y.S. Shin, K.G. Cho, et al., Blood blister-like aneurysms at nonbranching sites of the internal carotid artery, *J. Neurosurg.* 105 (3) (2006) 400–405.
- [21] A.R. Martin, J.P. Cruz, C.C. Matouk, J. Spears, T.R. Marotta, The pipeline flow-diverting stent for exclusion of ruptured intracranial aneurysms with difficult morphologies, *Neurosurgery* 70 (1 Suppl Operative) (2012) 21–28, discussion 28.

- [22] M. Ghorbani, H. Shojaei, K. Bavand, M. Azar, Surpass streamline flow-diverter embolization device for treatment of iatrogenic and traumatic internal carotid artery injuries, *AJNR Am. J. Neuroradiol.* 39 (6) (2018) 1107–1111.
- [23] L. Pierot, Flow diverter stents in the treatment of intracranial aneurysms: where are we? *J. Neuroradiol. Journal de neuroradiologie* 38 (1) (2011) 40–46.
- [24] M.D. Mazur, P. Taussky, J.D. MacDonald, M.S. Park, Rerupture of a blister aneurysm after treatment with a single flow-diverting stent, *Neurosurgery* 79 (5) (2016) E634–e638.
- [25] J.W. Yoon, A.H. Siddiqui, T.M. Dumont, et al., Feasibility and safety of pipeline embolization device in patients with ruptured carotid blister aneurysms, *Neurosurgery* 75 (4) (2014) 419–429, discussion 429.
- [26] C. Cinar, I. Oran, H. Bozkaya, E. Ozgiray, Endovascular treatment of ruptured blister-like aneurysms with special reference to the flow-diverting strategy, *Neuroradiology* 55 (4) (2013) 441–447.
- [27] S.T. Lang, Z. Assis, J.H. Wong, W. Morrish, A.P. Mitha, Rapid delayed growth of ruptured supraclinoid blister aneurysm after successful flow diverting stent treatment, *BMJ Case Rep.* 2016 (2016).
- [28] D.K. Kung, B.A. Policeni, A.W. Capuano, et al., Risk of ventriculostomy-related hemorrhage in patients with acutely ruptured aneurysms treated using stent-assisted coiling, *J. Neurosurg.* 114 (4) (2011) 1021–1027.
- [29] L.M. Tumialan, Y.J. Zhang, C.M. Cawley, J.E. Dion, F.C. Tong, D.L. Barrow, Intracranial hemorrhage associated with stent-assisted coil embolization of cerebral aneurysms: a cautionary report, *J. Neurosurg.* 108 (6) (2008) 1122–1129.