



A rare form of Mayer-Rokitansky-Küster-Hauser syndrome: Case report and review of literature

Omran Al Dandan *, Ali Hassan, Amna Alsaihati, Lujain Aljawad, Fathiya Almejhim

Imam Abdulrahman Bin Faisal University, King Fahd Hospital of the University, Al-Khobar, Saudi Arabia

ARTICLE INFO

Article history:

Received 15 July 2019

Received in revised form 30 July 2019

Accepted 2 August 2019

Keywords:

Primary amenorrhea

Mullerian agenesis

Mayer-Rokitansky-Küster-Hauser syndrome

ABSTRACT

Introduction: Primary amenorrhea is failure to reach menarche. Mayer-Rokitansky-Küster-Hauser (MRKH) syndrome is the second most common cause of primary amenorrhea, after gonadal dysgenesis. Herein, we report a rare case of an unusual subtype of MRKH syndrome.

Case Report: This report describes the case of a 28-year-old woman with primary amenorrhea and coital difficulties. On examination, she had normal secondary sexual characteristics but a blind-ending vagina. Her hormonal profile was within normal limits; ultrasound examination was inconclusive due to technical difficulties. Subsequently, she underwent pelvic magnetic resonance imaging, which revealed bilateral rudimentary uterine horns in the presence of normal ovaries and normal length of a blind-ending narrow vagina.

Conclusion: MRKH syndrome with bilateral rudimentary uterine horns and normal-length vagina is an unusual form of Müllerian agenesis.

© 2019 The Author(s). Published by Elsevier B.V. This is an open access article under the CC BY-NC-ND license (<http://creativecommons.org/licenses/by-nc-nd/4.0/>).

1. Introduction

Primary amenorrhea is defined as absence of menarche by 13 years of age in the absence of secondary sexual characteristics or by 15 years of age in the presence of secondary sexual characteristics [1]. There are various causes of primary amenorrhea, including primary ovarian insufficiency, outflow disorders of the female genital tract, hypothalamic and pituitary diseases, and receptor abnormalities or enzyme deficiencies. However, any secondary cause of amenorrhea (e.g. polycystic ovarian syndrome) can also present as primary amenorrhea [1].

Herein, we present a case of a 28-year-old woman who presented with a complaint of primary amenorrhea and coital difficulties. After thorough history and clinical examination, pelvic magnetic resonance imaging (MRI) was performed, which revealed isolated bilateral rudimentary uterine horns with a narrow but normal-length vagina and normal ovaries. This is a rare form of Müllerian agenesis.

2. Case Presentation

A 28-year-old nulliparous woman presented the gynecology clinic with primary amenorrhea and difficulties with sexual intercourse in the form of pain and resistance. She had been married for three years. A review of her pubertal development revealed onset of thelarche at age of 11 and pubarche at age of 12. She did not report having cyclic

pelvic pain. She had an unremarkable medical, surgical and social history. She was not on any medications. Additionally, there was no history of congenital anomalies among the family members. Her mother's obstetric history was unremarkable, with no exposure to hormonal therapy or radiation while pregnant and a full-term vaginal delivery.

The patient was of average height and weight and normal arm span. The breasts were well developed and there was normal distribution of axillary and pubic hair (Tanner Stage 5) with grossly normal external female genitalia. A bimanual pelvic examination revealed a narrow vaginal canal with a blind end. Her complete blood count was within normal limits. Laboratory test results for follicular stimulating hormone, luteinizing hormone, thyroid stimulating hormone, estradiol, progesterone, testosterone, and prolactin were within the reference range, confirming normal reproductive female hormones (Table 1).

On transabdominal ultrasonography, the uterus and ovaries could not be visualized. Subsequently, MRI of the pelvis was performed with and without contrast (Fig. 1), which revealed that the vagina was blind-ending with a narrow lumen and a length of 9 cm. Assessment for the presence of the vaginal septum was difficult as the lumen was not distended. The cervix was absent. There were bilateral rudimentary uterine horns interconnected at the midline with a fibrous septum, with no endometrial cavities. Additionally, both right and left ovaries were seen, with volumes of 6.5 and 3.5 mL, respectively, and were of normal appearance with multiple follicles. No urinary tract anomalies were seen. An intra-venous urogram was not performed as standard MRI protocol for Mullerian duct anomalies, at our institution, covers the region of the kidneys and adrenals. Based on the findings, a diagnosis of type I Mayer-Rokitansky-Küster-Hauser (MRKH) syndrome was made.

* Corresponding author.

E-mail address: odandan@iau.edu.sa (O. Al Dandan).

Table 1
Result of the patient's hormonal profile.

Hormone	Level		Normal range	
FSH	4.7	IU/L	4.5–21.5	IU/L
LH	3.2	IU/L	1–9	IU/L
TSH	0.79	μIU/mL	0.4–4	μIU/mL
Progesterone	1.0	ng/mL	0.1–1.0	ng/mL
Estradiol	53.6	pg/mL	15–350	pg/mL
Testosterone	41	ng/dL	15–70	ng/dL
Prolactin	12.3	ng/mL	2–29	ng/mL

FSH; follicle-stimulating hormone, LH; luteinizing hormone, TSH; thyroid-stimulating hormone.

Our patient had extensive counseling regarding the diagnosis and its implications for fertility and childbearing, along with involvement of a consultant psychologist to support the patient in dealing with the emotional burden of the condition.

3. Discussion

Müllerian agenesis, eponymously referred to as Mayer-Rokitansky-Küster-Hauser (MRKH) syndrome, is a spectrum of congenital anomalies of unknown etiology characterized by a variable degree of utero-vaginal agenesis in women with normal secondary sexual characteristics and a 46, XX karyotype. The reported prevalence of the condition is 1 in 5000 females and it is the second most common cause of primary amenorrhea, after gonadal dysgenesis [2].

The condition was first described by the German anatomist and physiologist Mayer in 1829. It was also reported in various studies by Rokitansky (1838), Küster (1910), and Hauser and Schreiner (1961)

and was later named MRKH syndrome [3]. It is caused by interrupted development of the Müllerian duct system, which normally forms the uterus, cervix and the upper two-thirds of the vagina, during the fifth and sixth weeks of gestation [3].

MRKH syndrome is generally classified into two types, with type I being seen in isolated cases of utero-vaginal agenesis, while the more common type II is seen in cases of utero-vaginal agenesis associated with extra-genital anomalies, including urologic (e.g. renal agenesis, pelvic kidney, and horseshoe kidneys), skeletal, auditory and cardiac anomalies. So-called Müllerian hypoplasia, renal agenesis, cervicothoracic somite dysplasia (MURCS) association is the most severe form of type II MRKH syndrome [4].

The spectrum of genital and associated anomalies comprising MRKH syndrome was reported in 2012 by Oppelt et al. in a cohort of 284 patients. It was demonstrated that in all cases there was complete agenesis of both the vagina and the cervix. Uterine malformations were variable, with bilateral rudimentary uterine horns being the most frequent [5]. Among the patients with associated extra-genital malformations, renal anomalies were the most common. Interestingly, among these 284 patients there was no case of an isolated uterine anomaly, as seen in our case [5].

Ultrasound examination is often the first diagnostic test in the evaluation of patients with MRKH syndrome and can confirm the presence of ovaries and the absence of a uterus [6]. However, due to technical difficulties, the results can sometimes be inconclusive [6]. MRI is the imaging modality of choice for the confirmation of diagnosis and is also useful in the identification of any associated malformations [7,8]. It is worth mentioning that Preibsch et al. have shown an excellent correlation between MRI and laparoscopy findings in patients with MRKH syndrome [9]. In view of the high sensitivity of MRI for this condition, we

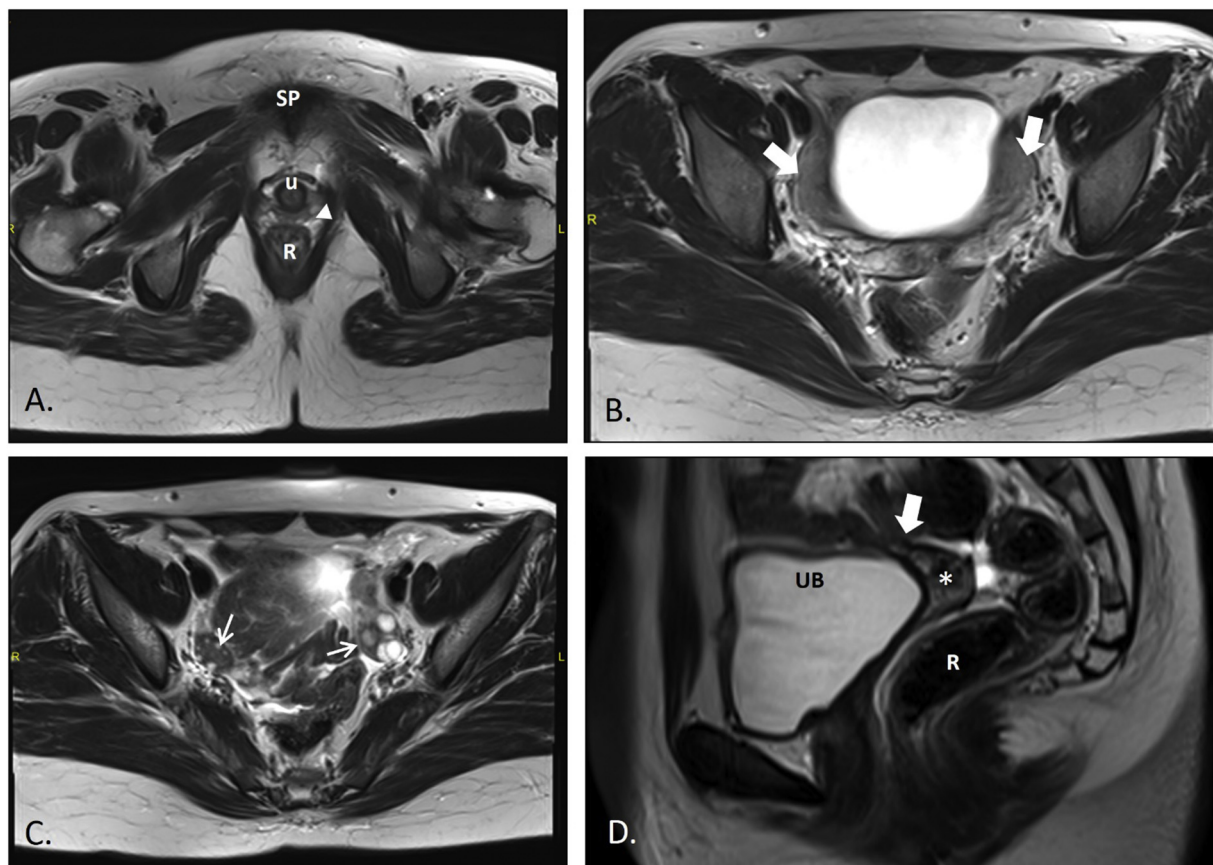


Fig. 1. MRI of pelvis T2-weighted TSE images: Axial (A; at the level of symphysis pubis, B & C; at lower sacrum), and Mid-sagittal (D) showing absent cervix with interposition of bowel loops in the expected location of cervix (thick arrow in B). Rudimentary uteri (thick arrow in B) are interconnected at midline. The lower vagina is small (arrowhead in A). The vaginal vault is present (asterix in D). Both ovaries are normal (thin arrows in B). R: Rectum. SP: symphysis pubis. TSE: turbo spin echo U: urethra. UB: urinary bladder.

were satisfied with the imaging findings in the present case and chose not to proceed to diagnostic laparoscopy.

The differential diagnoses of the condition include androgen insensitivity, transverse vaginal septum and imperforate hymen. Androgen insensitivity syndrome is distinguished from MRKH syndrome by decreased pubic and axillary hair, a 46, XY karyotype, male testosterone level and presence of rudimentary testicles on magnetic resonance images [2,6].

The diagnosis of MRKH syndrome imposes a significant psychological burden on patients because of the associated infertility [6]. The distress can be alleviated by psychological counseling and support groups. Treatments include progressive vaginal dilators or surgical creation of a neovagina. Assisted reproductive techniques and surrogacy may be options with regard to fertility [2,10].

Contributors

Omran Al Dandan edited and finalized the manuscript. Ali Hassan drafted the manuscript and reviewed the literature. Amna Alsaihati drafted the manuscript and reviewed the literature. Lujain Aljawad obtained patient data and drafted the manuscript. Fathiya Almejhim edited the manuscript. All authors read and approved the final manuscript.

Funding

This research did not receive any specific grant from funding agencies in the public, commercial or not-for-profit sectors.

Patient Consent

Written informed consent was obtained from the patient for publication of this case report and accompanying images.

Provenance and Peer Review

This case report was peer reviewed.

Declaration of Competing Interest

The authors declare that they have no conflict of interest regarding the publication of this case report.

References

- [1] Current evaluation of amenorrhea, *Fertil. Steril.* 90 (5) (2008) S219-S25.
- [2] ACOG Committee Opinion No. 728, Mullerian agenesis: diagnosis, management, and treatment, *Obstet. Gynecol.* 131 (1) (2018) e35–e42.
- [3] A. Pizzo, A.S. Laganà, E. Sturlese, G. Retto, A. Retto, R. De Dominicis, et al., Mayer-rokitansky-kuster-Hauser syndrome: embryology, genetics and clinical and surgical treatment, *ISRN Obstet. Gynecol.* 2013 (2013), 628717.
- [4] S. Ledig, P. Wieacker, Clinical and genetic aspects of Mayer-Rokitansky-Küster-Hauser syndrome, *Med. Genetik: Mitteilungsblatt des Berufsverbandes Med. Genetik eV.* 30 (1) (2018) 3–11.
- [5] P.G. Oppelt, J. Lermann, R. Strick, R. Dittrich, P. Strissel, I. Rettig, et al., Malformations in a cohort of 284 women with Mayer-Rokitansky-Küster-Hauser syndrome (MRKH), *Reprod. Biol. Endocrinol.: RB&E.* 10 (2012) 57.
- [6] L. Londra, F.S. Chuong, L. Kolp, Mayer-Rokitansky-Küster-Hauser syndrome: a review, *Int. J. Women's Health* 7 (2015) 865–870.
- [7] D.K. Boruah, S. Sanyal, B.B. Gogoi, K. Mahanta, A. Prakash, A. Augustine, et al., Spectrum of MRI appearance of Mayer-Rokitansky-Küster-Hauser (MRKH) syndrome in primary amenorrhea patients, *J. Clin. Diagn. Res.* 11 (7) (2017) TC30-TC5.
- [8] V. Fiaschetti, A. Taglieri, V. Gisone, I. Coco, G. Simonetti, Mayer-Rokitansky-Küster-Hauser syndrome diagnosed by magnetic resonance imaging. Role of imaging to identify and evaluate the uncommon variation in development of the female genital tract, *J. Radiol. Case Rep.* 6 (4) (2012) 17–24.
- [9] H. Preibsch, K. Rall, B.M. Wietek, S.Y. Brucker, A. Staebler, C.D. Clausen, et al., Clinical value of magnetic resonance imaging in patients with Mayer-Rokitansky-Küster-Hauser (MRKH) syndrome: diagnosis of associated malformations, uterine rudiments and intrauterine endometrium, *Eur. Radiol.* 24 (7) (2014) 1621–1627.
- [10] D.K. Edmonds, G.L. Rose, M.G. Lipton, J. Quek, Mayer-Rokitansky-Küster-Hauser syndrome: a review of 245 consecutive cases managed by a multidisciplinary approach with vaginal dilators, *Fertil. Steril.* 97 (3) (2012) 686–690.