

## Epidemiological and clinical features of the endomyocardial form of restrictive cardiomyopathy in cats: a review of 41 cases

Yusuke KIMURA<sup>1)</sup>, Ryuji FUKUSHIMA<sup>2)</sup>, Atsushi HIRAKAWA<sup>3)</sup>, Masayuki KOBAYASHI<sup>1)</sup> and Noboru MACHIDA<sup>1)\*</sup>

<sup>1)</sup>Laboratory of Veterinary Clinical Oncology, Tokyo University of Agriculture and Technology, 3-5-8 Saiwai-cho, Fuchu, Tokyo 183-8509, Japan

<sup>2)</sup>Laboratory of Veterinary Surgery, Tokyo University of Agriculture and Technology, 3-5-8 Saiwai-cho, Fuchu, Tokyo 183-8509, Japan

<sup>3)</sup>Pet Clinic Hallelujah, 2544-1 Nakabaru, Kasuya, Kasuya-gun, Fukuoka 811-2304, Japan

(Received 25 June 2015/Accepted 15 January 2016/Published online in J-STAGE 28 January 2016)

**ABSTRACT.** Examination of our necropsy records for the period 2005 to 2014 yielded 41 cases of the endomyocardial form of restrictive cardiomyopathy among 327 cats with evidence of heart disease, and here, we reviewed their epidemiological and clinical features. The medical data obtained retrospectively included signalment, presenting complaints, findings of physical examination, results of various diagnostic tests, methods of treatment and survival times. Except for one Chinchilla Persian cat, all were domestic short-haired cats. The mean age at death was  $7.3 \pm 4.5$  years (median, 6 years; range, 4 months to 19 years), and males accounted for 61% (25/41) of the total. Dyspnea was the most common clinical sign, being evident in 83% (35/41) of the cats. Hind limb paresis or paralysis due to aortic thromboembolism was evident in 41% (17/41). Arrhythmias of atrial origin were common. Echocardiography commonly revealed left atrial or biatrial enlargement with severe endocardial thickening of the left ventricle. Most of the affected cats had a poor outcome; the disease duration ranged from 1 to 977 days, and the median survival period was 30 days.

**KEY WORDS:** endomyocardial fibrosis, epidemiology, feline, restrictive cardiomyopathy

doi: 10.1292/jvms.15-0373; *J. Vet. Med. Sci.* 78(5): 781–784, 2016

Restrictive cardiomyopathy (RCM) is a primary myocardial disease characterized by diastolic dysfunction (restrictive pathophysiology) resulting from ventricular wall stiffness and represents the second most common form of cardiomyopathy in cats [3]. In humans, RCM is divided into two basic categories: conditions with predominant endocardial involvement (endomyocardial form) and others with predominant myocardial involvement (myocardial form) [6]. This classification also appears to be valid for cats, and the former type is known as endomyocardial fibrosis [2, 5].

In the endomyocardial form of RCM, marked fibrosis focally or diffusely involving the endocardium or endomyocardium primarily affects the left ventricle (LV) and causes chamber deformity and/or obstruction at different levels. These disorders cause elevation of the left ventricular diastolic pressure with normal-to-reduced ventricular filling volumes (decreased compliance). This elevation of diastolic ventricular pressure results in left atrial enlargement and pulmonary venous congestion or pulmonary edema. Systolic function (contractility) of the LV is generally normal or mildly impaired [4, 5, 7, 8].

In humans, endomyocardial form of RCM can result from endomyocardial fibrosis (Loeffler's endocarditis and tropical

endomyocardial fibrosis) and endocardial fibroelastosis (primary and secondary) [6]. The etiology of endomyocardial form of RCM in cats is unknown but considered multifactorial, as there is a wide spectrum of clinical manifestations and pathologic phenotypes [5]. In other words, specific diagnostic clinical and morphologic criteria in the cat have not been as clearly defined as they have in humans [8].

In order to deepen the understanding of the epidemiological and clinical features of endomyocardial form of RCM in cats, the present report reviews 41 necropsies that were diagnosed at our laboratory between 2005 and 2014.

### MATERIALS AND METHODS

The materials for the present study were obtained from consecutive feline necropsies conducted in the Laboratory of Veterinary Clinical Oncology, Tokyo University of Agriculture and Technology, during the period January 2005 to December 2014. A total of 327 necropsies were performed on cats with heart disease, and 41 cats were diagnosed as having the endomyocardial form of RCM. During this period, 34 cases of hypertrophic cardiomyopathy (HCM), 12 cases of dilated cardiomyopathy (DCM), 11 cases of arrhythmogenic right ventricular cardiomyopathy (ARVC) and 2 cases of myocardial form of RCM were identified.

The diagnosis of endomyocardial RCM was based on characteristic gross features and histological evidence of marked fibrosis focally or diffusely involving the endocardium or endomyocardium of the LV. Grossly, the hallmark findings included an enlarged heart with marked left atrial and often right atrial dilatation and hypertrophy; severe and extensive endocardial scarring frequently bridging between

\*CORRESPONDENCE TO: MACHIDA, N., Laboratory of Veterinary Clinical Oncology, Tokyo University of Agriculture and Technology, 3-5-8 Saiwai-cho, Fuchu, Tokyo 183-8509, Japan.  
e-mail: machida@cc.tuat.ac.jp

©2016 The Japanese Society of Veterinary Science

This is an open-access article distributed under the terms of the Creative Commons Attribution Non-Commercial No Derivatives (by-nc-nd) License <<http://creativecommons.org/licenses/by-nc-nd/4.0/>>.

the left ventricular free wall (LVFW) and septum (VS) (Fig. 1); left ventricular hypertrophy commonly associated with wall and chamber deformity; and mural thrombi in the left atrium (LA) or LV [4, 5].

The medical data were obtained at three different facilities and included signalment (breed, age and sex), presenting complaints, findings of physical examination, results of various diagnostic tests, treatment methods and survival times. Laboratory data that were evaluated included complete blood counts (CBCs) and serum biochemistry profiles. Thoracic radiographs (lateral and dorsoventral projections), standard six-lead electrocardiograms, and two-dimensional and Doppler echocardiograms were available for most or all of the cats. Survival times for all of the cats were calculated from the date of clinical diagnosis until death. Median survival time was defined as the time at which 50% of the cats were still alive.

## RESULTS

Forty were domestic short-haired cats, and one was a Chinchilla Persian cat. The mean age at death was 7.3 years (median, 6 years), ranging from 4 months to 19 years, with a standard deviation of 4.5 years. The sex distribution was 25 males (19 castrated and 6 intact) and 16 females (13 spayed and 3 intact).

Thirty of the 41 cats were presented because of respiratory distress, and six of these also had hind limb paresis or paralysis due to aortic thromboembolism (ATE). An additional 11 cats had only hind limb paresis or paralysis. Common abnormalities demonstrated by physical examination at initial presentation included dyspnea (n=35), tachycardia (n=28), muffled heart and lung sounds (n=24), absent femoral pulses (n=17), irregular heart rhythms (n=12), abdominal distension (n=10), systolic heart murmurs (n=8) and gallop sounds (n=7). The thyroid glands were not palpable in any cases.

CBCs and serum biochemical analyses were performed on 37 cats at initial presentation. Results of CBCs were within normal limits in 29 cats; the remaining eight cats had either mild leukocytosis (n=5) or mild anemia (n=3). Serum biochemical abnormalities included mild to marked increases in blood urea nitrogen (n=13), aspartate aminotransferase and alanine aminotransferase activities (n=14), and lactate dehydrogenase and creatine kinase activities (n=2).

Thoracic radiographs were taken in 38 cats, and these commonly demonstrated generalized mild to moderate cardiomegaly with a marked increase in the size of the left or both the left and right atria (n=36). Pleural effusion and pulmonary edema were evident in 27 and 19 cats, respectively. Abdominal radiographs confirmed ascites (n=12) and hepatomegaly (n=9).

Standard six-lead electrocardiograms were obtained in 34 cats. A variety of arrhythmias were recorded alone or in combination in 19 cats, including premature atrial contractions (PACs; n=9), atrial fibrillation (AF; n=5), premature ventricular contractions (PVCs; n=5), right bundle branch block (RBBB; n=4), complete atrioventricular block (CAVB; n=1) and first-degree atrioventricular block (1AVB; n=1).

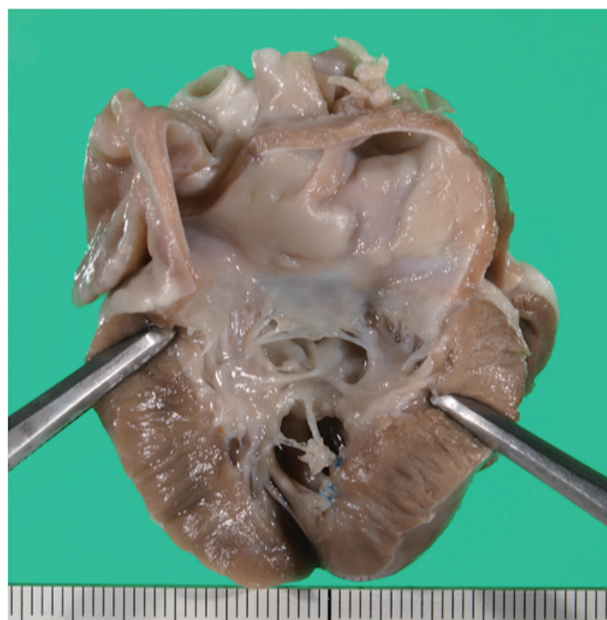


Fig. 1. Left side of the heart from a 3-year-old castrated male domestic short-haired cat with the endomyocardial form of restrictive cardiomyopathy (RCM), showing extensive endocardial fibrosis involving substantial portions of the left ventricular cavity. The fibrotic lesions envelop and fuse the papillary muscles and chordae tendineae, causing distortion of the mitral apparatus. The left atrium is severely enlarged with diffuse endocardial thickening. Scale, 1 mm.

Echocardiographic examination performed on all 41 cats commonly revealed moderate to severe left atrial (n=29) or biatrial (n=12) enlargement with variable LVFW and VS thickening. Patchy or extensive areas of increased echogenicity of the endocardium were also observed within the LV (n=36) (Fig. 2). The endocardial lesions were often present as large trabecular bands bridging the LVFW and VS (n=25). Echocardiographic evidence of mural thrombus in the LA was found in 8 cats. Mild to moderate mitral and/or tricuspid regurgitation was a consistent finding on Doppler examination (n=38).

Medical treatment was attempted in all 41 cats. The treatment regimens included administration of diuretics, positive inotropic agents, an ACE inhibitor, and antiarrhythmic drugs. The outcome was generally poor, and half of the cats died of profound left-sided or biventricular congestive heart failure (CHF) or recurrent ATE within 1 month of clinical onset: the median survival time was 30 days (range, 1 to 977 days).

## DISCUSSION

To the authors' knowledge, the endomyocardial form of RCM in cats was first described by Liu [9], who reported a retrospective series of 68 cases of focal endocardial and myocardial fibrosis in the LV as "acquired cardiac disease leading to CHF". Thereafter, the clinical and morphologic features of the abnormality were systematically assessed and

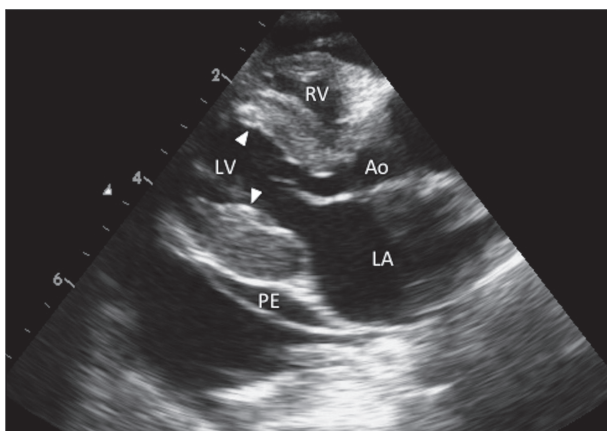


Fig. 2. Two-dimensional echocardiogram (long-axis view from the right parasternal location) of a 7-year-old spayed female domestic short-haired cat with endomyocardial RCM, showing marked left atrial enlargement and irregular hyperechoic endocardial regions within the left ventricle (arrowheads). Ao, aorta; LA, left atrium; LV, left ventricle; PE, pericardial effusion; RV, right ventricle.

published as feline RCM by Liu and Tilley [11]. Since then, the endomyocardial form of RCM has been recognized as an important cause of left-sided or biventricular CHF or ATE in cats. In 2004, Fox [5] reported the first comprehensive description of the disease.

In the present study, the endomyocardial form of RCM was diagnosed pathologically in 41 cats over a 10-year period (2005 to 2014), during which 34 cases of HCM, 12 cases of DCM and 11 cases of ARVC were identified. The prevalence of the disease in cats is currently unknown, but it appears to be less prevalent than HCM but more prevalent than DCM [1]. One clinical report of 106 cats with cardiomyopathy identified RCM in 21% (22/106) of them, HCM in 58% (61/106) and DCM in 10% (11/106) [3]. Such variations may reflect differences in the time frame, geography and breed prevalence between the present and previous studies. On the other hand, it is possible that this type of cardiomyopathy is more common than published clinical reports indicate, since endocardial fibrotic lesions could be overlooked during echocardiography due to their location and size, the quality of the ultrasonographic equipment or the skill of the operator. In this connection, it is interesting to note that a study of 1,472 cats necropsied between 1986 and 1992 identified 37 cases of endomyocarditis (EMC) and 25 cases of left ventricular endocardial fibrosis (LVEF), followed by 34 cases of HCM and 33 cases of DCM; in that report, it was considered that EMC and LVEF represented temporally different manifestations of a single disease entity (i.e. endomyocardial RCM) [13].

Among the 41 cats included in the present study, all were domestic short-haired cats except for one Chinchilla Persian, and no breed predilection was evident; this is consistent with previous reports. In one necropsy study of 25 cats with LVEF (endomyocardial RCM), 22 were domestic short-haired cats, and three were Siamese cats [13]. Furthermore, this condi-

tion has been reported in Birman, Siamese and Persians as well as domestic shorthair and longhair cats, but specific breed predispositions have not been identified [3, 11, 12].

In our series of cases, the mean age at death was  $7.3 \pm 4.5$  years (median, 6 years; range, 4 months to 19 years). In two series of pathologic studies of cats with the endomyocardial form of RCM, the mean age at death was reported as  $7.3 \pm 4.0$  years (range, not described) and  $6.8 \pm 0.5$  years (range, 1 to 11 years), respectively [9, 10]. In addition, in a pathologic report of cats affected by LVEF, the mean age at death was 7.4 years (range, 1 to 16 years) [13]. Thus, the mean age at death of the affected cats in the present series is similar to that reported in previous descriptions.

In the present study, the total numbers of male and female cats were 25 (61%) and 16 (39%), respectively. The male/female ratio was 1.56, indicating a slight predominance in males, although we were unable to rigorously compare this figure with the proportions of male cats in previous necropsy populations. One reported series of 68 cats with LVEF included 40 males and 28 females (59% vs 41%) [9]. In one pathologic study of 25 cats with LVEF, 20 were males, and five were females (80% vs 20%) [13]. On the other hand, in a clinical case series of 22 cats, 73% were females [3]. Thus, some reports have indicated a male predisposition, whereas others have reported a female predisposition. Further studies will be needed to confirm any gender predisposition.

The clinical findings observed in our present 41 cases were generally related to left-sided or biventricular CHF, including dyspnea, tachycardia, pleural effusion, ascites, pulmonary edema and hind limb paresis or paralysis due to ATE. Eight cats had systolic murmurs associated with mitral and/or tricuspid regurgitation and irregular heart rhythms. CBCs were generally within the normal ranges, and no pathognomonic abnormalities of significance were detected. The results of serum biochemical analyses largely reflected the disease process underlying ATE. Thoracic radiographs frequently revealed various degrees of cardiomegaly, pleural effusion and pulmonary edema. Echocardiography disclosed severe endocardial thickening of the LV with left-atrial or biatrial enlargement. These clinical findings reviewed in this series are very similar to those reported in previous descriptions, including a high risk of ATE [3, 5, 11]. There was no obvious relationship between the occurrence of hind limb paresis or paralysis and echocardiographic evidence of mural thrombus in the LA. Various arrhythmias were observed alone or in combination on electrocardiography in 19 affected cats, including PACs, AF, PVCs, RBBB, CAVB and 1AVB. The frequency of PACs (26%; 9/34) and AF (15%; 5/34) in our cats was not surprising in view of the severe left-atrial or biatrial enlargement detected by echocardiography [5].

In our series of cases, the duration of the disease ranged from 1 to 977 days, with a median survival time of 30 days, despite aggressive medical treatment. For a total of 16 cats with RCM including 12 that had died before the time of publication and 4 that had still been alive, Ferasin *et al.* [3] reported median survival times of 21 days for the former and 1,277 days for the latter, respectively; almost half of the cats did not survive more than 1 month. Thus, cats with RCM

have previously been found to have short survival times, and the results of the present study confirmed this. In other words, most affected cats are diagnosed at an advanced stage of the disease, presumably because the clinical signs may not be evident until cardiac decompensation has markedly progressed.

The present results confirmed and extended the findings of previous studies and led to the following conclusions, although limitations of the study include the small size and the retrospective and necropsy-based nature of the research. First, the endomyocardial form of RCM in cats might be more prevalent than believed previously, because there is a possibility that endocardial fibrotic lesions might be overlooked during echocardiography. Second, we found a slight predominance in males (male/female ratio of 1.56), although we were unable to rigorously compare this figure with the proportions of male cats in previous necropsy populations. Third, medical treatment of left-sided or biventricular CHF is usually ineffective, although management of pleural effusion and pulmonary edema for more than 1 year has been possible in some cats. Finally, the prognosis for cats with endomyocardial RCM is poor; many affected cats die due to profound CHF or ATE, with a median survival time of 1 month.

#### REFERENCES

- Cote, E., MacDonald, K. A., Meurs, K. M. and Sleeper, M. M. 2011. Restrictive / unclassified cardiomyopathy. pp. 177–181, *In: Feline Cardiology*, Wiley-Blackwell, Ames.
- Ferasin, L. 2009. Feline myocardial disease. 1: Classification, pathophysiology and clinical presentation. *J. Feline Med. Surg.* **11**: 3–13. [[Medline](#)] [[CrossRef](#)]
- Ferasin, L., Sturgess, C. P., Cannon, M. J., Caney, S. M. A., Gruffydd-Jones, T. J. and Wotton, P. R. 2003. Feline idiopathic cardiomyopathy: a retrospective study of 106 cats (1994–2001). *J. Feline Med. Surg.* **5**: 151–159. [[Medline](#)] [[CrossRef](#)]
- Fox, P. R. 1999. Feline cardiomyopathies. pp. 621–678. *In: Textbook of Canine and Feline Cardiology*, 2nd ed. (Fox, P. R., Sisson, D. and Moise, N. S. eds.), W. B. Saunders, Philadelphia.
- Fox, P. R. 2004. Endomyocardial fibrosis and restrictive cardiomyopathy: pathologic and clinical features. *J. Vet. Cardiol.* **6**: 25–31. [[Medline](#)] [[CrossRef](#)]
- Gallo, P. and d'Amati, G. 2001. Cardiomyopathies. pp. 285–325. *In: Cardiovascular Pathology*, 3rd ed. (Silver, M. D., Gotlieb, A. I. and Schoen, F. I. eds.), Churchill Livingstone, New York.
- Kienle, R. D. 1998. Feline unclassified and restrictive cardiomyopathy. pp. 363–369. *In: Small Animal Cardiovascular Medicine* (Kittleson, M. D. and Kienle, R. D. eds.), Mosby, St. Louis.
- Kienle, R. D. 2008. Feline cardiomyopathy. pp. 151–175. *In: Manual of Canine and Feline Cardiology*, 4th ed. (Tilley, L. P., Smith, F. W. K. Jr., Oyama, M. A. and Sleeper, M. M. eds.), Saunders Elsevier, St. Louis.
- Liu, S. K. 1970. Acquired cardiac lesions leading to congestive heart failure in the cat. *Am. J. Vet. Res.* **31**: 2071–2088. [[Medline](#)]
- Liu, S. K. 1985. Myocarditis and cardiomyopathy in the dog and cat. *Heart Vessels Suppl.* **1** Suppl: 122–126. [[Medline](#)] [[CrossRef](#)]
- Liu, S. K. and Tilley, L. P. 1980. Animal models of primary myocardial diseases. *Yale J. Biol. Med.* **53**: 191–211. [[Medline](#)]
- Meurs, K. M., Fox, P. R., Magnon, A. L., Liu, S. and Towbin, J. A. 2000. Molecular screening by polymerase chain reaction detects panleukopenia virus DNA in formalin-fixed hearts from cats with idiopathic cardiomyopathy and myocarditis. *Cardiovasc. Pathol.* **9**: 119–126. [[Medline](#)] [[CrossRef](#)]
- Stalis, I. H., Bossbaly, M. J. and Van Winkle, T. J. 1995. Feline endomyocarditis and left ventricular endocardial fibrosis. *Vet. Pathol.* **32**: 122–126. [[Medline](#)] [[CrossRef](#)]