

Contents lists available at [ScienceDirect](https://www.sciencedirect.com)

International Journal of Surgery Case Reports

journal homepage: www.casereports.com

Successful salvage of an infected breast prosthesis by changing from continuous to intermittent suction under continuous irrigation

Mika Takeuchi*, Masamitsu Kuwahara, Junji Ando, Riyo Miyata, Masayuki Harada, Saori Kanagawa

Division of Plastic Surgery, Nara Medical University Hospital, 840 Shijocho, Kashihara, Nara, 634-8522, Japan

ARTICLE INFO

Article history:

Received 24 February 2021
 Received in revised form 30 March 2021
 Accepted 30 March 2021
 Available online 5 April 2021

Keywords:

Breast reconstruction
 Breast implant
 Breast prosthesis
 Infection

ABSTRACT

INTRODUCTION: Implant-based breast reconstruction is a widely performed procedure. However, prostheses are susceptible to infection and there are currently no established guidelines on treatment. In the present case, a prosthesis was salvaged by changing from continuous irrigation and suction to continuous irrigation and intermittent suction. This case report has been reported in line with the SCARE criteria [1].

PRESENTATION OF CASE: A 50-year-old female patient underwent implant-based breast reconstruction following surgery for breast cancer. One month later, the left breast prosthesis was infected with abscesses. Surgical treatment and continuous irrigation were performed as postoperative therapy. However, recurrent infection was detected a few days after surgery. Continuous irrigation was changed to continuous irrigation with intermittent aspiration, which successfully controlled the infection.

DISCUSSION: Factors that limit the effectiveness of continuous irrigation and aspiration have not yet been identified. Inflow/discharge shunt routes may be established in continuous aspiration, and, thus, sufficient cleaning may not be possible. On the other hand, the storage of water throughout the wound in intermittent aspiration may facilitate cleaning.

CONCLUSION: Intermittent suction worked well in this patient and, thus, warrants further study.

© 2021 Published by Elsevier Ltd on behalf of IJS Publishing Group Ltd. This is an open access article under the CC BY-NC-ND license (<http://creativecommons.org/licenses/by-nc-nd/4.0/>).

1. Introduction

Reconstruction following breast cancer using Allagan's Natrel® Tissue Expander (TE) and prosthesis has been widely performed in Japan since 2013. However, prostheses are vulnerable to infection and there are currently no established guidelines on treatment. A case of an infected breast prosthesis that resisted antibiotics was presented herein.

Two main approaches are currently used to treat infected prostheses: continuous irrigation and suction around the prosthesis with saline and continuous irrigation with intermittent suction. It currently remains unclear whether one system is superior to the other, and the limitations of each system have not yet been elucidated. Furthermore, a method to change from continuous to intermittent suction has not yet been reported for patients with infected prostheses.

In the present case, the prosthesis was successfully salvaged by changing from continuous suction cleaning to intermittent suction cleaning around the prosthesis.

Intermittent suction worked well in this patient and, thus, warrants further study.

2. Presentation of case

A 50-year-old female was receiving methotrexate for rheumatoid arthritis. The patient underwent bilateral resection for breast cancer at the age of 44 years with no recurrence. TE were inserted on both sides at the age of 49 years. The day after surgery, a hematoma developed in the left breast, and emergency hemostasis was performed. Four months after TE insertion, bilateral TE were removed and prostheses were inserted. The patient did not receive radiotherapy. Fever, inflammation of the left chest, and pain developed one month later. Infection around the prosthesis was suspected. Computed tomography showed fluid retention around the left prosthesis (Fig. 1).

The prosthesis was temporarily removed under general anesthesia. Sixty milliliters of yellow pus was discharged (Fig. 2). Poor granulation in the capsule was removed using a spoon. Two 1 cm multichannel™ drainage catheters (flat type) were inserted into the pocket for continuous irrigation, and once thoroughly

Abbreviation: TE, Tissue Expander.

* Corresponding author.

E-mail addresses: mk.takeuchi@naramed-u.ac.jp (M. Takeuchi), makuwa@naramed-u.ac.jp (M. Kuwahara), K171830@naramed-u.ac.jp (J. Ando), mriyo39@naramed-u.ac.jp (R. Miyata), K179415@naramed-u.ac.jp (M. Harada), po0124sor@gmail.com (S. Kanagawa).

<https://doi.org/10.1016/j.ijscr.2021.105860>

2210-2612/© 2021 Published by Elsevier Ltd on behalf of IJS Publishing Group Ltd. This is an open access article under the CC BY-NC-ND license (<http://creativecommons.org/licenses/by-nc-nd/4.0/>).

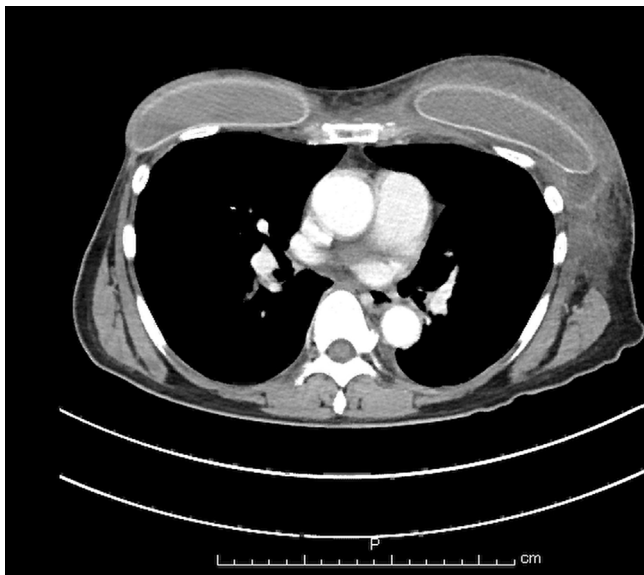


Fig. 1. Fluid retention around the left prosthesis.

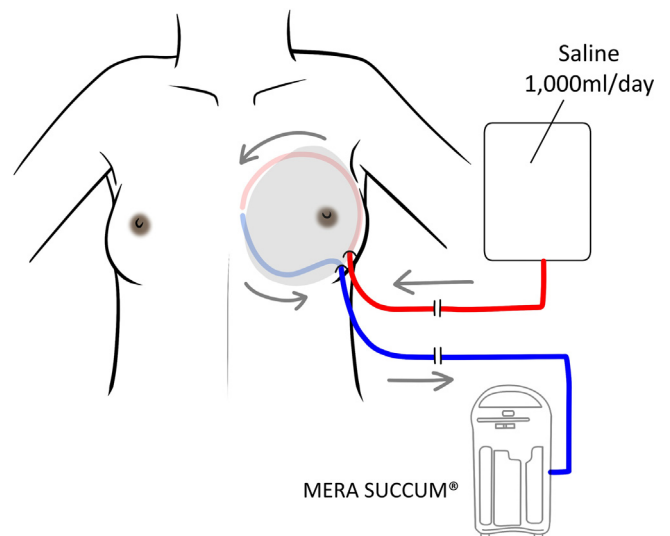


Fig. 3. Schema of continuous irrigation. The continuous infusion of saline at 1000 mL/day and continuous aspiration at 50 cm H₂O negative pressure with MERA SUCUUM® (continuous suction unit). To perform intermittent aspiration, the suction drainage tube (blue tube) was clamped and opened every hour for suction.

washed with povidone iodine, the prosthesis was reinserted. After surgery, continuous irrigation was initiated at 1,000 mL/day with constant aspiration using MERA SUCUUM® (continuous suction unit) (Fig. 3). Meropenem and vancomycin were administered empirically. On the 5th day, fever, pain, inflammation, and blood parameters improved. The infection was considered to be under control and, thus, antibiotic therapy was stopped on the 7th postoperative day. However, the patient developed a high fever on the 8th postoperative day and antibiotic therapy was initiated again. A bacterial culture revealed that the causative bacterium was methicillin-sensitive *Staphylococcus aureus* (MSSA). Since cefazolin

has demonstrated efficacy against MSSA, it was administered to the patient.

Continuous irrigation only was changed to continuous irrigation with intermittent manual aspiration.

One thousand milliliters of saline was continuously infused each day at 60–90 ml/hour with a pump and continuous aspiration at 50 cm H₂O negative pressure was performed with MERA SUCUUM® (continuous suction unit). The clamp was opened for one hour and then closed for one hour. As a guide, a large amount of water is not expected to leak from the site of insertion of the drainage port.

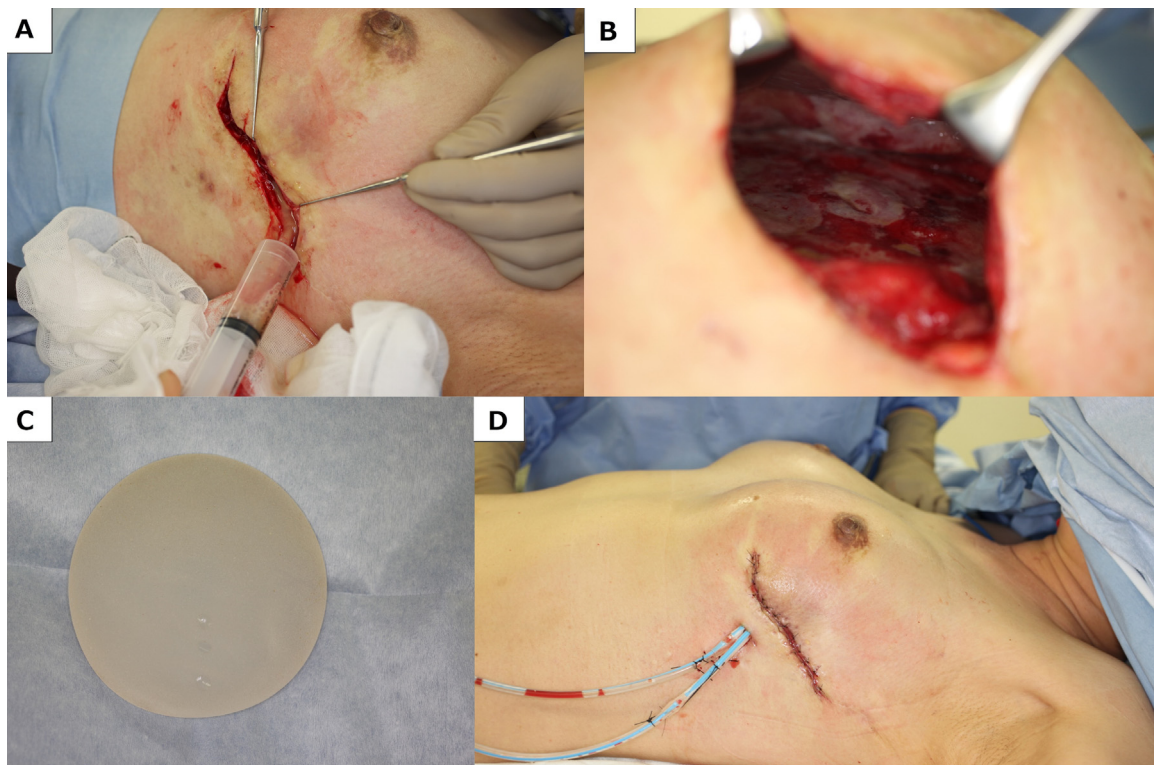


Fig. 2. A: Pus drainage by incision B: After debridement C: Removed TE. It was thoroughly washed and reinserted. D: After surgery.

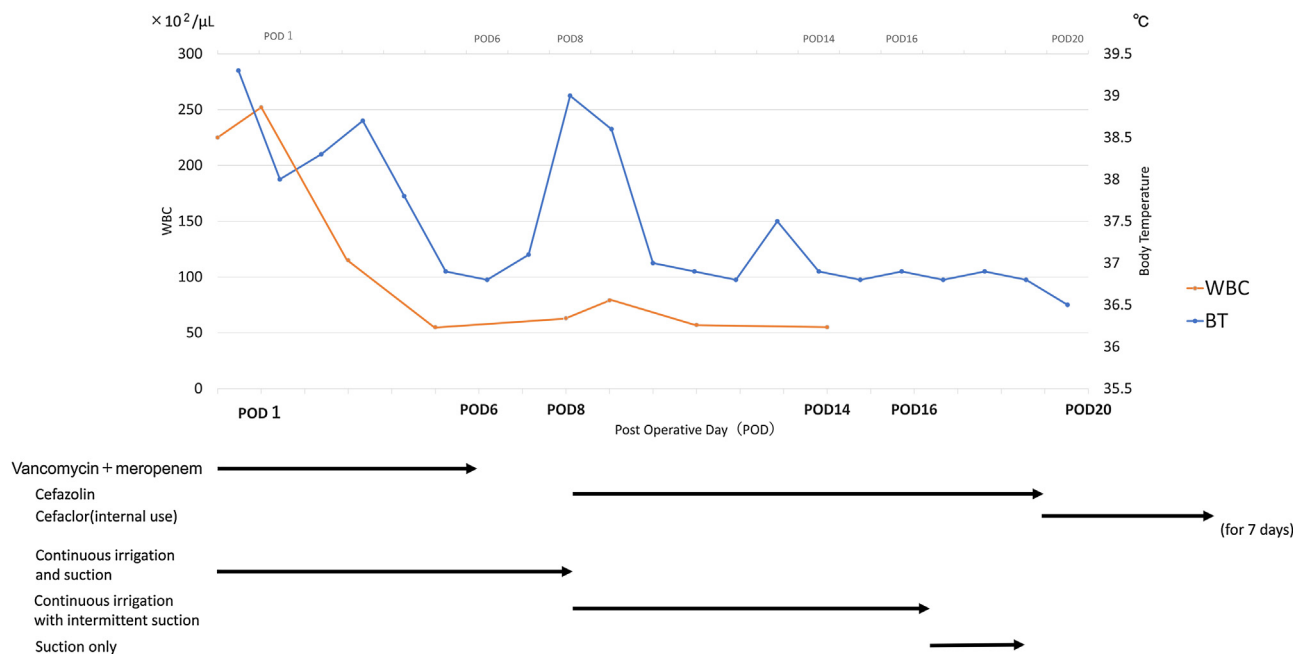


Fig. 4. Pre- and postoperative courses for the WBC count, body temperature, and antibiotics used.

Drainage fluid after the first clamp was purulent. Fever and inflammation were ameliorated, and intermittent aspiration was completed 9 days after its initiation. Drains were removed 3 days later. There have been no signs of infection for 3 years after surgery (Fig. 4).

3. Discussion

Bacteria easily adhere to implant surfaces and produce extracellular polysaccharides and glycoproteins, which form biofilms.

A previous study detected subclinical bacteria on 56% of implants with and on 18% of those without capsular contracture [2].

In addition to a no-touch technique [3], a 14-point plan to reduce the number of bacteria around implants has successfully minimized the occurrence of capsular contracture and infection [4]. Although we adhere to this plan, the cleaning of pockets with antibiotics is not covered by the national health insurance system in Japan and, thus, was not performed on this patient.

The use of an immunosuppressive drug and the presence of a hematoma may have increased the risk of infection in the present case.

Implant infections generally occur more than 30 days after surgery with *Staphylococcus* species [5–8].

Therapeutic approaches vary among hospitals, but mainly include two main types: conservative and surgical [6,9]. Conservative treatment involves antibiotics alone. Surgical treatment includes incisional drainage, tissue debridement and prosthesis replacement with continuous irrigation, and is normally performed by some hospitals in Japan [10,11]. A prosthesis is generally removed when infection is severe and not responding to intravenous antibiotics or cellulitis is accompanied by purulent drainage with systemic signs (i.e., fever and tachycardia) [12,13]. The salvage rate is 70% for TE and 88.2% for prostheses [14].

We explained to the patient that an infected prosthesis is generally removed to maintain the shape of the breast, and reconstruction may be required after a sufficient interval. However, she requested treatment to keep the current prosthesis. We explained that a replacement prosthesis was not readily available and that

cleaning the area around the implant may temporarily attenuate fever, but also that infection may recur and cause life-threatening sepsis. We agreed to attempt to salvage the implant, but also explained that its removal was necessary if the infection was difficult to control. Surgery was subsequently performed with her consent.

In the present case, the wound was considered to be severely infected. Therefore, pocket debridement, careful and meticulous cleaning of the implant by scrubbing with a brush to reduce biofilms, and continuous irrigation with saline were conducted.

A limitation of continuous irrigation is that inflow/discharge shunt routes may need to be established and, as a consequence, sufficient cleaning may not be possible. This appears to have occurred in the present case because drainage fluid after the first clamp was purulent. In an agar wound model, infusion solution was more evenly distributed over the wound surface with intermittent irrigation [15].

Continuous irrigation with intermittent aspiration has two major limitations in clinical settings: leakage from the insertion site of the tube and frequent clamping and suction, which cause discomfort in patients. Kajikawa previously reported a continuous irrigation method with intermittent aspiration [16]. Hayashi demonstrated the efficacy of this method and reduced the risk of leakage by shortening the suction pause time [17]. Following the change from continuous irrigation to intermittent aspiration, leakage was managed using a water absorbing dressing, which reduced the need for frequent clamping and suction.

The continuous irrigation with intermittent aspiration method may have been developed based on the findings obtained from unsuccessful continuous cleaning. Continuous irrigation is not commonly performed for breast reconstruction with implants and the limitations of continuous suction systems currently remain unknown [5,10,11,18]. Although leakage may frequently occur, intermittent cleaning will be performed for future cases. A simpler intermittent cleaning system using the NPWTi system may be developed to reduce patient discomfort. However, this system was not available for the present case. Since a number of similar attempts using the NPWTi system have already been reported [19,20], further studies are warranted.

4. Conclusion

We salvaged a breast implant by changing from continuous to intermittent suction.

Intermittent suction worked well in this patient and, thus, warrants further study.

Sources of funding

This research did not receive any specific grant from funding agencies in the public, commercial, or not-for-profit sectors.

Ethical approval

No institutional review board is required for the publication of a case report at our institution.

Consent

Written informed consent was obtained from the patient for publication of this case report and accompanying images. A copy of the written consent is available for review by the Editor-in-Chief of this journal on request.

Author contribution

Mika Takeuchi: Writing - Original draft, data collection, Writing - review and editing,

Masamitsu Kuwahara: Rephrasing, designing, data collection.

Junji Ando, Riyo Miyata, Masayuki Harada, Saori Kanagawa: Reviewing and editing.

Each author contributed to diagnosis, treatment, and postoperative follow-up of patient. All authors approved the submission of the final version.

Registration of research studies

Not applicable.

Guarantor

Mika Takeuchi.

Provenance and peer review

Not commissioned, externally peer-reviewed.

Declaration of Competing Interest

None.

References

- [1] R.A. Agha, et al., The SCARE 2020 guideline: updating consensus Surgical CAse REport (SCARE) guidelines, *Int. J. Surg.* 84 (2020) 226–230.

- [2] C.P. Virden, M.K. Dobke, Paul Stein, C. Lowell Parsons, D.H. Frank, Subclinical infection of the silicone breast implant surface as a possible cause of capsular contracture, *Aesthetic Plast. Surg.* 44 (2020), <http://dx.doi.org/10.1007/s00266-020-01816-w>.
- [3] R.A. Mladick, "No-Touch" submuscular saline breast augmentation technique, *Aesthetic Plast. Surg.* 17 (1993), <http://dx.doi.org/10.1007/BF00636260>.
- [4] W.P. Adams, E.J. Culbertson, A.K. Deva, M.R. Magnusson, C. Layt, M.L. Jewell, P. Mallucci, P. Hedén, Macrot textured breast implants with defined steps to minimize bacterial contamination around the device: experience in 42,000 implants, *Plast. Reconstr. Surg.* 140 (2017), <http://dx.doi.org/10.1097/PRS.0000000000003575>.
- [5] J. Kelsall, E. Gutteridge, L. Whisker, Salvage of infected breast implants with continuous peri-prosthetic antibiotic irrigation: a retrospective audit, *Eur. J. Surg. Oncol.* (2017), <http://dx.doi.org/10.1016/j.ejso.2017.01.100>.
- [6] S. Franchelli, M. Pesce, I. Baldelli, A. Marchese, P. Santi, A. De Maria, Analysis of clinical management of infected breast implants and of factors associated to successful breast pocket salvage in infections occurring after breast reconstruction, *Int. J. Infect. Dis.* 71 (2018), <http://dx.doi.org/10.1016/j.ijid.2018.03.019>.
- [7] J.B. Cohen, C. Carroll, M.M. Tenenbaum, T.M. Myckatyn, Breast implant-associated infections: the role of the national surgical quality improvement program and the local microbiome, *Plast. Reconstr. Surg.* (2015), <http://dx.doi.org/10.1097/PRS.0000000000001682>.
- [8] S. Franchelli, F. Vassallo, C. Porzio, M. Mannucci, V. Priano, E. Schenone, M.S. Leone, G. Canavese, P. Santi, A. De Maria, Breast implant infections after surgical reconstruction in patients with breast cancer: assessment of risk factors and pathogens over extended post-operative observation, *Surg. Infect. (Larchmt)* (2012), <http://dx.doi.org/10.1089/sur.2011.004>.
- [9] R.O. Darouiche, Treatment of infections associated with surgical implants, *N. Engl. J. Med.* (2004), <http://dx.doi.org/10.1056/nejmra035415>.
- [10] K.Tomita M.Taminato, K. yano, Recovery from an acute infection in the context of tissue expander-based breast reconstruction, *Jpn. J. Plast. Surg.* 62 (8) (2019) 837–846.
- [11] A. Nishibayashi, K. Tomita, Y. Sugio, An analysis of postoperative infection cases in tissue expander breast reconstruction, *Oncoplast. Breast Surg.* 1 (2) (2016) 59–63.
- [12] S.P.H. Bennett, A.D. Fitoussi, M.G. Berry, B. Couturaud, R.J. Salmon, Management of exposed, infected implant-based breast reconstruction and strategies for salvage, *J. Plast. Reconstr. Aesthet. Surg.* 64 (2011), <http://dx.doi.org/10.1016/j.bjps.2011.05.009>.
- [13] C. Ozturk, C.N. Ozturk, M. Platek, A. Soucise, P. Laub, N. Morin, R. Lohman, W. Moon, Management of expander- and implant-associated infections in breast reconstruction, *Aesthetic Plast. Surg.* 44 (2020), <http://dx.doi.org/10.1007/s00266-020-01923-8>.
- [14] C. Tsunashima, S. Kawamura, T. Tokiyoshi, Management of infection following breast reconstruction using a prosthesis, *Oncoplast. Breast Surg.* 2 (3) (2017) 71–77.
- [15] A.M. Rycerz, P. Slack, A.K. McNulty, Distribution assessment comparing continuous and periodic wound instillation in conjunction with negative pressure wound therapy using an agar-based model, *Int. Wound J.* (2013), <http://dx.doi.org/10.1111/j.1742-481X.2012.00968.x>.
- [16] A. Kajikawa, K. Ueda, Y. Katsuragi, S. Iida, Salvage of infected tissue expanders using a new continuous irrigation method with intermittent aspiration, *J. Plast. Reconstr. Aesthet. Surg.* (2009), <http://dx.doi.org/10.1016/j.bjps.2008.09.027>.
- [17] K. Hayashi, A. Kajikawa, Method for remedying infected expander using K-system, *Pepars* 115 (2016) 64–68 [in Japanese].
- [18] M. Higashiyama, H. Daizo, M. Yagishita, K. Shimada, A case of breast reconstruction with surgical site infection controlled after tissue expander insertion using continuous negative pressure and irrigation, *Jpn. J. Plast. Surg.* 61 (12) (2018) 1576–1581.
- [19] J.Y. Cheong, D. Goltsman, S. Warriar, A new method of salvaging breast reconstruction after breast implant using negative pressure wound therapy and instillation, *Aesthetic Plast. Surg.* 40 (2016), <http://dx.doi.org/10.1007/s00266-016-0668-z>.
- [20] F. Meybodi, N. Sedaghat, J. French, C. Keighley, D. Mitchell, E. Elder, Implant salvage in breast reconstruction with severe peri-prosthetic infection, *ANZ J. Surg.* 87 (2017), <http://dx.doi.org/10.1111/ans.13379>.

Open Access

This article is published Open Access at [sciencedirect.com](https://www.sciencedirect.com). It is distributed under the [IJSCR Supplemental terms and conditions](#), which permits unrestricted non commercial use, distribution, and reproduction in any medium, provided the original authors and source are credited.