



## Repair of bone defect of the lateral forefoot by double segment triangular fibula flap with vascular pedicle: A case report

Ruifu Yang, Mingwu Zhou<sup>\*</sup>, Chaofeng Xing, Shimin Li, Li Song, Jia Chen, Yingjie Xiong, Kai Zhang

The 153rd Central Hospital of PLA, Zhengzhou 450042, China

### ARTICLE INFO

#### Article history:

Received 30 September 2017

Revised 10 November 2017

Accepted 12 November 2017

Available online 14 November 2017

#### Keywords:

Fibula

Repair

Lateral forefoot

Bone defect

Surgery

### ABSTRACT

**Objective:** To expound the clinical effect of a new operation by transplanting double segment triangular fibula flap with vascular pedicle to repair the forefoot with lateral bone defect, and to study how to improve the operation method in the following stage. **Methods:** The inclusion criteria: More than 2 phalangeal and metatarsal bones defects of the lateral forefoot, widespread skin and soft tissue defects on pelma and dorsal foot, and destruction of the anterior aspect of foot arch, which seriously affects the foot function. There was one case of clinical application in November 2014. The repairing method is as followed: the harvested vascularized free fibula was cut into 2 segments and then they were folded into a right angle. According to selected control points on the residual metatarsals, an optimal stereo triangular net was constructed. Meanwhile, according to flow-through mode, the free anterolateral thigh flap was incorporated to repair the forefoot and foot arch. **Results:** Postoperative bone flaps all survived. After a 17-month following up, it was found that the grafted fibular healed well, shape of the foot was good, weight-bearing walking was practical, a slight limp and discomfort with plantar pain existed, sensory recovery reached S3 level and functional recovery of weight-bearing walking by forefoot reached W3 level, comprehensive evaluation was good, and there were wear scar and ulcer on the plantar flap during long-time walking for patients, such results were excellent according to foot function scoring criteria. **Conclusion:** In this operation the grafted fibula was fold into a triangle according to actual need, which though not completely restores the tridimensional structure of the longitudinal, transverse arches of the lateral foot makes weight-bearing walking possible, besides, its appearance and function is satisfactory. Such an operation has overcome the shortage of non-tridimensional structure of the transverse arch etc. in traditional operations and it should be an ideal operation in repairing serious defects on the lateral forefoot through further improvement.

© 2017 Production and hosting by Elsevier B.V. on behalf of King Saud University. This is an open access article under the CC BY-NC-ND license (<http://creativecommons.org/licenses/by-nc-nd/4.0/>).

### 1. Introduction

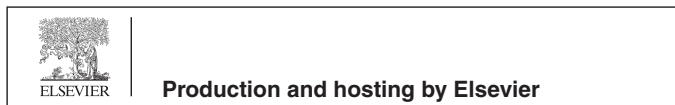The lateral 4, 5th metatarsal of forefoot is one cornerstone for the three-point support balance, also the main component of the lateral longitudinal and transverse arch (Jinfang, 2013). In the clinics, forefoot injury caused by car accidents, mechanical damage is very common. The forefoot damage is mostly due to blunt object hit or mechanical crushing, in which, bone, soft tissue injury is

widespread, the foot loses three point stable fusion, and the function is seriously affected. In the case of severe forefoot defects, tissue transplantation for repair and improvement from the structure can restore the function of foot and restore the patient's ability to live and work. Multiple metatarsal defects should be fully reconstructed if condition allows, but there are a lot of existing problems in reconstruction of the entire forefoot. If total reconstruction is impossible, reconstruction should be done for tibia, calf; and the 1st, 5th metatarsal defects should be reconstructed. Repair of the forefoot defect mainly targets at iliac bone flap, fibular flap, scapular flap, and the specific flap should be selected based on the specific circumstances of the injured. Yunsheng et al. (2013) held that free fibula flap repair is the ideal treatment method for composite tissue defects in forefoot. Our hospital repaired large-area lateral bone defects in forefoot with vascularized fibular flap graft. We found in the process that single transplant could not repair multiple metatarsal lesions at the same time, and weight-bearing walk-

<sup>\*</sup> Corresponding author.

E-mail address: [zmw153@outlook.com](mailto:zmw153@outlook.com) (M. Zhou).

Peer review under responsibility of King Saud University.



ing was impossible. In November 2014, our hospital folded the transplanted fibula to right angles according to certain ratio to repair large-area lateral bone defects in forefoot, so that a stable triangular bone formed, and patients with serious forefoot bone injury restored weight-bearing walking ability. Good clinical efficacy was achieved, which is reported as follows.

## 2. Materials and methods

### 2.1. Clinical data

The 60 years old male patient was the subject. Due to machine crushing in 2014, his right foot had anterior lateral damage, only the first metatarsal and great toe was intact, the 2nd–5th toes were damaged, the third metatarsal was exposed and partially absent, the 4,5th metatarsals were completely absent, the ankle bone to the distal 2nd metatarsal of the dorsal had fibular skin defect in an area of 11 cm × 5 cm, 2 cm from the heel bone to the first metatarsal of the dorsal had fibular skin defect in an area of 10 cm × 8 cm (Figs. 1a and 1b). The arch needed reconstruction to restore the patient's weight-bearing walking ability.

### 2.2. Surgical method

#### 2.2.1. Recipient area preparation

Patient took supine position. After onset of general anesthesia, the operational field was disinfected to thoroughly debride the wound surface, remove the inactivated tissue, repair stump and expose the bone cross section. The dorsalis pedis artery and two companion veins, small saphenous vein revealed in anatomy were chosen as blood supply vessels for the recipient area. The deep peroneal nerve, sural nerve and plantar lateral nerve were chosen as recipient area nerve. By bipedal contrast, bone defect length and skin area were measured and designed. The wound received pressure dressing by complex iodine diluted gauze.

#### 2.2.2. Design of vascularized fibular flap

Vascularized fibular flap design is shown in Fig. 2. Ultrasound Doppler detection of lateral peroneal artery of contralateral calf was performed before the operation for skin perforation and marking. Flap and fibular length was designed based on dorsal wound surface with the marking point as the center. The flap area was 12 cm × 7 cm, and fibular length was 9 cm. Cut off appropriate length of lateral leg nervus cutaneus so that it remains in the flap.

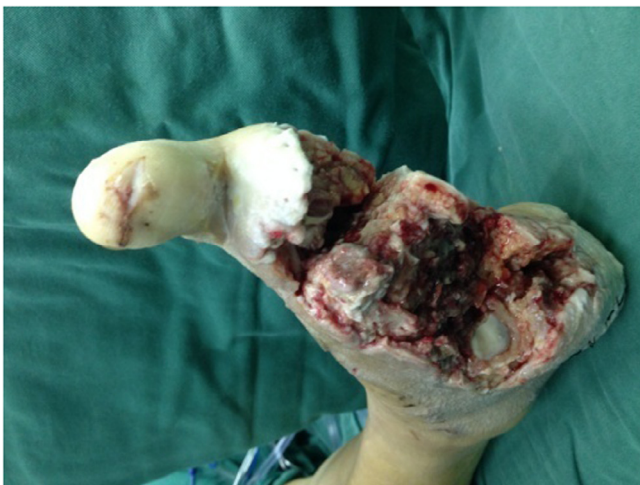

Fig. 1a. Dorsal view of forefoot with large-area lateral bone defect.

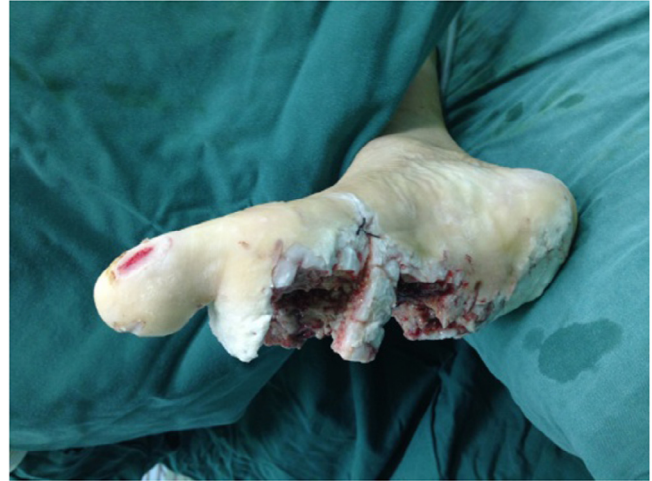

Fig. 1b. Pelma view of foot with large-area lateral bone defect.

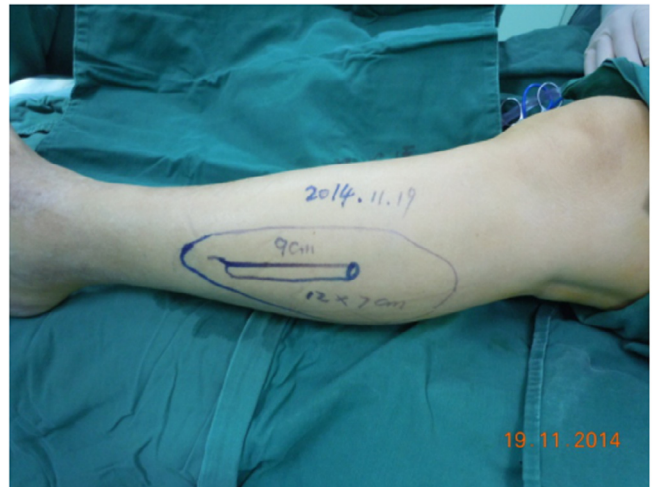

Fig. 2. Design vascularized fibular flap Fig. 3 cut fibular flap.

Find the peroneal artery, vein, peroneal artery perforation and fibular nutrition branch in the posteromedial fibula. Clamp the peroneal artery, vein, to facilitate foot blood supply. Cut off the required fibula with the swing saw according to the design line (Fig. 3), the free fibula shall carry a little muscular sleeve to protect the fibular blood vessel bundle. Dissociate appropriate length of the proximal and distal ends of the fibula arteries and veins to fit proximal and distal ends of descending branch of the dorsal and lateral circumflex femoral artery and vein, so that flow-through flap connecting free anterolateral femoral flap was formed.

#### 2.2.3. Dissociate anterolateral femoral flap

Ultrasound Doppler detection of descending branch of lateral circumflex femoral artery of contralateral calf was performed before the operation for skin perforation and marking. Flap was designed and cut based on dorsal wound surface with the marking point as the center. In area of 12 cm × 10 cm, the flap shall carry tensor fasciae latae to increase the plantar thickness, enhance wear resistance of the flap. The proximal and distal ends of descending branch of lateral circumflex femoral artery and vein were protected during the operation. Dissociate appropriate length of lateral femoral nerve for standby use (Fig. 4).

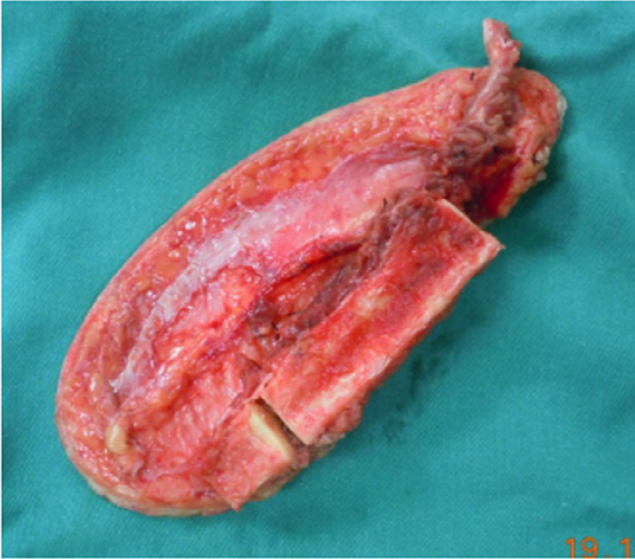

Fig. 3. Cut fibula flap.

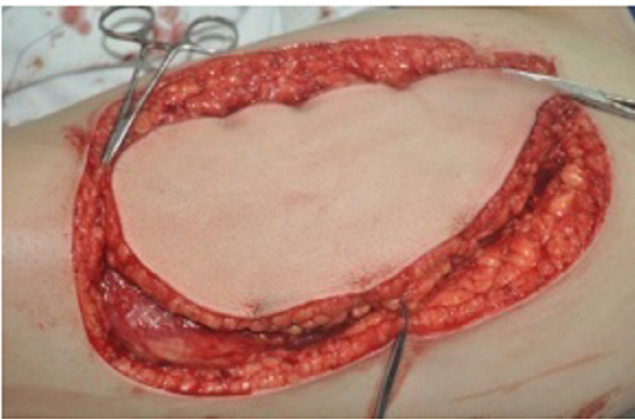


Fig. 4. Anterolateral thigh flap.

#### 2.2.4. Recipient area bone fixation and wound repair for vascularized fibular flap shift

Maintain the integrity of fibular vascular periosteum muscular sleeve after the cut, cut the fibula with swing saw at the design

point 3 cm away from the distal end, and fold the two segments of fibula into a right angle towards the periosteal side (Fig. 5). Insert the proximal fibular flap into the tarsal bone with 1.5 g Kirschner to replace the fifth metatarsal, fix the other right angle and the medial remaining third metatarsal to form a transverse arch for bony support repair (Fig. 6). In the fixation process, the three-dimensional structure position of the reconstructed fifth metatarsal head should be adjusted according to the contralateral arch. Upward and sagging which affect the repair effect are not allowed. Under the microscope, the proximal end of peroneal artery and vein shall fit the dorsal foot artery and vein, the distal end of the peroneal artery and vein shall fit descending branch of lateral circumflex femoral artery and vein, small saphenous vein of peroneal artery flap and lateral leg nervus cutaneus shall fit the dorsal vein and deep peroneal nerve respectively, anterolateral femoral flap superficial vein and the femoral lateral nerve shall fit the saphenous vein of lateral malleolus and sural nerve respectively. Cover the fibular flap to repair dorsal foot, cover the anterolateral femoral flap to the repair the pelma. Close the wound.

### 3. Results

In this case, all the flaps survived. Callus growth can be seen 6 months after the fracture in postoperative x-ray review. Basic healing was achieved after 12 months, with right contraposition (Fig. 6). The transverse and longitudinal arch shape basically restored, with partial ability of weight-bearing walking restored. Sensory training began since the 2nd week after the tissue flap healing to promote sensory recovery of tissue flap. Deep foot pain sensory restored 3 months after the surgery, pain and part superficial sensory restored after 6 months; foot pain and tactile sensory restored 1 year after the surgery, with sporadic epicritic sensibility and sensory function at S3 level. Fractures underwent bone healing, foot shape was good, weight-bearing walking was practical, there was slight limp. The old patient had a heavy weight, and resumed job early after the surgery, walked a lot, so forefoot skin ulcers appeared. The wound surface healed completely after rest and medical prescription change. The patient had obvious pain discomfort in the heel after tired walking, with plantar flap weariness, ulcers. The patient's weight-bearing walking ability restored to W3 level. The comprehensive score according to [Jinfang et al. \(2002\)](#) evaluation indicator for heel function reconstruction is fine, and the repair effect is satisfactory (Figs. 7–9).

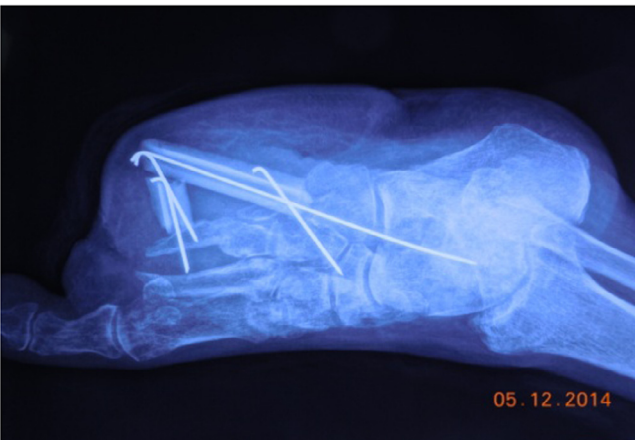

Fig. 5. Fixation of bone graft.

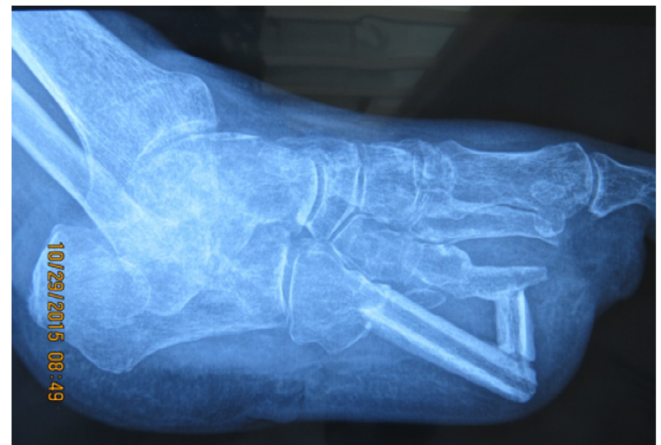

Fig. 6. Healing of bone graft.

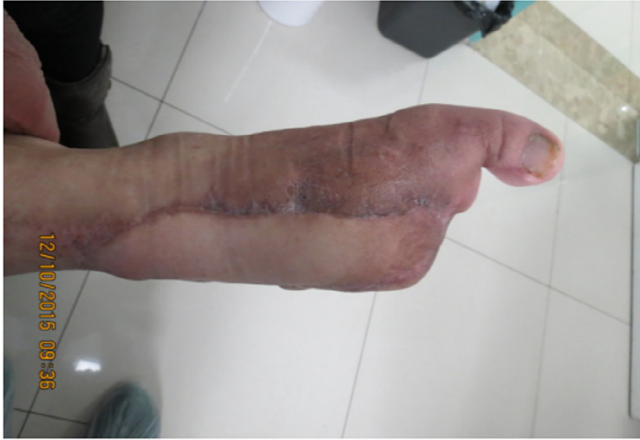

Fig. 7. Healed dorsal.

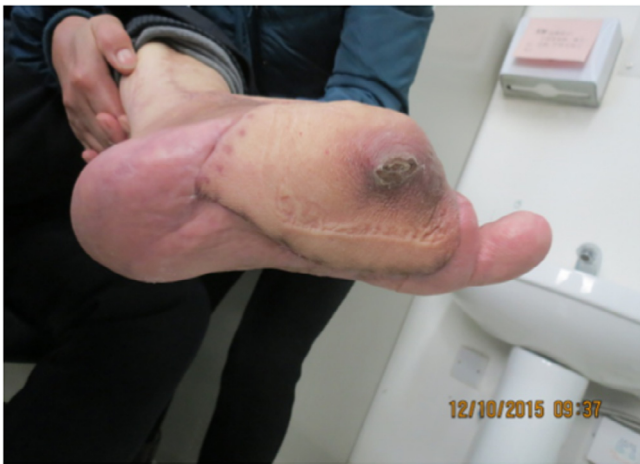

Fig. 8. Rupture occurs in early healing of pedicle.



Fig. 9. Weight-bearing walking after 1 year.

#### 4. Discussion

##### 4.1. Selection of reconstruction method for arch of forefoot with lateral bone defect

Lateral longitudinal arch of the foot can be divided into front, middle and rear. The front is involved in the formation of transverse foot arch. The rear is the heel, which unites with the medial foot arch as the important structure for standing of the body. The three arches are connected in pairs to form a support triangle, an important structure for weight-bearing standing and stability of the body. [Xin et al. \(1998\)](#) used pressure-sensitive film method in study and concluded that: 5 metatarsal heads play an important role in the weight-bearing structure, and bear a different proportion of the weight in different gaits, with the most on 1st, 5th metatarsal heads. Any metatarsal (head) defect can cause foot stability imbalance and arch structure changes, thus affecting the foot function. [Shupei \(1998\)](#) used computer and software technology to study normal foot and biomechanical changes in foot after metatarsal defect: any function, morphological changes in transverse foot arch will cause weight distribution abnormalities in metatarsal head, leading to forefoot pain in weight-bearing walking and walking abnormality. It can be seen that metatarsal head defects have a great impact on the foot function, and thus must be reconstructed. Due to the complex structure of lateral longitudinal arch and bone, nerve vessels, plantar soft tissue, ligament as a functional unit in deficiency, reconstruction is difficult. Doctors not only need to reconstruct solid bone stent, but also establish thick, flexible foot soft tissue layer and skin with good sensory and blood circulation. In metatarsal head defects, especially the first or fifth metatarsal defect, vascular ilium or fibular transplantation is generally adopted, or tandem transplantation with vascular bone and vascular free flap is also practical in repair ([Wang et al., 2000](#)). For smaller first metatarsal head defects combined with skin defects, perforation of geminate composite tibial skin flap with free medial posterior tibial artery of the calf can be adopted to repair the first metatarsal and soft tissue defects ([Ruifu et al., 2014](#)). For repair and reconstruction of lateral large-area bone defect in forefoot, ipsilateral fibular shifting transplantation with vascular pedicle is commonly used for repair and reconstruction. Fibula is strong, firm and relatively long, can bear weight, and appropriate osteotomy length has small effect on recipient area joints. Therefore, the free fibula can be folded in transplantation to repair multiple metatarsal defects, or larger bone defects in other parts ([Riedel et al., 2012](#)). The shortcoming is that it is difficult to completely repair the foot structure, rebuild the transverse arch in case of multiple metatarsal defects, only frame can be reconstructed. [Rajacic et al. \(1993\)](#) reconstructed the foot bone – skin after severe trauma with fibular flap in vascular anastomosis. Fibula was chosen to replace the first metatarsal bone defect part according to the observed similarity between fibula and metatarsal, and fibular flap grafting was combined according to the size of foot soft tissue defects. For multi-metatarsal defects, [Yuanhui et al. \(2015\)](#) transplanted vascularized free iliac bones and flaps for reconstruction and achieved ideal effect, as patients achieved a high rate of excellence regardless of appearance and function. However, flap with relatively long pedicle vessel and larger branch should be selected for the sake of connection with pedicle of the iliac bone or coincide joint at the side. Due to the big technical difficulty and risk, failure at any step or concurrent infection and other complications can lead to the failure of the entire reconstruction project.

#### 4.2. The advantages of repair of bone defect of the lateral forefoot by fibula flap with vascular pedicle

Fibula flap with vascular pedicle supports large-area cutting, as all the fibula can be cut except the lower 1/4 part. The flap is in good, not bloated shape. It carries lateral sura nervus cutaneus, which facilitates sensory recovery. As it can carry part of soleus muscle and flexor hallucis longus for repair of the cavity, postoperative benefits include good shape and strong anti-infection ability. The fibula is composed of hard tubular cortical bone, which helps weight-bearing ability and foot function recovery. The tissue flap does not damage the main blood vessels of the lower limbs, also vessel pedicle has equivalent size as the recipient area artery and vein, the flap artery and vein has balanced circulation after the transplantation, which meets the requirements of physiological blood supply. Soldado et al. (2012) found that repair of large bone defects in the limbs with vascularized fibular transplantation could effectively promote bone healing. Some scholars (Takazawa et al., 2011; Gao et al., 2017a; Gao et al., 2017b) believed that vascularized fibular transplantation can significantly promote bone non-union healing as it improves the surrounding soft tissue conditions. We believe that lateral longitudinal foot arch has small arc; relative flatness, and thus suitable for relatively straight fibular graft, while medial longitudinal arch has large arc, thus suitable for graft with iliac bone in similar curvature. Repair of lateral bone defects in forefoot with vascularized fibula can effectively promote bone healing, which is conducive to weight-bearing ability and foot function recovery.

#### 4.3. Intraoperative, postoperative attentions

##### 4.3.1. The patient in the case had multiple metatarsal, skin defects

Use of only one flap causes too large harm to the recipient area, while use of two flaps in series connection can reduce recipient area damage. Fibular flap with vascular pedicle has thin skin soft tissue, thick blood vessels, thus suitable for repairing the dorsal and can form flow-through flap to connect the anterolateral femoral flap; the anterolateral femoral flap has thick tissue after carrying tensor fasciae latae, so it is more similar to the pelma with relatively good wear resistance, thus suitable for pelma repair.

##### 4.3.2. The recipient area sensory nerve should be properly treated during flap removal

Dissociate sufficient length of lateral leg nervus cutaneus and lateral femoral cutaneous nerve, which shall be in end-to-end anastomosis with the fine end of deep peroneal nerve at the dorsal and sural nerve at lateral malleolus respectively after transplantation, so that forefoot skin sensory can be restored. The patient in this case had unsatisfactory nerve recovery due to his old age, obesity, more postoperative activities. The pelma had rupture in early walking, which was healed after treatment. Therefore, early postoperative activity amount for such type of patients should be appropriate, and certain protective measures should be taken.

##### 4.3.3. As the foot position is low, venous anastomosis is needed not only for accompanying vein, but also superficial vein of flap, to increase blood flow channel, and reduce lower extremity edema

The small saphenous vein of peroneal artery flap and superficial vein of anterolateral femoral flap should fit the affected dorsal vein and small saphenous of affected lateral malleolus respectively.

##### 4.3.4. The foot arch as an important structure of foot bearing and cushioning has very complicated three-dimensional structure

During the reconstruction and fixation, the three-dimensional structure position of the reconstructed fifth metatarsal head should be adjusted according to the contralateral arch data. No

upward or sagging is allowed. The plane formed by 1st, 5th metatarsal head and calcaneus weight point should be parallel with the ankle joint horizontal plane at functional position. Otherwise, the repair effect will be affected. Patient should wear a special foot arch pad after the operation to maintain the three-dimensional structure of the foot arch. The foot bearing point should be frequently changed by equipment to avoid the arch collapse and skin ulceration.

#### 4.4. Problems to be solved in lateral forefoot reconstruction

The shape of fibular flap with fibular pedicle cannot fully match the forefoot arch, and much adjustment is needed especially in the repair of medial foot arch defects. Fibular head transplantation for single first metatarsal defect achieved good effect. Due to the special anatomical structure of forefoot, the bone defects are often accompanied by defects in the skin and soft tissue. In fibular head transplantation, the recipient area suffers great injury and it is difficult to carry flap to repair the complex tissue defect of the forefoot. In repair of forefoot bone injury, only single transplantation is possible, and repair of multiple metatarsal defects is impossible. In this case, multiple metatarsal defects need to be folded into triangular to replace the multiple metatarsal and repair vertical and horizontal foot arch frame. Still, it is difficult to simulate the vertical and horizontal arch arc and dynamic buffer structure.

In this study, repair of most of the bone and soft tissue defects in the lateral forefoot was performed with vascularized fibular flap graft, with good effect achieved. The patient basically restored weight-bearing function and part of walking function. Moreover, the foot appearance was fine, there being no influence on shoe wearing. However, the transplanted flap sensory recovery was not ideal, the skin sliding was huge, with poor wear resistance and prone to weariness. Therefore, it is not only necessary to solve soft tissue problems such as wear resistance, sliding and nerve innervation of transplanted skin, but also solve the problem of restoration of bone structure, foot arch structure of supporting point, to maximally restore the foot function. In the next step, further study and evaluation is needed for postoperative biomechanical conditions of affected foot.

## 5. Conclusion

The new operation for repair of bone defect of the lateral forefoot by double segment triangular fibula flap with vascular pedicle overcomes the shortcomings of traditional technique without three-dimensional frame for transverse arch. It reconstructs the three-dimensional frame of longitudinal and transverse foot arch, so that patients restore weight-bearing walking ability. With satisfactory shape and function, it has achieved good clinical curative effect as an ideal technique for repairing severe defect of lateral forefoot.

## Funding

Key Program of Science and Technique Plan in Henan (Grant: 102102310002); Jinan Military Region Logistical Scientific Research Program (Grant: CJN14J015).

## References

- Gao, W. et al., 2017a. The first multiplication atom-bond connectivity index of molecular structures in drugs. *Saudi Pharmaceut. J.* 25 (4), 548–555.
- Gao, W. et al., 2017b. Characteristics studies of molecular structures in drugs. *Saudi Pharmaceut. J.* 25 (4), 580–586.
- Jinfang, C., 2013. Personalized design for reconstruction in longitudinal arch defect of lateral foot. *Orthopedic. J. China* 06, 531–532.

- Jinfang, C., Zihai, D., Zhongwei, C., 2002. *Micro-Foot Surgery*. Shandong Science and Technology Press. 217.
- Rajacic, N., Ebrahim, M.K., Grgurinovic, S., Starovic, B., 1993. Foot reconstruction using vascularised fibula. *Br. J. Plast Surg.* 46 (4), 317–321.
- Riedel, B., Franklin, C., Seal, A., et al., 2012. Free vascularized fibula graft to treat chondroblastoma of the hip. *Orthopedics* 35 (2), e259–e261.
- Ruifu, Y., Mingwu, Z., Chaofeng, X., et al., 2014. Repair of the first metatarsal head and soft tissue defects by perforation of twin composite flap with free posterior tibial artery. *Pract. J. Med. Pharm.* 31 (1), 13–15.
- Shuipei, W., 1998. Biomechanical experiment and clinical study of reconstruction of forefoot defect with fibular head composite flap. *J. Med. Biomech.* 13 (2), 124–129.
- Soldado, F., Fontecha, C.G., Barber, I., et al., 2012. Vascularized fibular periosteal graft: a new technique to enhance bone union in children. *Pediatr Orthop.* 32 (3), 308–313.
- Takazawa, A., Matsuda, S., Fujioka, F., et al., 2011. Split tibia vascularized fibular graft for congenital pseudarthrosis of the tibia: a preliminary report of 2 cases. *Pediatr Orthop.* 31 (4), e20–e24.
- Wang, J.L., Fu, X.M., Wang, C.Q., Tian, Q.Y., Zhang, S.M., Zhang, Z.Y., Liu, G.J., 2000. Vasculariliac bone incorporating free flap transfer for reconstruction of defects of metatarsal and forefoot. *Zhonghua Xianwei Waike Zazhi (Chin J Microsurg)* 23, 180–181.
- Xin, M., Xiangjie, G., Huangyuan, H., et al., 1998. Biomechanical significance of three-dimensional shape of transverse foot arch. *Chin. J. Orthopaed.* 09, 17–20.
- Yuanhui, L., Yunfa, Y., Hansheng, H., et al., 2015. Repair of large segmental bone defect in limb with vascularized fibular graft: bone healing can be effectively promoted. *J. Clin. Rehabil. Tissue Eng. Res.* 19 (11), 1641–1646.
- Yunsheng, T., Zhaojie, W., Chong, L., Chao, Z., Feng, C., Meng, W., 2013. Repair of complex tissue defect of forefoot with free fibular flap. *Chin. J. Reparat. Reconstruct. Surg.* 27 (3), 11–12.