

Received: 2010.03.15  
Accepted: 2010.03.31

## Personal experiences in direct ultrasound-guided injection of thrombin into the lumen of pseudoaneurysm as a method of treatment in case of iatrogenic femoral artery damage

Joanna Słonina<sup>1</sup>, Marta Obremaska<sup>2</sup>, Urszula Zaleska-Dorobisz<sup>1</sup>, Anil Agrawal<sup>3</sup>,  
Joanna Malczewska<sup>1</sup>, Urszula Koźmińska<sup>1</sup>, Marek Sasiadek<sup>1</sup>

<sup>1</sup> Department of Radiology, Wrocław Medical University, Wrocław, Poland

<sup>2</sup> Department of Cardiosurgery, Wrocław Medical University, Wrocław, Poland

<sup>3</sup> 3<sup>rd</sup> Department and Clinic of General and Oncological Surgery, Wrocław Medical University, Wrocław, Poland

**Author's address:** Joanna Słonina, Department of Radiology, Wrocław Medical University, Curie-Skłodowskiej 24A Str., 50-369 Wrocław, Polska, e-mail: joanna.slonina@post.pl

### Summary

**Background:**

Pseudoaneurysms constitute a quite common complication of procedures requiring puncture of the common femoral artery. The risk factors of the condition include: obesity, arterial hypertension, sex (more prevalent in males) as well as antithrombotic therapy.

**Material/Methods:**

The US-guided injection of thrombin into the pseudoaneurysm lumen was performed in patients referred from the Department of Invasive Cardiology who had undergone coronarography or coronary angioplasty. Pseudoaneurysms constituted the complication of common femoral artery cannulation. After setting the diagnosis of pseudoaneurysm by means of Doppler ultrasound, patients with large pseudoaneurysms of volume exceeding 10 mm were qualified for thrombin injection. Generally, 33 patients underwent the treatment. In 3 cases – due to the presence of multicellular pseudoaneurysm – thrombin was administered twice.

**Results:**

Taking into account the safety of the procedure, ultimately 33 patients were qualified for thrombin administration, in whom aneurism of diameter exceeding 10 mm was diagnosed. In 3 patients with aneurysm of less than 10mm, only a compression band was used prophylactically. In one case, because of a considerable oedema surrounding the tissue, as well as deep location of the aneurysm in the groin, thrombin treatment was not given due to technical reasons. In 30 cases, single administration of thrombin was effective and resulted in a complete thrombosis of the pseudoaneurysm lumen within a couple of seconds following thrombin injection. In 3 patients with multicellular aneurysm, thrombin was given twice, resulting in a total obliteration of the pseudoaneurysm in two cases only.

**Conclusions:**

No complications were observed after the performed procedures. No recanalisation of pseudoaneurysms was demonstrated in follow-up examinations.

1. Direct thrombin injection into the pseudoaneurysm lumen can constitute an alternative method of treatment for open surgical techniques. 2. The procedure is highly effective, cheap and minimally invasive.

**Key words:**

iatrogenic pseudoaneurysm • thrombin • Doppler ultrasonography

**PDF file:**

<http://www.polradiol.com/fulltxt.php?ICID=878514>

## Background

Pseudoaneurysms constitute a quite common complication after procedures requiring puncture of the common femoral artery. The risk factors of this condition include: obesity, arterial hypertension, sex, and antithrombotic therapy [1–3].

A low-invasive method of aneurysm obliteration is the US-guided injection of thrombin into its lumen [3,4]. Such a treatment was introduced in our Department in 2006 and has led to a considerable decrease in the number of performed surgical procedures since.

## Aim of the work

The aim of the work was to evaluate the efficacy of the US-guided injection of thrombin into the lumen of the femoral artery pseudoaneurysm, which formed after diagnostic and therapeutic procedures in patients with cardiological conditions. The obtained USG images allowed for identification of the features of pseudoaneurysms on the basis of which it was possible to form criteria of application of that treatment procedure.

## Material and Methods

Pseudoaneurysms of the femoral artery were diagnosed in 37 patients (28 women and 9 men, mean age 62.7 years) hospitalised at the Department of Cardiology and Cardiosurgery in the years 2006–2009 and subjected to coronarography or coronary angioplasty. Pseudoaneurysms constituted complication of femoral artery cannulation.

Physical examination at the site of femoral artery puncture revealed oedema and skin reddening in most of the cases. Patients reported severe pain of the inguinal area and of the lower limb.

Every patient was then subjected to an ultrasound examination of the inguinal area with a Voluson 740 GE ultrasound scanner, linear probe, broadband high resolution (7–12 MHz) in grey-scale mode and with the use of Doppler options.

After revealing the presence of the pseudoaneurysm and identification of its morphological features (volume, presence of septa), the blood flow within the aneurysm was evaluated and patients were qualified for thrombin treatment. The scheme of thrombin injection was established on the basis of the literature [1–3]. With the use of the available literature data, it was possible to establish the dosage, i.e. the number of bovine thrombin units injected to the lumen of the pseudoaneurysm. This number depended on the size of the aneurysm mainly, and its morphological features. In the examined cases, the injected amount of thrombin ranged from 400 to 800 units, on average. The most significant criteria of choice included the size of the aneurysm in mm (above 10 mm), its width, and the length of its neck, with a visible blood inflow (Table 1).

## Results

Taking into consideration the safety of the procedure, 33 patients with an aneurysm of more than 10 mm in

**Table 1.** Parameters of pseudoaneurysms.

	Minimal dimension in mm	Maximal dimension in mm	Mean dimension in mm
Study group (N=33)	10	8.2	4.2

**Table 2.** Types of pseudoaneurysms in the study group.

	One-cavity	Multicellular
Number (N=37)	34 (91.8%)	3 (8.1%)

**Table 3.** Age of patients from the study group.

	Age	Range
Study group I (N=37)	62.7 years	53–83 years

**Table 4.** Results obtained after thrombin injection.

	I injection of thrombin resulting in obliteration	II injection of thrombin resulting in obliteration	No positive results – surgical treatment
Study group (N=33)	30 (90%)	2 (6%)	1 (3%)

diameter were qualified for thrombin injection. In three cases, in which the size of the aneurysm was small, i.e. below 10 mm, a conservative treatment was introduced with the use of a compression band. In one patient, due to a considerable oedema of the surrounding tissues and a deep location of the tumour in the inguinal area, the thrombotic treatment was withheld for technical reasons.

In 30 patients, a one-course treatment was successful and resulted in thrombus formation in the lumen of the pseudoaneurysm after a few seconds from thrombin administration. In 3 individuals, due to the presence of a multicellular aneurysm, thrombin was injected twice. This led to a full obliteration in two cases only. After an unsuccessful two-fold administration of thrombin, one patient was referred for a surgical procedure. The reason for this failure was a short and a wide neck of the aneurysm, which, on USG Doppler, showed a constant blood inflow into the aneurysm, leading to its volume increase.

No patient revealed any complications of the performed thrombin injections. In the follow-up ultrasound examinations, often performed by us on the 1<sup>st</sup>, 2<sup>nd</sup>, and 3<sup>rd</sup> day after the procedure (in the early days of method application), no recanalisation of pseudoaneurysms was found. The last ultrasound evaluation, usually performed after 3 weeks from the day of the procedure, tended to show a full resorption of the pseudoaneurysm (Tables 1–4).

## Discussion

Coronary diagnostics and cardiosurgery are commonly performed nowadays in cardiological cases. The most frequent complications include the formation of pseudoaneurysms of the femoral artery after its cannulation. The incidence amounts to 0.1–5.5% of the procedures of cardiac catheterisation [2,4]. According to some other authors, this is as much as 7.7% [3–5]. Statistically, this is a rare complication, but due to a steadily increasing number of endovascular procedures, the absolute number of such complications rises as well. Other possible complications include haematomas, arteriovenous fistulas, peripheral artery embolisms.

Among multiple factors promoting the formation of pseudoaneurysms, there are: female sex, obesity, hypertension, puncture of the femoral artery and vein at the same time, difficulties in a proper compression of the injection site, extensive calcifications in the arterial wall, antithrombotic therapy, hemodialysis [5,6].

Currently, the easiest diagnostic method of this complication is Doppler US. The examination is easy to perform, even in patients with a large oedema and pain in the lower limb. In ultrasound image visualisation, pseudoaneurysms are presented by fluid spaces located in soft tissues and communicating through their neck with an artery. Doppler examination reveals blood flow within vessels. The surrounding tissues are mostly oedematous and are frequently accompanied by the presence of single or multiple haematomas.

According to the anatomical classification, pseudoaneurysms can be divided into single- and multicellular ones. Ultrasound examination allows for a precise determination of the aneurysm size and volume, as well as visualisation of the pseudoaneurysm neck, its course, length and width. The length and width of the aneurysm neck is a prognostic factor in evaluation of the evolution of changes within the aneurysm [5].

Treatment of pseudoaneurysms is necessary due to the possibility of multiple complications connected with rupture and haemorrhage, as well as because of severe pain reported by patients, compression on the femoral nerve, or even the dysfunction of the lower limb.

The hitherto prevailing treatment of femoral artery pseudoaneurysms was mostly conservative and included the use of a mechanical compression or, in some particular cases, performance of surgery, which is always connected with a higher risk of complications.

Thrombin used for pseudoaneurysm obliteration has substantially reduced the number of the performed procedures, shortened the time of patients' hospitalisation, and significantly reduced their pain. First reports on the effectiveness of thrombin injected into the lumen of the pseudoaneurysm for its obliteration are dated 1986 and were presented by C. Cope and R. Zeit [7].

Bovine thrombin is a polypeptide which is formed from prothrombin activated by calcium ions, factor Xa, Va and

phospholipids. Thrombin is an active enzyme converting fibrinogen into fibrin and leading to thrombus formation. Administration of exogenous fibrin also exerts the transition of fibrinogen into fibrin, leading to thrombus formation [8,9].

The easiness of thrombin administration depends on a few factors. The depth of the aneurysm defines application of a proper injection set. The number of the aneurysm cavities diagnosed on US determines the success of the surgical procedure after one injection of thrombin. Sometimes, multicellularity of the aneurysm requires injection into every cavity. Some other time, a substantial oedema of the surrounding tissues, as well as the presence of haematomas hinders the injection.

These are the most frequent difficulties with the performance of this simple procedure. The effectiveness of thrombin injections into the aneurysm lumen ranges, according to different studies, from 90 to 100% [7–10]. Complications include procedure inefficacy and the necessity of surgery. Other complications, such as allergic reactions to bovine thrombin and arterial embolism due to thrombin penetration into the arterial lumen, are extremely rare. Some authors recommend filling the cavity of the aneurysm with physiological saline in order to improve the safety of the procedure and to confirm the presence of the needle inside the aneurysm [10]. In our studies, this method was used several times to facilitate visualisation of the needle inside the aneurysm.

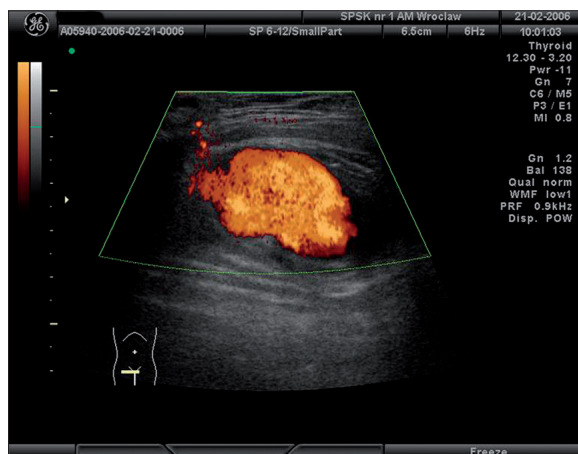
There are not many reports on complications in the form of venous thrombosis. Authors point to the possibility of thrombosis caused by the compression of the pseudoaneurysm on veins. Hung et al. described two requiring surgery cases of deep vein thrombosis being the result of compression on the saphenous vein, caused by pseudoaneurysm obliterated with thrombin. [11].

Complication in the form of peripheral thrombosis, present in one patient out of 186 subjected to obliteration, was described by Kłopotowski et al. However, in this case, symptoms resolved on their own, without the necessity of pharmacotherapy. Rare complications include the formation of an abscess at the point of puncture [12,13].

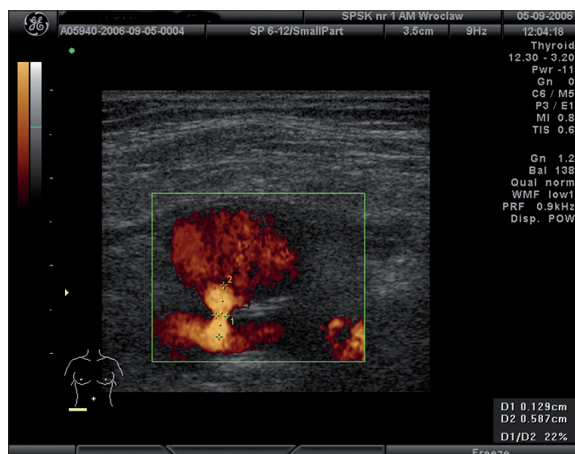
Pope and Johnson, on the other hand, described two cases of anaphylactic reaction after thrombin administration, which were successfully treated with hydrocortizol [14].

Ultrasound examination is helpful in the evaluation and qualification of femoral artery pseudoaneurysms for surgery, when thrombin administration is impossible. Surgery for pseudoaneurysm is recommended in cases of a rapid increase of the aneurysm volume, symptoms of peripheral ischaemia caused by compression on the femoral artery, neuropathy caused by compression on the femoral nerve, features of pseudoaneurysm infection and ineffectiveness of transdermal surgeries [5].

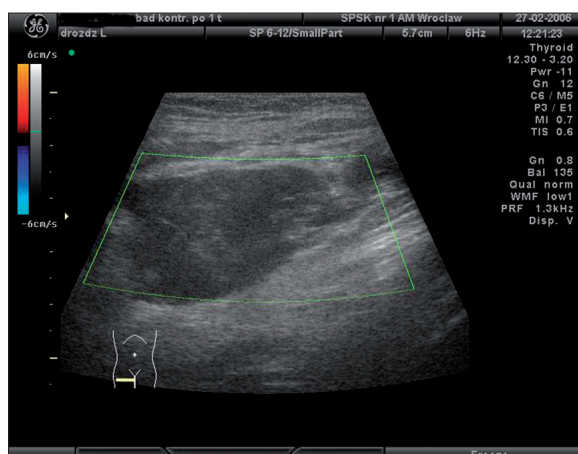
In our material, we performed a successful obliteration of the pseudoaneurysms in 33 cases (96%). These procedures were introduced a few hours after diagnosing



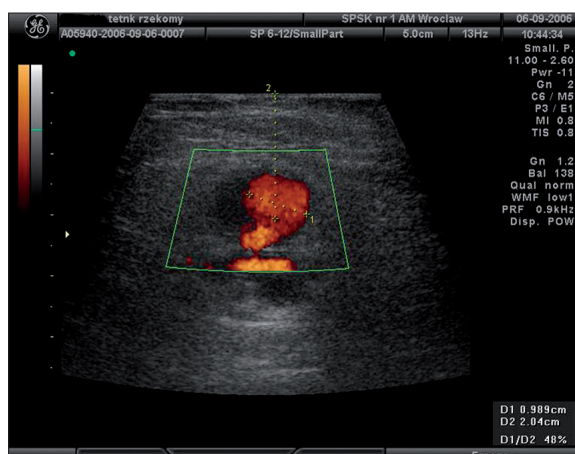
**Figure 1A.** Picture of pseudoaneurysm in power Doppler.



**Figure 2A.** Pseudoaneurysm with a visible short neck.



**Figure 1B.** Thrombosis in the cavity of the aneurysm after thrombin administration.



**Figure 2B.** Partial obliteration of pseudoaneurysm after the first thrombin injection.

pseudoaneurysm. Under US guidance, we injected thrombin into the lumen of the pseudoaneurysm, at a rate of 5–10 seconds and obtaining a fast coagulation. The lumen of the aneurysm was being filled with thrombus in up to approx. 10 seconds. Next, with the use of Doppler techniques, we evaluated the presence of the blood flow. It was absent in most of the cases. The mode of thrombin administration depended on the size of the aneurysm. Fast coagulation was achieved in small aneurysms, of 10–30 mm in diameter, and in aneurysms with a long neck. Such an anatomical structure is connected with the lowest possible risk of thrombus penetration into the systemic circulation (Figures 1A,B, 2A,B).

In the early days of these procedures, frequent monitoring of the results of thrombin injection (1<sup>st</sup>, 2<sup>nd</sup>, and 3<sup>rd</sup> day) resulted from our lack of any experience in the application of this method and from our concern for its effectiveness. With time, we abstained from such a frequent monitoring and developed our own scheme of action. On the basis of those own experiences, it seems that a follow-up examination on the first day after the procedure is sufficient, especially in case of small, one-cavity aneurysms.

In case of multicellular aneurysms and those with a short neck, ultrasound examination should be performed on the second day as well.

After a thorough analysis of all cases subjected to treatment with US-guided thrombin injection, the effectiveness of this method was rated as high, i.e. for 96%, which may be confirmed by multiple reports from other Polish and foreign centers applying a similar method of treatment of the femoral artery pseudoaneurysms, with a high rate of successful obliterations, amounting to 93–100% [1,15]. We did not find any complications during thrombin administration, and the recovery time was significantly shorter than in case of surgeries.

The most significant result of the treatment was the nearly immediate pain relief. Still, the most difficult procedures are the ones with aneurysms located deep in the groin, with a poorly visible neck, which reduces the safety of the procedure. A detailed action plan should be developed for large aneurysms as well (of >50 mm in diameter, with a short neck). There is always a risk of thrombus in the femoral artery. Other issue to work on is the identification of morphological and clinical features predisposing to the development of iatrogenic aneurysms during different diagnostic and therapeutic procedures, such as the evaluation of atherosclerotic lesions in the femoral artery. In the Polish literature, there appeared multiple reports on that issue [5,6,10].

In our work, due to a low number of performed thrombin injections, we did not refer to any control group, to compare

the effectiveness of the method in relation to surgical procedures [16]. Such studies will be possible due to the continuation of this method, i.e. a non-invasive treatment of pseudoaneurysms of the femoral artery with the use of thrombin.

## Conclusions

1. A direct injection of thrombin into the pseudoaneurysm lumen may be an alternative for surgeries.

2. This is a successful, cheap and minimally invasive method.
3. It is quite fast in eliminating pain present during the formation of the pseudoaneurysm.
4. It substantially reduces the time of hospitalisation.

## References:

1. Paulson EK, Nelson RC, Mayes CE et al: Sonographically guided thrombin injection of iatrogenic femoral pseudoaneurysms: further experience of a single institution. *AJR*, 2001; 177: 309–16
2. Krüger K, Zachringer M, Strohe H et al: Postcatherization Pseudoaneurysm: Results of US-guided Percutaneous Thrombin Injection in 240 Patients. *Radiology*, 2005; 235: 1104–10
3. Katzenschlager R, Ugurluoglu A, Ahmadi A: Incidence of pseudoaneurysm after angiography. *Radiology*, 1995; 195: 463–66
4. Morgan R, Belli A-M: Current Treatment Methods for Postcatherization Pseudoaneurysms. *JVIR*, 2003; 14: 697–710
5. Lewandowski P, Wąsek W, Budaj A: Jatrogenne tętniaki rzekome – leczenie metodą iniekcji trombin pod kontrolą ultrasonografii. *Kardiol Pol*, 2008; 66: 775–80
6. Kaźmierski M, Iwiński J, Kozakiewicz K et al: Tętniak rzekomy tętnicy udowej – występowanie i doświadczenia własne w leczeniu. *Folia Cardiologica*, 2006; 13: 419–22
7. Cope C, Zeit R: Coagulation of aneurysms by direct percutaneous thrombin injection. *AJR AM J Roentgenol*, 1986; 147: 383–87
8. Morgan R, Belli AM: Current Treatment Methods for Postcatherization Pseudoaneurysms. *J Vasc Intervent Rad*, 2003; 14: 697–710
9. Elford J, Burrell C, Roobottom C: Ultrasound guided percutaneous thrombin injection for the treatment of iatrogenic pseudoaneurysms. *Heart*, 1999; 82: 526–27
10. Wojtarowicz A, Lewandowski M, Płońska E: Ultrasonografia z użyciem kontrastu – metoda zwiększająca bezpieczeństwo obliteracji trombiną tętniaka rzekomego po nakłuciu tętnicy udowej. *Kardiologia Polska*, 2005; 63: 6
11. Hung B, Gallet B, Hodges TC: Ipsilateral femoral vein compression: a contraindication to thrombin injection of femoral pseudoaneurysms. *J Vasc Surg*, 2002; 35(6): 1280–83
12. Kłopotowski M, Kukuła K, Mączyńska R et al: Zamykanie jatrogennych tętniaków rzekomych tętnicy udowej metodą przezskórnego podania trombin pod kontrolą ultrasonograficzną – wyniki obserwacji krótkoterminowych. *Post Kardiol Inter*, 2009; 3(17): 129–36
13. Orawczyk T, Urbanek T, Biolik G: Obliteracja tętniaków rzekomych tętnicy udowej przy użyciu trombin – doświadczenia własne. *Chirurgia Polska*, 2004; 6(1): 7–18
14. Pope M, Johnston KW: Anaphylaxis after thrombin injection of a femoral pseudoaneurysm. Recommendation for prevention. *J Vasc Surg*, 2000; 32: 289–98
15. Paulson EK, Sheafor DH, Kliever MA et al: Treatment of iatrogenic femoral arterial pseudoaneurysms; comparison of US-guided thrombin injection with compression repair. *Radiology*, 2000; 215: 403–8
16. Dratwiczki M, Sankowski A, Gorczyca-Wiśniewska E et al: Leczenie jatrogennych tętniaków rzekomych tętnicy udowej za pomocą wstrzykiwań trombin. *Ultrasonografia*, 2008; 8(34): 51–60