

# A verrucous plaque on the lower leg

Sarina Drusinsky<sup>1</sup>, Karan Lal<sup>2</sup>, Faisal Hamid<sup>3</sup>, Viktoriya Kazlouskaya<sup>4</sup>

1 Dermatology practice, East London, South Africa

2 New York College of Osteopathic Medicine, New York, USA

3 Jamaica Hospital Medical Center, New York, USA

4 Ackerman Academy of Dermatopathology, New York, USA

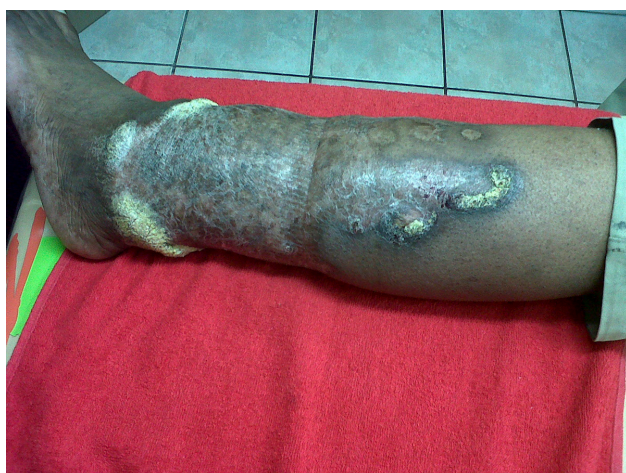**Citation:** Drusinsky S, Lal K, Kazlouskaya V, Hamid F. A verrucous plaque on the lower leg. *Dermatol Pract Conc*. 2013;3(4):4. <http://dx.doi.org/10.5826/dpc.0304a04>.

**Copyright:** ©2013 Kazlouskaya et al. This is an open-access article distributed under the terms of the Creative Commons Attribution License, which permits unrestricted use, distribution, and reproduction in any medium, provided the original author and source are credited.

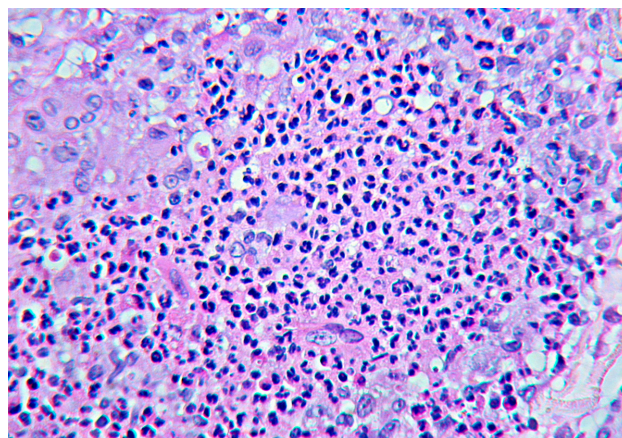
**Corresponding author:** Viktoriya Kazlouskaya, M.D., Ph.D., Ackerman Academy, 145 East 32nd Street, New York, NY 10016. Tel. 800.553.6621. Email: [viktoriakozlovskaya@yahoo.com](mailto:viktoriakozlovskaya@yahoo.com)

## Quiz case

A 52-year-old male patient from South Africa presented with a lesion on his lower left leg extending from the ankle to just below the knee that has been present for twenty years. The lesion first developed as a verrucous nodule close to the lateral part of the ankle and gradually enlarged, involving the entire lower leg. Clinical examination revealed a verrucous plaque with an elevated border and central areas of atrophy and scar formation. The patient was otherwise healthy, in an

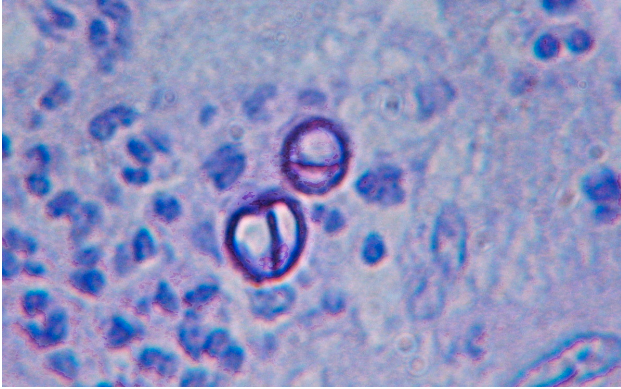


**Figure 1.** Verrucous plaque on the lower leg. [Copyright: ©2013 Kazlouskaya et al.]



**Figure 2.** Suppurative granulomas with neutrophils, histiocytes and plasma cells. [Copyright: ©2013 Kazlouskaya et al.]

excellent physical profile (Figure 1). He had no associated leg pain, abdominal pain, or any history of recurrent fevers. There was no history of systemic disease, and physical examination with CBC was within normal limits. A biopsy was obtained from the verrucous plaque. Histopathologic findings revealed epidermal hyperplasia and papillomatosis. Granulomas were noted in the dermis showing central suppuration and necrosis (Figure 2). A marked plasma cell infiltrate was also evident. Copper colored muriform bodies were revealed in some granulomas (Figure 3).



**Figure 3.** Copper colored muriform bodies. [Copyright: ©2013 Kazlouskaya et al.]

## Answer

Given the histopathological and clinical information, a diagnosis of *chromoblastomycosis* was made.

## Discussion

Chromoblastomycosis is a fungal infection usually found in tropical and subtropical climates [1]. The causative agents for this infection include but are not limited to dematiaceous fungi *Fonsecaea pedrosoi*, *Fonsecaea compacta*, *Rhinochlorella aquaspersa*, *Cladophialophora*, and *Phialophora verrucosa*. This infection was first described in Brazil by Pedroso de Moraes. It usually develops in adolescents working with soil in rural environments. Chromoblastomycosis is seen predominantly in males [1]. Poverty and absence of proper footwear are the main factors involved in the etiology and development of the infection.

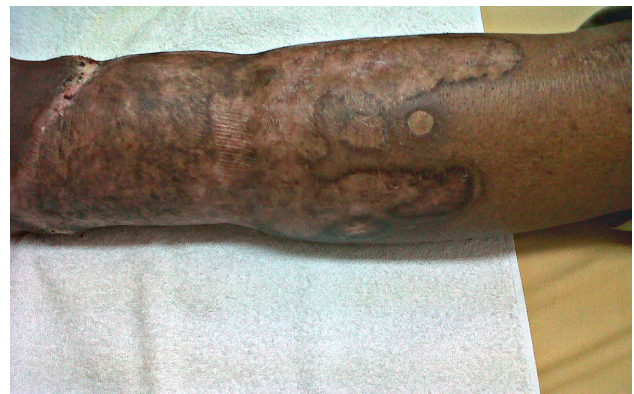Fungal organisms are often implanted in the skin as a result of mild trauma. Microorganisms transform into filamentous forms within tissues. The infection tends to be chronic and may be present several years.

The lesions are usually confined to the lower legs, but cases have been reported of the infection located on the face, scalp, groin and arms. Mucous membranes are not affected. Different clinical presentations of chromoblastomycosis are described: nodular, tumor-like, verrucous hypertrophic plaques, scaly papules, and as cicatricial atrophic lesions [1]. Verrucous plaques are the most common clinical presentation. More than one type of lesion may be present in one patient, given the polymorphic clinical nature of the infection. Pruritus may accompany early lesions [2].

Clinically the diagnosis is not specific and may be misdiagnosed with other infectious conditions such as Mycobacteria infections and sporotrichosis, as well as neoplastic conditions (squamous cell carcinoma, basal cell carcinoma and keratoacanthoma). Typical copper colored muriform bodies can be identified by direct microscopic examination via a KOH preparation. Dermatopathological examination of the lesions

reveals epidermal hyperplasia with suppurative granulomas. Fungi are also typically seen on biopsy. Culture of the scrapings on the Sabouraud agar aids in identifying the causal organism.

Treatment is region specific but often includes systemic antifungal medications such as terbinafine (200-250 mg/day), itraconazole (100-400 mg/day), fluconazole (100-400 mg/day), and/or ketoconazole (200-400 mg/day). Amphotericin B is less effective and is usually used in combination therapy. This patient was placed on 400 mg itraconazole therapy for two months and clinical improvement was seen in several months (Figure 4). The infection is difficult to treat and it may be refractory to antifungal therapy. Relapses are common. Treatment is usually prolonged and is performed until negative cultures are obtained [3]. Surgical excision or cryotherapy may be performed in cases of small lesions. Heat has been described to help in healing of the lesions. Portable pocket heaters showed to be effective in killing pathologic fungi, with temperatures higher than 420° C [3].



**Figure 4.** Atrophic scar formation within healing lesions. [Copyright: ©2013 Kazlouskaya et al.]

Chromoblastomycosis infection rarely has systemic complications and this is the reason why patients refer to their physician in late stages of the infection. Squamous cell carcinoma may rarely arise in chromoblastomycosis lesions [4]. A case of osseous infection due to overlying chromoblastomycosis has also been described [5]. Lymphedema and elephantiasis may develop as a result of lymphatic spread and obstruction [6]. Cases of internal organ involvement are extremely rare in immunocompetent individuals.

## References

1. López Martínez R, Méndez Tovar LJ. Chromoblastomycosis. Clin Dermatol. 2007;25(2):188-94.
2. Queiroz-Telles F, Esterre P, Perez-Blanco M, et al. Chromoblastomycosis: an overview of clinical manifestations, diagnosis and treatment. Med Mycol. 2009;47(1):3-15.
3. Torres-Guerrero E, Isa-Isa R, Isa M, Arenas R. Chromoblastomycosis. Clin Dermatol. 2012;30(4):403-8.
4. Torres E, Beristain JG, Lievanos Z, Arenas R. Chromoblastomycosis associated with a lethal squamous cell carcinoma. An Bras Dermatol. 2010;85(2):267-70.

5. Sharma NL, Sharma VC, Mahajan V, Shanker V, Sarin S. Chromoblastomycosis with underlying osteolytic lesion. *Mycoses*. 2007;50(6):517-9.
6. Sharma N, Marfatia YS. Genital elephantiasis as a complication of chromoblastomycosis: a diagnosis overlooked. *Indian J Sex Transm Dis*. 2009;30(1):43-5.