



## Endourology

## Supine PCNL in patient with staghorn renal stone and severe degree kyphosis: A case report

Rendy Andika, Ponco Birowo, Nur Rasyid, Widi Atmoko\*

Department of Urology, Cipto Mangunkusumo Hospital, Faculty of Medicine Universitas Indonesia, Jakarta, Indonesia

## ARTICLE INFO

## Keywords:

Kyphosis  
PCNL  
Staghorn renal stone  
Spinal deformity

## ABSTRACT

Spinal deformity concomitantly with large renal stone has become a challenges for urologist since it needs different approach in performing percutaneous procedures. This case report highlight our success experience in treating a 53-years old female patients with severe degree of kyphosis and staghorn stone using supine PCNL. She underwent right PCNL and right Double-J stent insertion antegrade after stone were released. The duration of surgery was 2 hours and 45 minutes with no intra and post-operative complication reported. Supine position can be safely chosen if prone cannot be placed in complex situation such as staghorn stone in severe kyphosis patients.

## Introduction

Staghorn calculi is a condition when renal stones occupy a large portion of renal pelvis or renal calyces. The European Association of Urology (EAU) recommend actively treat all newly diagnosed staghorn calculi using surgical treatment since untreated staghorn calculus tend to destroy the kidney and cause life-threatening urosepsis. Percutaneous nephrolithotomy (PCNL) is a minimally invasive method and become first-line treatment for removal of stones larger than 20mm, staghorn, and partial staghorn calculi as recommended by EAU with stone-free rates up to 95%.<sup>1</sup>

Kyphosis is one of spinal deformity in which excessive outward curves of the spine result in abnormal rounding of the upper back. Right handling of urolithiasis in this population is difficult due to anatomic variations and stone size may not be a single factor in deciding the best treatment. Severe degree kyphosis becomes a challenge since it may reduce stone-free rate and higher risk of complications. Furthermore, patients who underwent PCNL need a different approach and positioning considering anaesthesiology and cardiorespiratory issues and percutaneous access modality.<sup>2</sup> This case report aimed to highlight our successful experience in treating severe kyphosis patient with staghorn renal stone using supine PCNL.

## Case presentation

Female, 53-years-old, came to outpatient clinic with progressive right flank pain since four months before admission. The pain was intermittent, dull, and not influenced by position. She urinates spontaneously 1500ml/24 hours. The patient had kyphosis since 8 years ago causing visible hump on the back, spine stiffness, and severe back pain. Physical examination showed pain with VAS 7 and severe degree kyphosis with more than 40° curvature (Fig. 1A and B).

Laboratory examinations showed anemia with hemoglobin 8.8 mg/dL and hematocrit 26.3%, ureum 94 and creatinine 4.8. Other parameters and urinalysis were within normal limit. Abdominal x-ray showed radioopaque lesion sized 90 × 41 mm in right hemiabdomen as high as L2-L4 (Fig. 1C). CT urography showed hyperdense lesion in right pelvicolalyces with size 90 × 30 × 41mm with no hydronephrosis (Fig. 1D and E). Patient was diagnosed with right staghorn renal stone, chronic kidney disease, and severe degree kyphosis. She underwent right supine PCNL and right Double-J stent insertion in general anesthesia.

The patient was placed in modified supine position (lateral 30°) and a 22F rigid cystoscope (OLYMPUS™) was used to pass ureteral catheter under fluoroscopic guidance into the renal pelvis. Right ureteral catheter was inserted through right ureter-vesical junction followed by wire insertion. Percutaneous puncture in right flank (2 fingers posterior to posterior line of axillaris) to gain access to the kidney was done. Calyx

\* Corresponding author. Department of Urology Cipto Mangunkusumo Hospital, Faculty of Medicine Universitas Indonesia, Jalan Diponegoro No. 71, Kenari, Senen, Jakarta Pusat, 10430, Indonesia.

E-mail addresses: [rendyandika.urology@gmail.com](mailto:rendyandika.urology@gmail.com) (R. Andika), [ponco.birowo@gmail.com](mailto:ponco.birowo@gmail.com) (P. Birowo), [nur.rasyid@gmail.com](mailto:nur.rasyid@gmail.com) (N. Rasyid), [dr.widiatmoko@yahoo.com](mailto:dr.widiatmoko@yahoo.com) (W. Atmoko).

<https://doi.org/10.1016/j.eucr.2020.101509>

Received 1 November 2020; Received in revised form 24 November 2020; Accepted 27 November 2020

Available online 29 November 2020

2214-4420/© 2020 The Authors.

Published by Elsevier Inc.

This is an open access article under the CC BY-NC-ND license

(<http://creativecommons.org/licenses/by-nc-nd/4.0/>).

puncture was done using 17G needle through inferior posterior calyx right kidney. Puncture then dilated using metal dilator no. 6, inner sheath no. 28, and Amplatz no. 28, a rigid nephroscope was inserted.

Staghorn renal stone was found then destroyed using shockpulse (OLYMPUS™) and pneumatic lithotripter (VIBROLITH™) (Fig. 2A–D). Stone fragments were evacuated using stone forceps (STORZ™). Evaluation showed no residual stone, no infundibulum laceration and active bleeding (Fig. 3A–D). 4.7F Double J-stent (UROTECH™) was placed from antegrade. Duration of surgery was 2 hours and 45 minutes. There were 50 ml bleeding, no intra or post-operative complication reported.

Postoperative imaging were performed 1 day after procedure and no residual stone was found (Fig. 3E). Double-J stent was removed after one month. The patient had no complain regarding surgical wound and urinary tract system.

## Discussion

The indication of PCNL procedure in our patient was the right staghorn renal stone. According to the EAU, PCNL is the first treatment choice for stones larger than 20 mm, staghorn, and partial staghorn calculi.<sup>1</sup> Computed tomography scan was done preoperatively as it is the first choice imaging modality for detecting renal calculi and the 3-dimensional reconstructions for collecting system evaluation. Consideration of the spinal deformity has been taken carefully in performing PCNL in this patient.

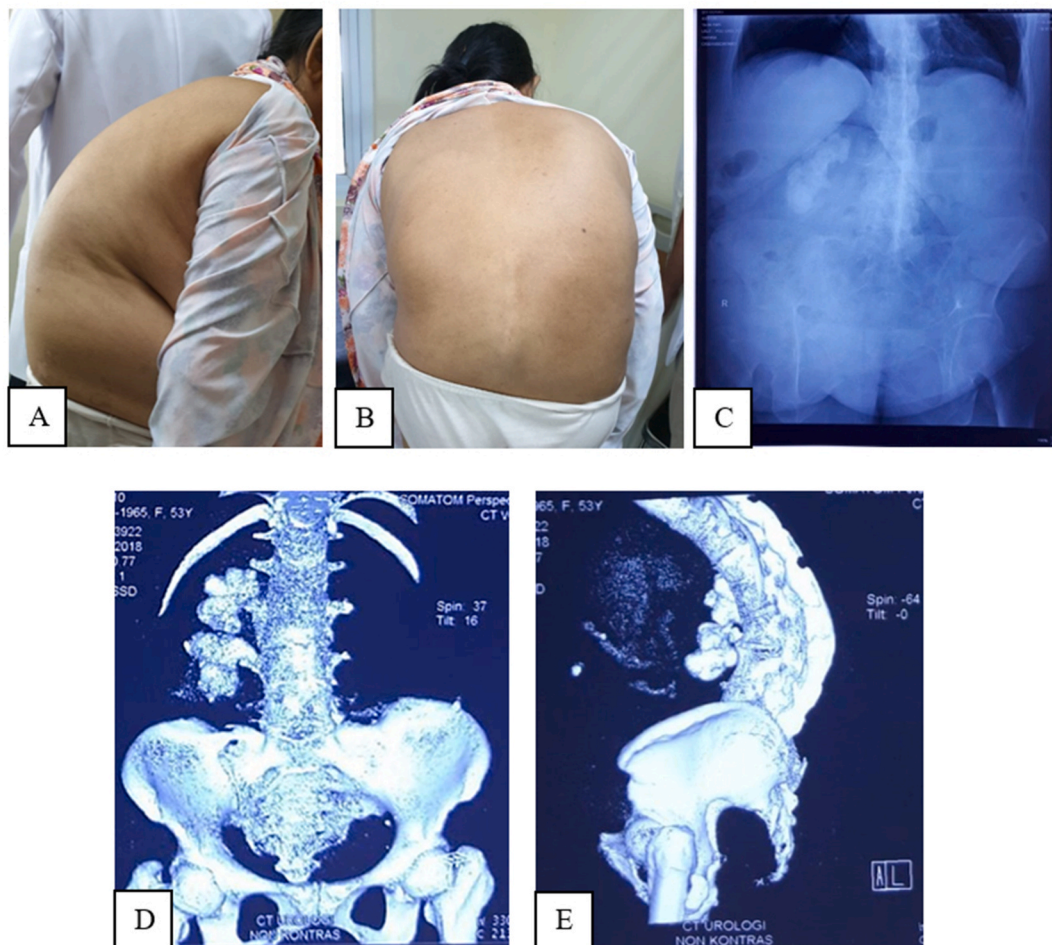
Severity of the kyphosis measured by the Cobb angle determines the success of stone surgery. As reported in a study by Chaudry et al. there

was a significant association between higher Cobb angle and lower stone-free rates in spina bifida patients.<sup>3</sup> Our patient had severe kyphosis with more than 40° and this condition may contribute to the challenging working space in PCNL procedure to achieve higher stone-free rates. Therefore, patient positioning was very decisive and our study addressed this problem as our main concern.

Prone position is normally considered as the standard approach in PCNL. However, concerning the anesthesiological safety affecting cardiovascular and ventilation status in patient with severe kyphosis as seen in this case, prone position may not be chosen. Prone position will increase intra-abdominal pressure that can secondarily restrict diaphragm movement lead to reduce respiratory function.<sup>2</sup> The modified supine position has better advantage in cardiovascular and respiratory system, easier for anesthesiologist to manage the patient. This is in contrast with previous study by Bahar et al. which performed prone PCNL in one severe skeletal deformity patient.<sup>4</sup>

Moreover, this patient was placed in supine position due to her severe pain. For that reason, change in position or significant movement should be avoided. By supine positioning, only minimal reposition needed after retrograde ureter catheter was inserted. Despite the significant difference in favour of prone position, it was reported that there was no difference of complications in both position.<sup>5</sup>

Percutaneous access guidance is also an important part in PCNL. We used fluoroscopy as the guiding for percutaneous access since this patient has higher risk to have visceral injury during the puncture of renal cavities because of anatomical abnormality. Previous studies suggested regional anesthesia as an alternative to general anesthesia in spinal



**Fig. 1.** Clinical presentation of severe kyphosis (curvature >40°) (2A, 2B). Preoperative abdominal xray (2C). CT urography and CT Scan with 3D modelling (2D, 2E).

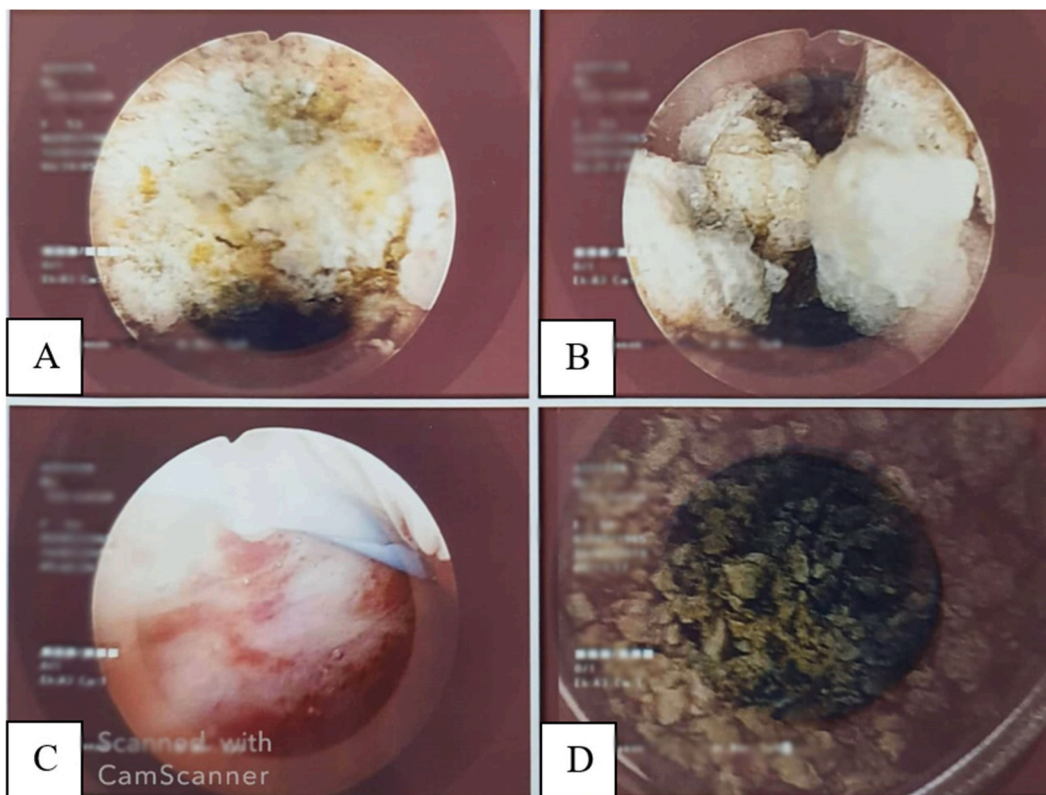


Fig. 2. Renal stone appearance from nephroscope (2A-2D).

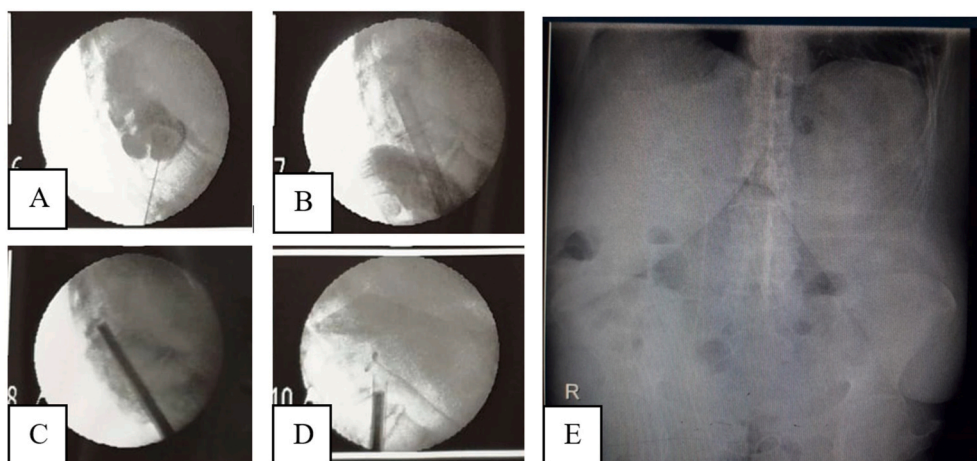


Fig. 3. Retrograde pyelogram after PCNL showed no residual stone (3A-3D). Abdominal x-ray after PCNL showed no residual stone (3E).

deformity patients.<sup>2</sup> However, we used general anesthesia with endotracheal tube due to the supine position. It was performed successfully without any complication.

**Conclusion**

Treatment of staghorn stone in patient with severe kyphosis is a complex situation which may need different approach in planning and performing PCNL. Supine position can be safely chosen. Special attention to percutaneous access and cardiorespiratory function is necessary to avoid complication.

**Funding source**

This research did not receive any specific grant from funding agencies in the public, commercial, or not-for-profit sectors.

**Declaration of competing interest**

None.

**Acknowledgements**

Department of urology, Cipto Mangunkusumo Hospital, Jakarta, Indonesia.

## References

1. Ghani KR, Andonian S, Bultitude M, et al. Percutaneous nephrolithotomy: update, trends, and future directions. *Eur Urol.* 2016;70:382–396.
2. Gourmas-Kartalas I, Montanari E. Percutaneous nephrolithotomy in patients with spinal deformities. *J Endourol.* 2010;24(7):1081–1089.
3. Chaudry R, Theisen KM, Stephany HA, Schneck FX, Cannon GM, Ost MC. Percutaneous stone surgery in spina bifida patients-Are stone-free rates worth the risk? *J Endourol.* 2017;31(S1):S81–S86.
4. Bahar SHM, Amirhasani S, Mohseni M, Daneshdoost R. Safety and efficacy of percutaneous nephrolithotomy in patients with severe skeletal deformities. *Endourol Stone Dis.* 2017;14(3):3054–3058.
5. Zhang X, Xia L, Xu T, Wang X, Zhong S, Shen Z. Is the supine position superior to the prone position for percutaneous nephrolithotomy (PCNL)? *Urolithiasis.* 2014;42(1):87–93.