

Classification of Mouth Corners in Asian Women

Tae Kwang Jeong*
Young Min Kim†
Kyung Hee Min†

Background: There is increasing interest in mouth corner lift (MCL), as well as lip augmentation. Procedures for lip corner lifting to create smiling lips include botulinum toxin, injectable filler, and surgery. However, there is no proper system to classify mouth corners, thereby causing difficulties in patient counseling, treatment planning, and communicating with medical staff. We developed a new classification system to analyze the shape of mouth corners in Asian women.

Methods: Lip shapes were classified as types I (arched upper lip) and II (flat upper lip), each of which was further classified as subtypes a (upturned mouth corner) and b (flat or downturned mouth corner). Atypical cases were classified as type III. The anterior–posterior view of facial photographs were taken of female patients aged 20–40 years who visited HB Plastic Surgery Clinic between January 2017 and December 2018. Patients who visited for surgery other than lip plastic surgery (group A) and those who visited for MCL (group B) were compared. Changes in mouth corner type across age were examined.

Results: The most common type was IIb in group A and Ib in group B. IIa and IIb were more common in group A, whereas Ib was more common in group B, at a statistically significant level. With increasing age, the proportions of IIb and III tended to increase, and Ia and IIa tended to decrease.

Conclusion: This relatively simple classification system for mouth corners might be helpful in patient counseling and communication with medical staff during plastic surgery. (*Plast Reconstr Surg Glob Open* 2020;8:e2608; doi: 10.1097/GOX.0000000000002608; Published online 6 February 2020.)

INTRODUCTION

With increasing income and advancements in the areas of media and marketing, the demand for cosmetic procedure and surgery has been steadily increasing.^{1,2}

During the past few years, the number of individuals wanting to aesthetically improve their lips has continuously increased. In the past, the demand was concentrated on lip

augmentation and subnasal lift; however, recently, increasingly more individuals are seeking a mouth corner lift (MCL).

Lips are an important aesthetic unit in the lower face and the window of such diverse emotions as joy, sadness, and anger.^{3,4} A face looks appealing or off-putting depending on the shape of the mouth corners. Typically, lips with slightly upturned corners look friendly and warm to others, while downturned corners look depressed and angry.⁵

Various techniques are used to create smiling lips, from smile exercise to botulinum toxin and injectable filler, and to surgery.^{6,7}

However, difficulties arise in patient counseling, communication between medical staff, and treatment planning due to lack of a proper classification system for mouth corners.

Accordingly, we conducted this study to classify mouth corners into a few types, compare patients who underwent MCL and those who did not, and examine changes across age to reference the classification system in performing cosmetic procedures and surgeries on lips in practice.

MATERIALS AND METHODS

Photos of the frontal face of female patients who visited HB plastic surgery clinic between January 2017 and December 2018 were analyzed. We determined mouth

Disclosure: The authors have no financial interest to declare in relation to the content of this article.

From the *HB Plastic Surgery Clinic, Seoul, Korea; and †Department of Plastic and Reconstructive Surgery, Eulji University School of Medicine, Eulji General Hospital, Seoul, Korea.

Received for publication September 2, 2019; accepted November 8, 2019.

Ethical Approval: All procedures performed in studies involving human participants were in accordance with the ethical standards of the institutional and/or national research committee and with the 1964 Helsinki declaration and its later amendments or comparable ethical standards.

Informed consent: The patients provided written informed consent for the publication and the use of their images.

Copyright © 2020 The Authors. Published by Wolters Kluwer Health, Inc. on behalf of The American Society of Plastic Surgeons. This is an open-access article distributed under the terms of the [Creative Commons Attribution-Non Commercial-No Derivatives License 4.0 \(CCBY-NC-ND\)](https://creativecommons.org/licenses/by-nc-nd/4.0/), where it is permissible to download and share the work provided it is properly cited. The work cannot be changed in any way or used commercially without permission from the journal.

DOI: 10.1097/GOX.0000000000002608

corner type in each patient, using a classification system devised by us. To compare the characteristics of control and MCL patient groups, the patients were divided into two groups. The first group (group A) represented the shape of mouth corners of control subjects and consisted of patients aged between 20 and 40 years who came to the clinic for surgery (blepharoplasty, rhinoplasty, otoplasty, etc.) other than lip plastic surgery, including MCL. The second group (group B) consisted of patients in the same age range who came to the clinic to undergo MCL during the same study period.

With increasing age, the perioral region changes, the upper lip becomes thinner and flatter, and the oral commissures descend.⁸ Accordingly, patients aged over 40 were excluded from study on the assumption that the shape of the lips changes with age and looks similar among older individuals. In addition, patients with a history that may have changed the shape of the lips (such as a procedure or surgery on the lips, Bell's palsy, trauma-induced lip distortion, and bone surgery through an intraoral incision) were excluded from the study.

To investigate age-related change in the mouth corners, the distribution of mouth corner types by age was examined.

Patients were instructed to maintain a relaxed closed bite and keep the face straight, and photographed at a fixed distance (1.5 m) from the camera in the same room. The relative position between the mouth corner and lip was measured on the anterior–posterior view photograph, and the mouth corners were categorized as follows.

The overall shape of the upper lip was classified into types I and II. A lip shape was determined to be type I if the stomion was superior to an imaginary line connecting the oral commissure on either side (ie, arched upper lip), and type II if it was on or inferior to the line (ie, flat upper lip).

Subtypes a and b were classified depending on the direction of a mouth corner. Specifically, a mouth corner was determined as subtype “a” if the lower margin of the upper lip continuing to the oral commissure was upturned around a one-quarter point in the upper lip laterally (ie, upturned mouth corner), and subtype “b” if it was flat or downturned around the point (ie, flat or downturned).

Mouth corners were classified as types Ia, Ib, IIa, and IIb on the basis of the aforementioned criteria. Those not fitting into any of the types were defined as atypical and labeled as type III (Figs. 1, 2).

Statistical Analysis

R language version 3.3.3 (R Foundation for Statistical Computing, Vienna, Austria) was used for all statistical analyses.

A two-sample proportion test was used to compare the distributions of mouth corner types. Weighted linear regression was performed to analyze the change in mouth corner types with increasing age.

RESULTS

A total of 820 mouth corners of 410 patients in group A and a total of 496 mouth corners of 248 patients in group

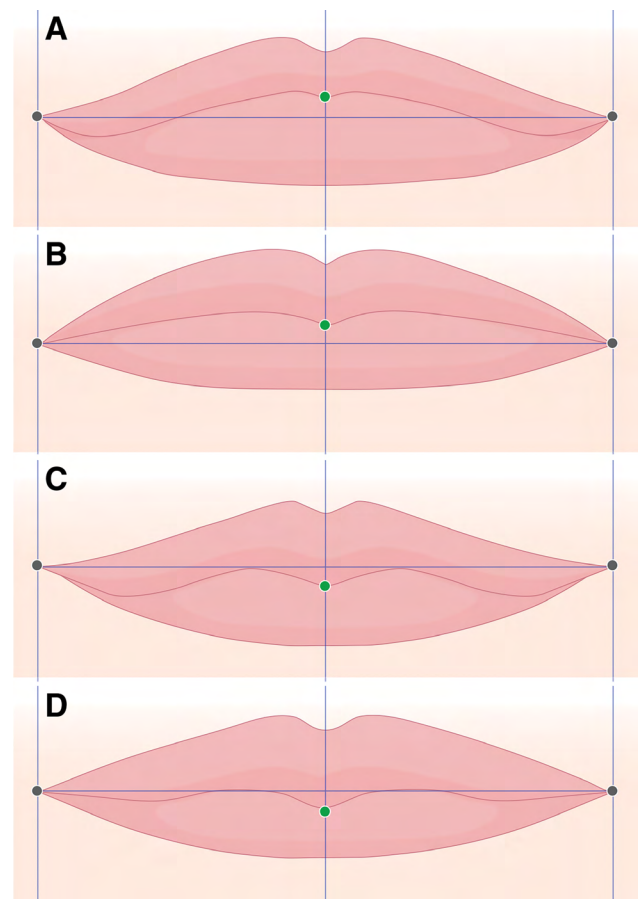


Fig. 1. Classification of mouth corners. A mouth corner was classified as type I if the stomion was located above an imaginary line connecting the oral commissure in either side, and type II if it was located on or below the line; subtype “a” if the lower margin of the upper lip continuing to the oral commissure was upturned around a one-quarter point laterally in the upper lip lateral, and subtype “b” if it was flat or downturned around the point. A, type Ia; B, type Ib; C, type IIa; D, type IIb. Green dot: stomion; black dot: cheilion.

B were classified into one of the five types according to the classification system developed by us.

In group A, the most common type of mouth corner was type IIb (51.1%). The proportions of types Ia and IIa, the types desired by patients wanting MCL for aesthetic reasons, were 12.4% and 18.0%, respectively.

In group B, the most common type was type Ib (46.2%), followed by type IIb (37.3%). Between-group analysis showed that the proportions of types IIa and IIb were statistically significantly higher in group A than in group B, while type Ib was statistically significantly higher in group B than in group A (Table 1).

Asymmetry between the left and right mouth corners was observed in 86 (10.5%) patients in group A and in 25 (10.1%) patients in group B. The most common mouth corner types among patients with the asymmetry were type IIa/IIb (n=56, 65.1%) in group A and type Ia/Ib (n=12, 48%) in group B.

The analysis of the change in mouth corners across age showed that in group A* (female patients who came to the clinic for surgery other than lip plastic surgery), types

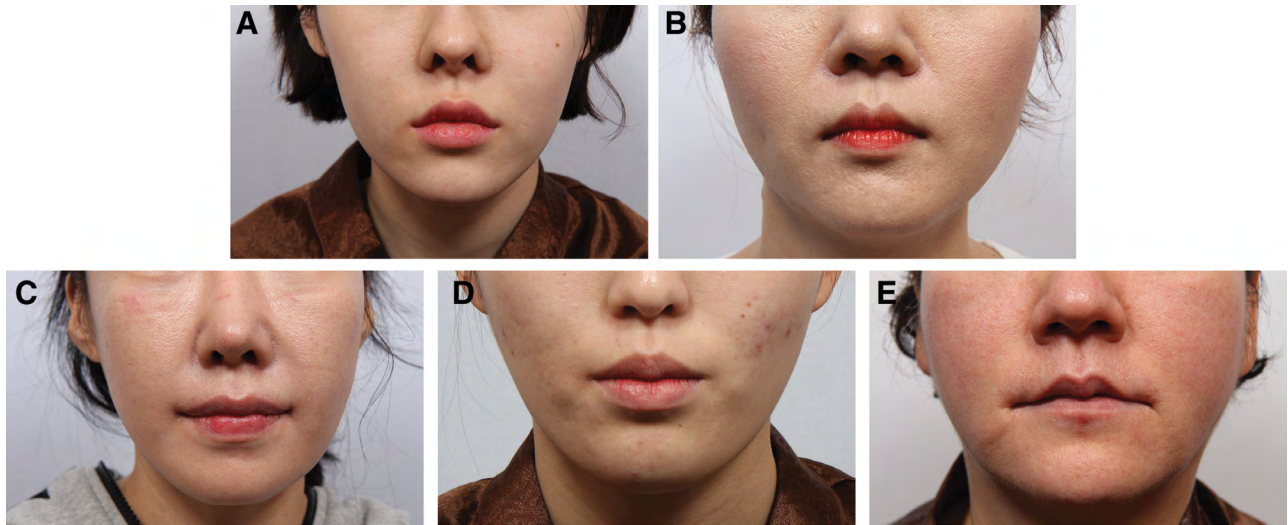

Fig. 2. Clinical photographs for each type of mouth corners. A, type Ia; B, type Ib; C, type IIa; D, type IIb; E, type III.

Table 1. Between-group Analysis of the Shape of Mouth Corners

Type	Group A (%)	Group B (%)	P
Type Ia	102 (12.4)	47 (9.5)	0.100
Type Ib	144 (17.6)	229 (46.2)	<0.001
Type IIa	148 (18.0)	35 (7.0)	<0.001
Type IIb	419 (51.1)	185 (37.3)	<0.001
Type III	7 (0.9)	0 (0)	0.039
Total	820	496	

Group A: Female patients aged 20–40 who came to the clinic for surgery other than lip plastic surgery.

Group B: Female patients aged 20–40 who came to the clinic for mouth corner lift.

Ia and IIa tended to decrease and types Ib, IIb, and III tended to increase with age, although the changes were not statistically significant (Table 2).

In group B* (patients who came to the clinic for MCL), type IIb significantly increased as age increased. And types Ia, Ib, and IIa tended to decrease and type III tended to increase, although the changes were not statistically significant (Table 3).

Table 2. Analysis of Mouth Corners According to Age in Group A*

Age	20–29 (%)	30–39 (%)	40–49 (%)	>50 (%)
Type Ia	82 (15.8)	20 (6.6)	8 (5.7)	3 (3.7)
Type Ib	106 (20.5)	38 (12.6)	28 (20.0)	21 (25.6)
Type IIa	85 (16.4)	63 (20.9)	23 (16.5)	2 (2.4)
Type IIb	239 (46.1)	180 (59.6)	79 (56.4)	53 (64.6)
Type III	6 (1.2)	1 (0.3)	2 (1.4)	3 (3.7)
Total	518	302	140	82

Type	Coef	95% CI	P
Type Ia	-4.755	-7.909~ -1.601	0.098
Type Ib	0.386	-5.482~ 6.254	0.909
Type IIa	-2.385	-8.201~ 3.431	0.506
Type IIb	6.28	1.107~ 11.454	0.14
Type III	0.474	-0.553~ 1.502	0.461

*Group A, female patients who came to the clinical for surgery other than lip plastic surgery.

Coef, coefficient of weighted linear regression; CI, confidence interval.

Table 3. Analysis of Mouth Corners According to Age in Group B*

Age	20–29 (%)	30–39 (%)	40–49 (%)	>50 (%)
Type Ia	24 (10.2)	23 (8.8)	4 (2.4)	4 (2.8)
Type Ib	114 (48.3)	115 (44.2)	74 (43.5)	49 (34.5)
Type IIa	17 (7.2)	18 (7.0)	14 (8.2)	2 (1.4)
Type IIb	81 (34.3)	104 (40.0)	77 (45.3)	82 (57.8)
Type III	0 (0)	0 (0)	1 (0.6)	5 (3.5)
Total	236	260	170	142

Type	Coef	95% CI	P
Type Ia	-2.932	-4.714~ -1.151	0.084
Type Ib	-4.04	-6.156~ -1.924	0.065
Type IIa	-1.394	-3.707~ 0.919	0.359
Type IIb	7.341	5.091~ 9.592	0.024
Type III	1.025	0.095~ 1.955	0.163

*Group B, female patients who came to the clinical for mouth corner lift. Coef, coefficient of weighted linear regression; CI, confidence interval.

DISCUSSION

It is difficult to define beautiful lips in a few simple words, but there is a definition of beautiful lips that is universally agreed upon. They have a proper proportion between the heights of the upper and lower lips, an appropriate volume, and a distinct upper lip white roll. For lips to be of ideal beauty, the ratio between the heights of the upper and lower lips should be 1:1.618, the volume of the lower lip being fuller, and on the sagittal view the upper lip being 1–2 mm more protruding than the lower lip.^{9–11} The oral commissure should be located inside of the line drawn vertically from the medial limbus of the iris, and not be drooping or descending.¹² The lips are an anatomical structure located in the center of the lower face and have multiple functions like food intake, speaking, dental hygiene, tactile organ, and facial expression.¹³ The function of the lips in facial expression is not only to display one’s emotion but also contribute in portraying one’s image to others.⁴

Approaches for mouth corner lifting can be categorized into surgical and nonsurgical. The representative

nonsurgical approaches include botulinum toxin type A (BoNTA) injection and injectable filler use. When BoNTA is injected to the depressor anguli oris muscle, a main depressor of the mouth corner, it causes the paralysis of the muscle and the mouth corner would be elevated.¹⁴ Injectable filler may be injected along the marionette line underneath the mouth corner to lift¹⁵ or in the lateral area of the upper lip to make the mouth corner look curved up by creating an inferiorly convex curve around a one-quarter point laterally in the upper lip. Many plastic surgeons obtain favorable outcomes by using a combination of fillers and BoNTA.^{7,16,17} Surgical approach (namely, MCL) is performed if nonsurgical approach cannot address the problem, to avoid the limitations of BoNTA and fillers (temporary effect, procedure-related complications, etc.) and to improve descended mouth corners or marionette lines remaining after a facelift.⁶

Like other lip plastic surgeries, MCL has also been avoided in the field of aesthetics because of the fear of the possibility of leaving visible scars in the perioral area and the lack of confidence in stable long-term results.^{8,18} Recently, however, the number of physicians performing MCL is gradually increasing, and proficiency in MCL is advancing.^{6,8,19–22}

So far, most studies on lip classification were conducted to determine diagnostic and treatment criteria for cleft lip and palate.^{23–26}

Research to assess and classify lips from an aesthetic point of view has begun relatively recently. Penna et al.²⁷ classified aging lips according to the shape and surface changes of the lips. Jacono AA²⁸ divided a lip into 15 anatomical zones and suggested that lip shapes can be made more ideal by injecting a filler in a certain zone. Carruthers et al.²⁹ proposed the “lip fullness grading scale” on the basis of lip volume, and Cohen et al.³⁰ graded lips using the criteria of static versus dynamic wrinkles and the shape of the oral commissures.

Research has also been conducted on the classification of animated lips. Liang et al.³¹ analyzed dynamic smile and upper lip curvature during a smile and classified each of them into three types. Ackerman et al.⁵ examined posed smile in the context of orthodontic treatment. Additionally, a variety of studies were conducted on lips, but many of them mentioned mouth corners in a vague manner, such as upturned and descended.^{3,6}

Parsa et al. categorized lips into two types according to the frowning mouth corner and the severity of marionette folds and reported the outcomes of excisional treatment in each of the types.¹⁹ However, it is believed that the topology proposed by the authors of that study cannot be used as universal criteria for mouth corner classification, because it was mainly applied to aging patients.

According to our study results, the most common mouth corner type among young Asian women was type IIb, followed by types IIa, Ib, Ia, and III. Most of the young Asian women who wanted lip plastic surgery had type Ib or IIb and wanted to have type Ia or IIa.

Aging change in the lips involves thinning, flattening, and descended mouth corner.⁸ It was confirmed in our study that with increasing age, the proportion of smiling

lips, as seen in types Ia and IIa, decreases, whereas the proportions of flat or downturned type and atypical type, such as types IIb and III, increase.

Treatment plans specific to each type in our classification system are as follows. Regarding type Ia, a slight lifting of the mouth corner can create overall smiling lips because the lateral portion of the upper lip always has a convex curvature. In contrast, to achieve the same effect, type Ib requires considerable lifting of the mouth corner or volume enhancement in combination with MCL to achieve convexity in the lateral portion of the upper lip.

In type IIa, a conservative approach is necessary to avoid the joker’s smile post surgery and create balanced lips because the mouth corner is already positioned relatively high in comparison to other types. In type IIb, the height of the mouth corner should be conservatively lifted and, simultaneously, the volumetric aspect in the lateral portion of the upper lip should be taken into consideration, as in type Ib.

Type III is a category for atypical cases not classified into either type I or type II. Cases in this category include those in which the oral commissures are not visible because of overriding soft tissue, which is common in the lips of the elderly, and those in which the lips are too thin to be classified into any of the types. When treating such lips, a surgical technique to address the overall volume of the lips and overriding soft tissue should accompany in addition to lifting the mouth corner.¹⁹

The ultimate goal of MCL is not to lift a mouth corner per se but to create a beautiful and harmonious mouth corner by taking into account its position in absolute and relative sense, harmony with the overall lips, and, further, the aesthetics of the lower face.

Our classification system for mouth corners may be useful in performing MCL, as it is relatively simple and can classify most mouth corners. A limitation of the classification system is that it focuses on classifying mouth corners, rather than the shape of the entire lips. Therefore, in the future, research should be conducted to develop a classification system which includes lips and mouth corners comprehensively.

Also, our study was conducted on the mouth corners of Asian women only. Therefore, it would be meaningful to analyze the shape of the mouth corners according to race using our classification.

CONCLUSION

We have proposed a simple and clinically useful classification system for mouth corners, which is expected to help facilitate patient counseling and communication between medical staff in lip plastic surgery.

Kyung Hee Min, MD, PhD

Department of Plastic and Reconstructive Surgery
Eulji University School of Medicine
Eulji General Hospital
280-1 Hagae-dong, Nowon-gu
Seoul 139-872, Korea
E-mail: mkh797@hanmail.net

REFERENCES

1. No authors. Cosmetic surgery national data bank statistics. *Aesthet Surg J*. 2018;38:S1–24.
2. Milutinovic J, Zelic K, Nedeljkovic N. Evaluation of facial beauty using anthropometric proportions. *Scientific World Journal*. 2014;20:1–8.
3. Matthews TG. The anatomy of a smile. *J Prosthet Dent*. 1978;39:128–134.
4. Sawyer AR, See M, Nduka C. Quantitative analysis of normal smile with 3D stereophotogrammetry—an aid to facial reanimation. *J Plast Reconstr Aesthet Surg*. 2010;63:65–72.
5. Ackerman JL, Ackerman MB, Brensinger CM, et al. A morphometric analysis of the posed smile. *Clin Orthod Res*. 1998;1:2–11.
6. Perkins SW. The corner of the mouth lift and management of the oral commissure grooves. *Facial Plast Surg Clin North Am*. 2007;15:471–476, vii.
7. Perkins NW, Smith SP Jr, Williams EF 3rd. Perioral rejuvenation: complementary techniques and procedures. *Facial Plast Surg Clin North Am*. 2007;15:423–32, vi.
8. Poindexter BD, Sigal RK, Austin HW, et al. Surgical treatment of the aging mouth. *Semin Plast Surg*. 2003;17:199–207.
9. Swift A, Remington K. Beautiphication™: a global approach to facial beauty. *Clin Plast Surg*. 2011;38:347–77, v.
10. Penna V, Fricke A, Iblher N, et al. The attractive lip: a photomorphometric analysis. *J Plast Reconstr Aesthet Surg*. 2015;68:920–929.
11. Sarnoff DS, Gotkin RH. Six steps to the “perfect” lip. *J Drugs Dermatol*. 2012;11:1081–1088.
12. Perkins SW, Sandel HD 4th. Anatomic considerations, analysis, and the aging process of the perioral region. *Facial Plast Surg Clin North Am*. 2007;15:403–7, v.
13. Page RE, Stranc MF. Normal lip function in adults. *Ann Plast Surg*. 1982;9:502–505.
14. Qian W, Zhang YK, Lv W, et al. Application of local injection of botulinum toxin A in cosmetic patients with congenital drooping mouth corner. *Aesthetic Plast Surg*. 2016;40:926–930.
15. Ho TT, Bacos JT, Dayan SH. Corner of the mouth-reversing the earliest sign of aging. *Facial Plast Surg*. 2019;35:172–175.
16. de Maio M, Wu WTL, Goodman GJ, et al. Facial assessment and injection guide for botulinum toxin and injectable hyaluronic acid fillers: focus on the lower face. *Plast Reconstr Surg*. 2017;140:393e–404e. doi:
17. Mannino GN, Lipner SR. Current concepts in lip augmentation. *Cutis*. 2016;98:325–329.
18. Haworth RD. Customizing perioral enhancement to obtain ideal lip aesthetics: combining both lip voluming and reshaping procedures by means of an algorithmic approach. *Plast Reconstr Surg*. 2004;113:2182–2193.
19. Parsa FD, Parsa NN, Murariu D. Surgical correction of the frowning mouth. *Plast Reconstr Surg*. 2010;125:667–676.
20. Weston GW, Poindexter BD, Sigal RK, et al. Lifting lips: 28 years of experience using the direct excision approach to rejuvenating the aging mouth. *Aesthet Surg J*. 2009;29:83–86.
21. Le Louarn C, Buis J, Buthiau D. Treatment of depressor anguli oris weakening with the face recurve concept. *Aesthet Surg J*. 2006;26:603–611.
22. Vidal P, Berner JE, Castillo P, et al. Descended mouth corner: an ignored but needed feature of facial rejuvenation. *Arch Plast Surg*. 2013;40:783–786.
23. Kernahan DA. The striped Y—a symbolic classification for cleft lip and palate. *Plast Reconstr Surg*. 1971;47:469–470.
24. Khan M, Ullah H, Naz S, et al. A revised classification of the cleft lip and palate. *Can J Plast Surg*. 2013;21:48–50.
25. Kirschner RE, LaRossa D. Cleft lip and palate. *Otolaryngol Clin North Am*. 2000;33:1191–215, v.
26. Allori AC, Mulliken JB, Meara JG, et al. Classification of cleft lip/palate: then and now. *Cleft Palate Craniofac J*. 2017;54:175–188.
27. Penna V, Stark GB, Voigt M, et al. Classification of the aging lips: a foundation for an integrated approach to perioral rejuvenation. *Aesthetic Plast Surg*. 2015;39:1–7.
28. Jacono AA. A new classification of lip zones to customize injectable lip augmentation. *Arch Facial Plast Surg*. 2008;10:25–29. doi:
29. Carruthers A, Carruthers J, Hardas B, et al. A validated lip fullness grading scale. *Dermatol Surg*. 2008;34:S161–S166.
30. Cohen JL, Thomas J, Paradkar D, et al. An interrater and intrarater reliability study of 3 photographic scales for the classification of perioral aesthetic features. *Dermatol Surg*. 2014;40:663–670.
31. Liang LZ, Hu WJ, Zhang YL, et al. Analysis of dynamic smile and upper lip curvature in young chinese. *Int J Oral Sci*. 2013;5:49–53.