

# A randomised preliminary study to compare the performance of fiberoptic bronchoscope and laryngeal mask airway CTrach (LMA CTrach) for visualisation of laryngeal structures at the end of thyroidectomy

## Address for correspondence:

Dr. Geetanjali T Chilkoti,  
A-1404, Jaipuria  
Sunrise Greens, Ahinsa  
Khand, Indrapuram,  
Ghaziabad - 201 014,  
Uttar Pradesh, India.  
E-mail: geetanjali@yahoo.  
co.in

**Submitted:** 16-Mar-2020

**Revised:** 25-May-2020

**Accepted:** 11-Jun-2020

**Published:** 31-Jul-2020

**Geetanjali T Chilkoti, Mayank Agarwal, Medha Mohta, Ashok K Saxena, Chhavi S Sharma, Zainab Ahmed**

Department of Anesthesiology and Critical Care, University College of Medical Sciences and Guru Teg Bahadur Hospital, Shahdara, Delhi, India

## ABSTRACT

**Background and Aims:** Various methods have been used to check vocal cord movements as a routine before awakening the patient at the end of thyroidectomy to rule out recurrent laryngeal nerve (RLN) palsy; out of which, fiberoptic-assisted visualisation via laryngeal mask airway (LMA) being the most desirable. **Methods:** Thirty patients of either sex, aged 18-65 years, American Society of Anaesthesiologists (ASA) grade I/II, scheduled for thyroidectomy under general anaesthesia (GA) were included and were randomised to receive either fiberoptic assisted (FB) or LMA CTrach-assisted (CT) visualisation of laryngeal structures at the end of thyroidectomy. The primary outcome was grade of view of laryngeal structures and secondary outcomes were time taken to achieve optimal view of laryngeal structures, ease of visualisation, hemodynamic parameters, and complications. **Results:** In the fiberoptic group, we obtained comparable optimal laryngeal view i.e., grade 1 and 2 in all (100%) patients in comparison to 14 (93.33%) in LMA CTrach group. The “time taken to achieve the optimal view” was significantly lower in the CTrach group when compared to Fiberoptic group ( $220.67 \pm 95.98$  vis-a-vis  $136.67 \pm 68.98$ ). The ease of visualisation of laryngeal structures was comparable ( $P = 0.713$ ) and the baseline haemodynamic parameters were comparable between the 2 groups and at various designated intervals. In total, 6.66% and 26.66% patients in group FB and CT group, respectively, required manoeuvres. However, difference was statistically significant ( $P < 0.05$ ). **Conclusion:** Both Fiberoptic-assisted and LMA CTrach-assisted visualization of laryngeal structures in thyroidectomy are equally efficacious in terms of the optimal laryngeal view obtained and ease of visualisation. However, the time taken to achieve optimal laryngeal view was lesser with LMA CTrach.

**Key words:** Fiberoptic bronchoscopy, laryngeal mask airway CTrach, thyroidectomy

## Access this article online

Website: [www.ijaweb.org](http://www.ijaweb.org)

DOI: 10.4103/ija.IJA\_138\_20

Quick response code



## INTRODUCTION

Recurrent laryngeal nerve (RLN) injury is one of the most feared complications associated with thyroid and parathyroid surgery with the incidence of permanent RLN injuries varying from 0.5%-5% and transient injuries between 1% -30%.<sup>[1-3]</sup> Therefore, it has been considered desirable to check vocal cord movements as a routine before awakening the patient at the end of thyroidectomy.<sup>[4]</sup> The frequently used techniques are direct laryngoscopy following reversal of neuromuscular blockade under intravenous (IV) sedation,<sup>[5,6]</sup> fiberoptic-assisted visualisation of vocal

cords via Laryngeal Mask Airway (LMA),<sup>[7-9]</sup> and recently, videolaryngoscopes<sup>[10]</sup> and ultrasonography<sup>[11]</sup> have been evaluated.

This is an open access journal, and articles are distributed under the terms of the Creative Commons Attribution-NonCommercial-ShareAlike 4.0 License, which allows others to remix, tweak, and build upon the work non-commercially, as long as appropriate credit is given and the new creations are licensed under the identical terms.

**For reprints contact:** [reprints@medknow.com](mailto:reprints@medknow.com)

**How to cite this article:** Chilkoti GT, Agarwal M, Mohta M, Saxena AK, Sharma CS, Ahmed Z. A randomised preliminary study to compare the performance of fiberoptic bronchoscope and laryngeal mask airway CTrach (LMA CTrach) for visualisation of laryngeal structures at the end of thyroidectomy. *Indian J Anaesth* 2020;64:704-9.

The problems with the direct laryngoscopic visualisation are obscured view and precipitation of laryngospasm due to light plane of anaesthesia.<sup>[5,6]</sup> The fibreoptic-assisted visualisation via LMA has been proposed to be an ideal technique.<sup>[7,8]</sup> The practical limitations of this technique are obscured glottic view due to secretions and interruption in ventilation during the fibreoptic-assessment.

The LMA CTrach is a modification of LMA Fastrach with inbuilt fibreoptic channel and a Liquid Crystal Display (LCD) viewer. It facilitates intubation under direct vision and enables ventilation throughout the procedure.<sup>[12,13]</sup> It has been extensively used as an adjunct to facilitate endotracheal intubation in difficult airway. Recently, it has been used for assessment of glottic structures following thyroidectomy in a case series.<sup>[14]</sup> The result of this series was found to be encouraging in terms of safety, use of corrective manoeuvres and tolerability by the patient.<sup>[14]</sup>

On extensive literature search, no randomised control trial (RCT) has evaluated the role of fibreoptic bronchoscope or LMA CTrach for visualisation of laryngeal structures to rule out RLN injury at the end of thyroidectomy. Therefore, we compared the performance of fibreoptic-assisted visualisation via LMA-proseal (PLMA) and LMA CTrach at the end of thyroidectomy in terms of obtained laryngeal view, time taken to achieve the optimal view, ease of visualisation, associated haemodynamic changes and related complications.

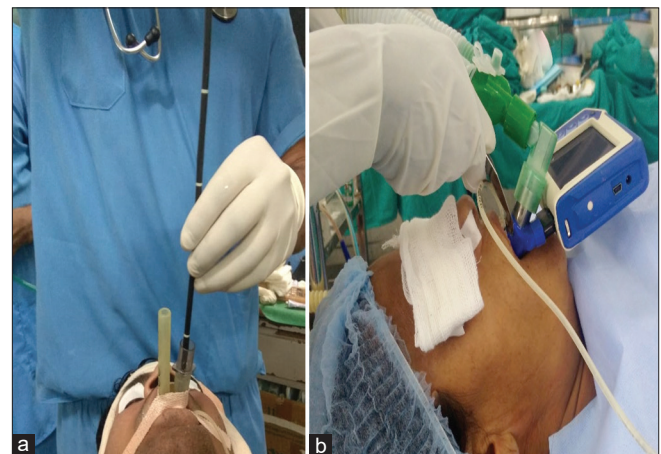## METHODS

The present randomised, interventional study was conducted following approval from Institutional Ethics Committee - Human (IEC-H) from November 2017 to April 2019. The clinical trial was prospectively registered at Clinical Trials Registry - India (hETTP://ctri.nic.in), CTRI/2017/11/010675 on 28<sup>th</sup> November 2017.

The study comprised of 30 patients undergoing thyroidectomy under general anaesthesia (GA). Written informed consent was obtained from all the participants. We included patients of either sex, aged 18-65 years, American Society of Anaesthesiologists (ASA) grade I/II, scheduled for thyroidectomy under GA. We did not recruit patients with upper airway obstruction/abnormalities in supraglottic anatomy, restricted mouth opening and increased risk of aspiration like morbid obesity, second or third trimester pregnancy.

All patients received normal tidal volume preoxygenation with 100% oxygen for three minutes. All routine ASA recommended minimal mandatory monitors i.e., continuous electrocardiogram (ECG), pulse oximeter, end-tidal CO<sub>2</sub>, temperature and intermittent non-invasive blood pressure (NIBP) were instituted. Baseline haemodynamic parameters were recorded. The anaesthetic technique was chosen depending upon the potential risk of difficult airway. Anaesthesia was induced with fentanyl 2 mcg/kg and propofol 2 mg/kg. After confirmation of the face mask ventilation, rocuronium 0.6 mg/kg was given for muscle relaxation. Anaesthesia was maintained with sevoflurane 2% in oxygen throughout the surgery achieving a minimum alveolar concentration (MAC) of 1.0-1.2. Inj. dexamethasone 8 mg IV at the beginning of surgery and Inj. ondansetron 4 mg IV towards the end of surgery was administered for post-operative nausea and vomiting (PONV) prophylaxis to all the patients. With the onset of spontaneous respiratory efforts, the neuromuscular blockade was reversed using glycopyrrolate 0.01 mg/kg and neostigmine 0.05-0.07 mg/kg IV. Following this, the patients were randomised into one of the groups using computer-generated random number tables and the allocation concealment was done by using sequentially-numbered sealed opaque envelopes.

In the patients in group FB, the endotracheal tube (ETT) was replaced with a PLMA which was inserted posterior to the in situ ETT by using Bailey's manoeuvre [Figure 1a].<sup>[9]</sup> The depth of anaesthesia was maintained using oxygen, nitrous oxide and sevoflurane. Following the replacement, fibreoptic bronchoscope was inserted via PLMA. The grade of laryngeal structures visualised was recorded [Table 1], and the vocal cord movement was shown to the



**Figure 1:** (a) Fibreoptic-assisted visualisation of laryngeal structures (b) LMA CTrach-assisted visualisation of laryngeal structures

surgeons. In case of non-optimal view, the placement of PLMA was re-checked and bronchoscope was reinserted. Manoeuvres such as repositioning and reinsertion of PLMA were recorded.

In patients in group CT, ETT was replaced with an appropriate size LMA CTrach™ (The Laryngeal Mask Company, Le Rocher, Victoria, Mahe, Seychelles) [Figure 1b]. Size 3 was used in adolescents from 30-50 kg body weight, size 4 in all adult female patients and a size 5 in all adult males. The LMA CTrach lubricated with jelly on the posterior surface was inserted using one handed rotational technique posterior to the in situ ETT by using Bailey's manoeuvre. If difficulty was faced during insertion along with the use of Bailey's manoeuvre,<sup>[9]</sup> then the ETT was removed first, following which LMA CTrach was inserted. The barrel of the LMA CTrach was then connected to the anaesthesia breathing circuit. Adequate ventilation was ensured in all the patients and the grade of view was recorded [Table 1]. The need for various manoeuvres such as down-up-down (DUD) manoeuvre, medial-lateral-medial (MLM) manoeuvre, Chandy's manoeuvre, suctioning or reinsertion were recorded for each patient [Table 2].

After visualisation, sevoflurane was stopped and PLMA or LMA CTrach was removed.

**Table 1: Grading of laryngeal view<sup>[12]</sup>**

Grade	View of laryngeal structure
I	Full view of the arytenoids and glottic
II	Partial view of the arytenoids and the glottic opening
III	View includes dark areas or blurred view but identifiable structures. View to arytenoids, glottic or epiglottic is blurred
III A	View to arytenoids, glottic or epiglottic is blurred
III B	Only the tip of the epiglottic is visible
IV	No part of larynx can be identified (red out indicates epiglottic or other tissues are blocking the view, white out indicates obstruction by secretions or lubricant, black out indicates insufficient light or insufficient depth of insertion into the larynx)

**Table 2: Recommended adjusting manoeuvres to improve the grade of view with LMA CTrach<sup>[12]</sup>**

Grade of view	Adjusting manoeuvres
I	None
II	Slightly shift the tip of CTrach further Increase light intensity on the viewer
III	Perform suction through the channel for intubation Try to position the tip of the CTrach below the epiglottis under direct vision (DUD)
IV	Red out image - DUD manoeuvre White out image- Reinsert the LMA CTrach Black out image - Increase the light intensity on viewer

Corrective manoeuvres reported with LMA CTrach are DUD manoeuvre and Chandy's manoeuvre (second step). The former involves gripping the handle of the device, swinging it outward about 4-6 cm and reinserting it without deflating the cuff (the "cm" markings on the airway tube may be used as a guide). In the second step of Chandy's manoeuvre, the handle is lifted (but not tilted) away from the posterior pharyngeal wall. Corrective manoeuvres with fiberoptic-assisted visualisation via PLMA are reinsertion of bronchoscope and reinsertion of PLMA.

The grade of laryngeal view was considered optimal if it was either grade I or grade II; whereas, grade III and IV were considered as poor and it required different manoeuvres. The time taken to achieve optimal view was recorded which was measured from the time of ETT removal until the optimal view was achieved. The "Ease of visualisation" was graded as Good: vocal cords visualised without any manoeuvres; Satisfactory: vocal cords visualised with manoeuvres; Worst: vocal cords not visualised even with manoeuvres. The baseline haemodynamic parameters i.e., heart rate (HR), systolic blood pressure (SBP) and diastolic blood pressure (DBP) were recorded immediately before the removal of ETT, and then at an interval of two minutes thereafter until the optimal view was achieved. In addition, any coughing, vomiting, desaturation spells or any other airway complication was also noted.

The primary outcome was the grade of laryngeal view. The secondary outcomes were time taken (in seconds) to achieve optimal view, ease of visualisation, haemodynamic parameters, vocal cord mobility, proportion of patients with complications.

The sample size could not be calculated because it was a preliminary study, rather it was determined on the basis of patients undergoing thyroidectomy in our institute on monthly basis i.e., approximately 2-4 cases per month. Since the study was limited to 18 months, we decided to take a sample size of a minimum of 30 patients with at least 15 patients in each group.

Data analysis was done by using Statistical Package for Social Sciences (SPSS) 20.0 statistical software (IBM, Corp., Armonk, NY, USA). The parametric data is presented as mean (SD) and proportion. The non-parametric data such as grade of laryngeal view, ease of visualisation and complications in both groups were analysed using Chi-square test. The time taken to achieve the optimal laryngeal view was analysed

using unpaired t-test. A *P* value <0.05 was considered as statistically significant.

**RESULTS**

A total of 34 patients were enrolled and 4 were excluded. Out of the 4 patients who were excluded, 3 had restricted mouth opening and one was morbidly obese with uncontrolled diabetes and thus had increased risk of aspiration. Finally, a total of 30 patients were included [Figure 2].

Both the groups were comparable with respect to age, ASA physical status and mean duration of surgery, whereas there was a marked discrepancy in the gender distribution [Table 3].

The optimal laryngeal view in group FB was obtained in all patients (100%) in comparison to 14 (93.33%) patients in group CT. The only patient in group CT who had grade IIIA view did not have anticipated difficult airway and the time taken to achieve optimal laryngeal view and the ease of visualisation of laryngeal structures

were within normal expected range, i.e., 142 seconds and good, respectively [Table 4]. Both the groups were comparable with respect to grade of view of laryngeal structures. The mean “time taken to achieve the optimal view” was significantly (*P* = 0.010) lower in the group CT when compared to group FB (220.67 ± 95.98 vis-a vis 136.67 ± 68.98) [Table 4]. Both the groups were comparable in terms of ease of visualisation of laryngeal structures (*P* = 0.713). Preoperative vocal cord assessment showed bilateral mobile vocal cords in all the patients in both the groups. Postoperative vocal cord mobility was checked and recorded and it matched with the previous baseline record in all.

The baseline haemodynamic parameters i.e., mean HR, SBP and DBP on intergroup analysis was comparable between the two groups. On intergroup analysis at various designated intervals during the procedure, there was no statistically significant difference at any time point.

In group FB, only one patient required repositioning of PLMA, remaining patients did not require any manoeuvre to visualise laryngeal structures. In group CT, three patients required DUD manoeuvre and one patient required Chandy’s manoeuvre while remaining did not require any manoeuvre to obtain optimal laryngeal view. So, in total 6.66% and 26.66% patients in group FB and CT group, respectively required manoeuvres and this difference was not found statistically significant (*P* < 0.05).

With 4 patients in group CT, there was difficulty during LMA CTrach insertion which could be attributed to either application of Bailey’s manoeuvre or the dressing since the vocal cord movements were checked after the dressing. Out of all patients, only one patient in group FB had coughing which was manageable and only one patient in group CT had laryngospasm which occurred after visualisation and removal of LMA CTrach. Laryngospasm was released with the use of CPAP only and the patient remained stable in the postoperative period. None of the patients had vomiting, desaturation spells or any airway-related complications.

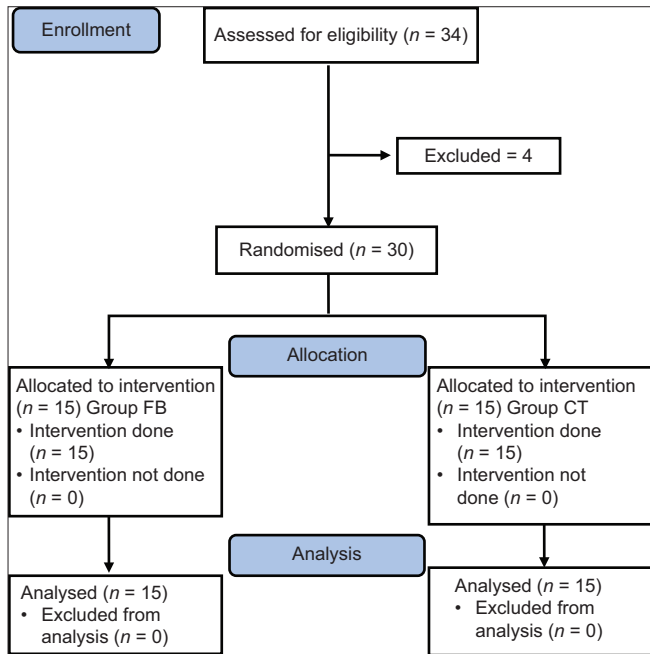


Figure 2: Consort Flow Diagram

Table 3: Patients’ characteristics			
Parameters	Group FB (n=15)	Group CT (n=15)	<i>P</i>
Age (in years) (mean±SD)	33.27±12.11	31.20±11.71	0.8
Duration of Surgery (in min) (mean±SD)	179±0.43	187.67±37.89	0.5
Gender (M:F)	1:14	0:15	0.8
ASA grade (I:II)	13:2	14:1	0.6

**DISCUSSION**

In the present study, no difference was observed in the grade of view of laryngeal structures and all other secondary outcomes were comparable between the two groups except for the “time taken to visualise the laryngeal structures” which was significantly lower in the CT group utilising LMA CTrach.

Table 4: Grade of view of laryngeal structures, Time taken to achieve optimal view and Ease of visualisation

Parameters	Grade	Group FB n=15	Group CT n=15	P
Grade of view	Grade I	7 (46.7)	10 (66.66)	0.462
	Grade II	8 (53.3)	4 (26.66)	
	Grade IIIA	-	1 (6.66)	
	IIB	-	-	
	Grade IV	-	-	
Time taken to obtain optimal view (in sec)	-	220.67±95.98	136.67±68.98	0.010
Ease of Visualisation	Good	9 (60%)	8 (53.3%)	0.713
	Satisfactory	6 (40%)	7 (46.66%)	
	Worst	-	-	

The most standard technique employed for assessment of vocal cord after thyroidectomy is fibreoptic assessment via LMA.<sup>[7,8]</sup> The practical limitations of this technique are that the glottic view may be obscured with secretions and ventilation is interrupted during the bronchoscopic assessment via LMA. Direct laryngoscopy is commonly practiced but is associated with problems like obscured view and precipitation of laryngospasm, both due to light plane of anaesthesia. The LMA CTrach has been commonly used as a difficult airway adjunct,<sup>[12,13]</sup> and recently a case series has employed the use of LMA CTrach for this indication.<sup>[14]</sup> observed lesser use of corrective manoeuvres and better tolerability by the patients. It has the advantage that it enables ventilation throughout the process of visualisation and provides a panoramic view of the laryngeal structures.

The reason for obtaining significantly lesser “time taken to achieve optimal laryngeal view” with the use of LMA CTrach could be attributed to the fact that the laryngeal view on LCD screen is obtained immediately after its insertion. On the other hand, with the use of fibreoptic bronchoscope, the PLMA is first inserted and secured, following which the fibreoptic bronchoscope is inserted via PLMA.

Various corrective manoeuvres have been advocated to improve the laryngeal view with the use of LMA CTrach i.e., DUD manoeuvre, MLM manoeuvre, Chandy’s manoeuvre, suctioning, light adjustment and reinsertion. But, there are no such dogmatic recommendations for corrective manoeuvres with the use of fibreoptic bronchoscope for visualisation of laryngeal structures via LMA. However, in the present study, we have used repositioning and reinsertion as the corrective manoeuvres. The higher use of corrective manoeuvres with the use of LMA CTrach was clinically not significant in the study. Haemodynamics during the study period were comparable which connotes the comparable haemodynamic response with both the

techniques. The reported complications were trivial and did not require any active intervention.

An important concern with the use of both the aforementioned techniques utilised in the present study is the replacement of ETT with PLMA or LMA CTrach. Most of the studies utilising the replacement of ETT has been conducted in anaesthetised and paralysed neurosurgical patients as it has been associated with favourable haemodynamic profile, less cerebral hyperaemia and a lower incidence of cough but may fret with the inadvertent risk of losing airway.<sup>[15,16]</sup> Similarly, the studies utilising such replacement in thyroidectomy were performed again in anaesthetised and paralysed patients<sup>[8,14]</sup> except a case report by Maroof *et al.*<sup>[7]</sup> where it was performed following reversal of neuromuscular blockade. In our previous study utilising LMA CTrach for this indication, we attempted replacement in anaesthetised and paralysed patients.<sup>[14]</sup> However, in the present study, it was done following reversal of neuromuscular blockade under adequate depth of anaesthesia – which not only allays the inadvertent risk of losing the airway but also resulted in early detection of vocal cord mobility.

The LMA CTrach lacks the gastric drain as it was manufactured primarily for facilitation of endotracheal intubation in difficult airway situation. Therefore, a remote risk of regurgitation and aspiration may be considered which can be avoided by following the fasting guidelines, PONV prophylaxis and aspiration prophylaxis when indicated. In the present study we anticipated this as a remote complication as the replacement of ETT was done following reversal of neuromuscular blockade because to which patient either did not receive IPPV or received assisted ventilation only for a short duration of time.

The first limitation of the study was inability to do double-blinding as it required two different techniques requiring different equipment; however, allocation

concealment was done. Secondly, the sample size was small. Thirdly, the limited availability of LMA CTrach is a concern. However, the result of the present study could be extrapolated to the other future Intubating LMAs allowing intubation under direct vision.

## CONCLUSION

To conclude, both LMA CTrach and fiberoptic bronchoscope are observed to be equally efficacious in terms of the optimal laryngeal view obtained, the ease of visualisation and the requirement of corrective manoeuvres to rule out RLN injury at the end of thyroidectomy. However, the LMA CTrach-assisted visualisation has been found to be easier to perform as reflected by the reduced time taken to achieve optimal laryngeal view, and thus can be considered a potential alternative for visualisation of laryngeal structures in thyroidectomy. Further studies with a larger sample size are warranted to validate the findings of the present study.

## Ethics approval taken

Institution Ethics Committee – Human Research, University College of Medical Sciences and GTB Hospital, Delhi-110095, INDIA.

## Declaration of patient consent

The authors certify that they have obtained all appropriate patient consent forms. In the form, the patient(s) has/have given his/her/their consent for his/her/their images and other clinical information to be reported in the journal. The patients understand that their names and initials will not be published and due efforts will be made to conceal their identity, but anonymity cannot be guaranteed.

## Acknowledgements

No external funding or competing interests declared. We would like to thank Dr Ruchi Kapoor, Dr Richa Pangtey & Dr Mamta Luckwal, consultants in the department of Anaesthesiology & Critical Care, University College of Medical Sciences, Delhi for helping in the perioperative management.

## Financial support and sponsorship

Nil.

## Conflicts of interest

There are no conflicts of interest.

## REFERENCES

- Hayward NJ, Grodski S, Yeung M, Johnson WR, Serpell J. Recurrent laryngeal nerve injury in thyroid surgery: A review. *ANZ J Surg* 2013;83:15-21.
- Joliat GR, Guarnero V, Demartines N, Schweizer V, MaETTer M. Recurrent laryngeal nerve injury after thyroid and parathyroid surgery: Incidence and postoperative evolution assessment. *Medicine (Baltimore)* 2017;96:e6674.
- Jeannon JP, Orabi AA, Bruch GA, Abdalsalam HA, Simo R. Diagnosis of recurrent laryngeal nerve palsy after thyroidectomy: A systematic review. *Int J Clin Pract* 2009;63:624-9.
- Perros P, Boelaert K, Colley S, Evans C, Evans RM, Gerrard Ba G, *et al.* Guidelines for the management of thyroid cancer. *Clin Endocrinol (Oxf)* 2014;81:1-122.
- Kundra P, Kumar V, Srinivasan K, Gopalakrishnan S, Krishnappa S. Laryngoscopic techniques to assess vocal cord mobility following thyroid surgery. *ANZ J Surg* 2010;80:817-21.
- Steurer M, Passler C, Denk DM, Schneider B, Niederle B, Bigenzahn W. Advantages of recurrent laryngeal nerve identification in thyroidectomy and parathyroidectomy and the importance of preoperative and postoperative laryngoscopic examination in more than 1000 nerves at risk. *Laryngoscope* 2002;112:124-33.
- Maroof M, Siddique M, Khan RM. Post- Thyroidectomy vocal cord examination by fibroscopy aided by the laryngeal mask airway. *Anaesthesia* 1992;47:445.
- Ellard L, Brown DH, Wong DT. Extubation of a difficult airway after thyroidectomy: Use of a flexible bronchoscope via the LMA-Classic™. *Can J Anaesth* 2012;59:53-7.
- Tan LZ, Tan DJ, Seet E. Laryngeal mask airway protector™ for intubation and extubation in thyroid surgeries: A case report. *Indian J Anaesth* 2018;62:545-8.
- Sastre JA, López T, del Barrio ME. Airtraq® videolaryngoscope for assessing vocal cord mobility at the end of thyroidectomy. *J Clin Anesth* 2017;38:3-4.
- Kumar A, Sinha C, Kumar A, Singh AK, Vardhan H, Bhavana K, Bhar D. Assessment of functionality of vocal cords using ultrasound before and after thyroid surgery: An observational study. *Indian J Anaesth* 2018;62:599-602.
- Timmermann A, Russo S, Graf BM. Evaluation of the CTrach--an intubating LMA with integrated fiberoptic system. *Br J Anaesth* 2006;96:516-21.
- Liu EHC, Gow RWL, Chen FG. The LMA CTrach, a new laryngeal mask airway for endotracheal intubation under vision: Evaluation in 100 patients. *Br J Anaesth* 2006;92:396-400.
- Chilkoti G, Mohta M, Saxena AK. Preliminary experience with LMA CTrach for assessment of glottic structures during thyroidectomy. *Anaesth Intensive Care* 2016;44:785-6.
- Hindman BJ, Santoni BG, Puttlitz CM, From RP, Todd MM. Intubation biomechanics: Laryngoscope force and cervical spine motion during intubation with Macintosh and Airtraq laryngoscopes. *Anesthesiology* 2014;121:260-71.
- Perelló-Cerdà L, Fàbregas N, López AM, Rios J, Tercero J, Carrero E, *et al.* ProSeal laryngeal mask airway attenuates systemic and cerebral hemodynamic response during awakening of neurosurgical patients: A randomised clinical trial. *J Neurosurg Anesthesiol* 2015;27:194-202.