



Case report

Intraosseous lipoma of the jaws: Review of the literature and rare case report

Nabil Kochaji^{a,*}, Sulieman Alhessani^a, Abdul Hadi Drbaa^b

^a Oral Histology & Pathology Department, Damascus University, Damascus, Syria

^b DDS, Albaath University 1992-1993, Homs, Syria

ARTICLE INFO

Keywords:

Lipoma
Intraosseous lipoma
Lipoma mandible
Rare case

ABSTRACT

Background: Lipoma is a benign tumor that arises at the expense of mature adipose tissue, it can occur anywhere in the body that contains adipose tissue. However, the intraosseous lipoma is considered a rare bone tumor, that affects the long and flat bones, but it is uncommon in the jaws. Usually, diagnosis based on clinical and radiographic features is insufficient and histopathology analysis is of utmost importance for the final diagnosis.

Case presentation: In this article, we present a case report of a 28-year-old female patient who visited the dentist with the intention of extracting an impacted tooth. She had no medical history with medications or genetic diseases. The tooth was extracted with a small soft mass that was subjected to histological analysis and it was found to be an intraosseous lipoma.

Discussion: Intraosseous lipoma is a rare tumor of the oral cavity, and it can be difficult to diagnose when only clinical and radiographic features are based, and the definitive diagnosis is based on histological examination. The treatment is complete surgical excision.

Conclusions and literature review: 30 cases were discovered and archived since 1948 until now, most of them were in the posterior region of mandibular, and the infection of females is higher than males with different final sub-diagnosis of types of intraosseous lipoma.

1. Introduction

Lipoma is a benign tumor of mature adipose tissue without cellular atypia, well-circumscribed, painless and slow-growing soft mass located in subcutaneous tissue, muscles, retroperitoneal space and bones, it is considered to be the rarest benign primary tumors of the bones [1].

Some hypotheses suggest that osseous lesions are primary benign tumor [2], while some of these hypotheses are likely to be a reactive bone lesion following bone infarct or trauma. Another hypothesis suggests that the cause of the tumor is conglomeration of fatty marrow, as commonly seen in calcaneus or vertebral bodies [3]. Although this tumor has been reported in the long bones: (humerus, radius, femur, tibia, fibula) as well as the calcaneus and cervical spine, also in the flat bones (ribs, pelvis, and skull), but in 20 % of all cases they are found in the head and neck region. However, only 1–4 % of lipomas are located in the oral cavity and the most common places of infection are the parotid gland, buccal mucosa, lip and tongue [4].

The literature reports that intraosseous lipoma usually occurs at age

between (20–65) years, and males are reported to be more frequently affected than females [2].

In general, intraosseous lipoma is asymptomatic [2] can be clinically silent, and then the lesion may be found incidentally during radiological investigation following an injury in the same region, but in some cases patients may suffer from swelling, pain and paresthesia [1].

Radiologically, some cases of intraosseous lipoma appear as well-defined osteolytic lesions with sclerotic borders [5] [6], But in other cases, some intraosseous lipomas are difficult to diagnose radiologically, just like the case in this article. Consequently, diagnosis of this lesion is based on clinical, radiological and histopathological features [5] [6], while emphasizing that the gold standard for accurate diagnosis remains the histopathological evaluation [7].

According to Cakarar et al. [5]. The etiology and characteristics of the jaw lesions are not clear, due to the small number of cases so far, stating the importance of documentation of each new case of intraosseous mandibular lipoma. Therefore, we present this rare case of mandibular lipoma, which was written according to SCARE criteria [8].

* Corresponding author at: Oral Maxillofacial Pathology, Damascus University, Syria.

E-mail addresses: oralpathology@gmail.com, nabil.kochaji@damsacusuniversity.edu.sy (N. Kochaji).

<https://doi.org/10.1016/j.ijscr.2022.107786>

Received 26 September 2022; Received in revised form 18 November 2022; Accepted 19 November 2022

Available online 23 November 2022

2210-2612/© 2022 The Authors. Published by Elsevier Ltd on behalf of IJS Publishing Group Ltd. This is an open access article under the CC BY-NC-ND license (<http://creativecommons.org/licenses/by-nc-nd/4.0/>).

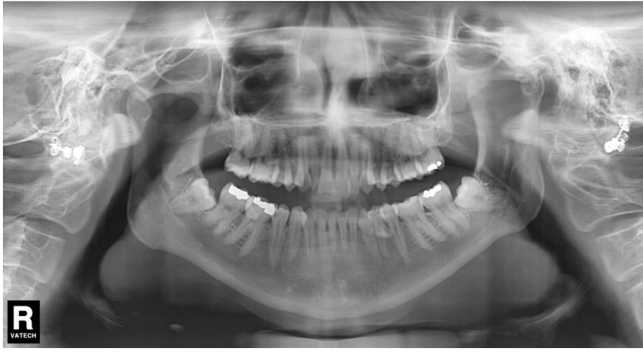

Fig. 1. Panoramic radiograph: the lesion does not appear clearly and definitively.



Fig. 2. Clinical view of the lesion after excision.

2. Presentation of case

Patient, female, aged 28 years was referred to her dentist with the aim of extraction the right impacted third molar. The patient's general health was good and there was neither a history of medical problems nor trauma, she did not suffer from any psychiatric or genetic diseases, and had no history with any specific medications. Extraoral examination did not reveal any abnormal results. Intraoral examination showed no dilatation or signs of inflammation.

The radiographic examination did not show clear signs of the presence of the lesion and there was no resorption of the root of the third molar (Fig. 1).

The surgery was performed by a general dentist with 20 years clinical experience, under local anesthesia and surgical suturing with 4/0 silk sutures, and the suture removed after a week. After the surgery, the patient was prescribed routine medications (analgesics and anti-edema).

On clinical examination, and after the extraction, the doctor found a yellowish, non-cystic mass, soft and not attached to the crown of the tooth or the root, measured in biggest dimensions: 12 × 10 × 06 mm (Fig. 2) with no traces of pus in the area. Dentigerous cyst was excluded as a differential diagnosis of the lesion because it is not associated with the crown of an impacted molar. Odontogenic Keratocyst was also excluded as a differential diagnosis due to the non-cystic lesion shape.

To make a final diagnosis, the sample was fixed in formaldehyde solution and sent directly to oral maxillofacial pathology service for histological examination. Microscopically, using traditional staining



Fig. 3. The stage of cutting and preparing the wax block.

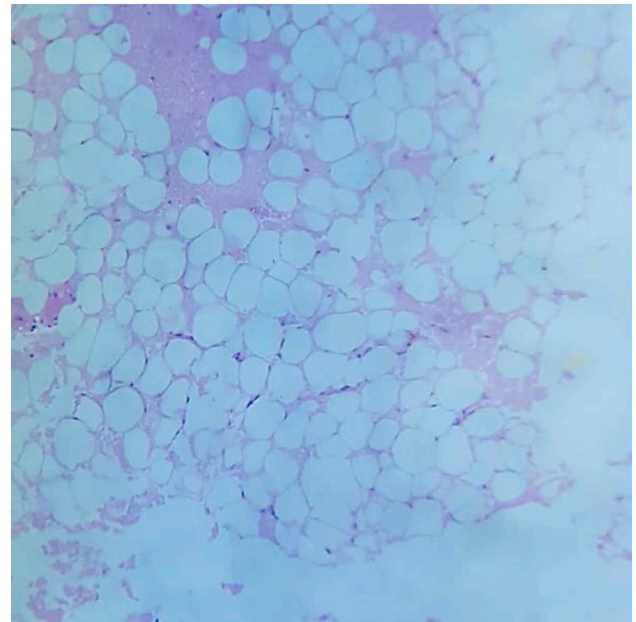


Fig. 4. Photomicrography showing mature adipose tissue (H&E; ×10).

(H&E) it was found that the lesion consisted of mature adipose tissue without cellular atypia. It was confirmed using immunohistochemical stains and the final diagnosis was Intraosseous lipoma (Figs. 3–5).

3. Discussion

Intraosseous lipoma (IOL) is one of the rarest benign tumors of the bone accounting for less than 0.1 % of primary bone tumor [5] [6], only in 20 % of all cases they are found in the head and neck region, while in the oral cavity it affects the soft tissues and the reason for the rareness of this tumor inside the jaws may be attributed to the lack of the lipid component inside these bones, in addition to the fact that the number of

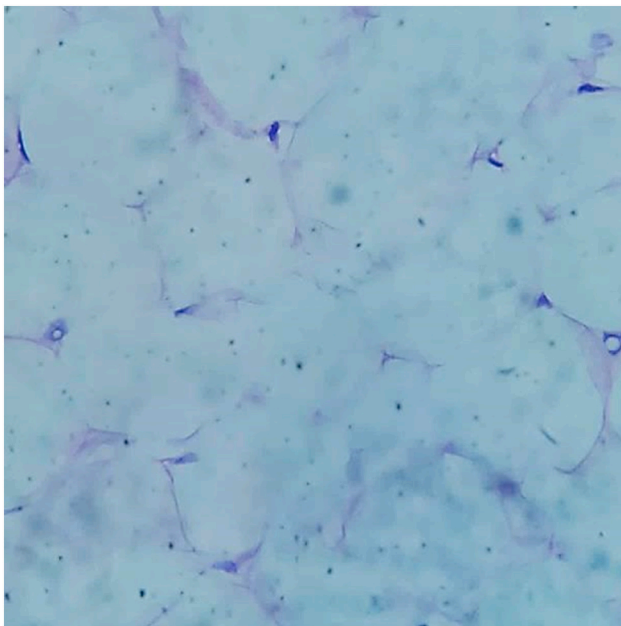


Fig. 5. Photomicrography showing mature adipose tissue (H&E; ×40).

archived cases is very few and does not give an idea about the abundance of this type of tumors inside of the jaws.

Returning to the medical literature, we found 30 cases of this tumor in the jaws since 1948 (Table 1) [9]. IOL of the jaws, like long bone IOL, can develop between (20–65) years old and the lesions were most

commonly found in the fourth and fifth decades [10].

Usually, IOL is asymptomatic and some authors even have stated that the intraosseous lipoma belongs to the “leave me alone” group of bony lesions and that any invasive method is unnecessary, although swelling, pain, chin numbness, hypoesthesia, trismus, and periodontal signs are also reported, that depends on the location and size of the lesion [7].

Intraosseous mandibular lipomas mainly arise in the posterior region of the mandible [1] [10].

In radiological X-rays they appear as clearly defined osteolytic lesions often with an osteosclerotic border and usually a single, soft, well-defined and slowly growing radiolucent lesion [6], but diagnosis of IOLs of the jaws is very difficult when based only on clinical and radiological features [7]. Thus, the definitive test that confirms the nature of the lesion is the result of histopathological examination [6].

4. Conclusion and literature review

Since the first case reported in 1948 only 30 cases have been reported. Almost all of them were uniclar radiolucent lesion (83.33 %), most cases had clear boundaries, but 16.66 % of cases did not specify the nature of the lesion border. The main location was body and posterior region of mandibular with percentage (66.66 %) followed by: Anterior mandibular (23.33 %) and maxillary (10 %). Although patients ranged between 20 and 65 (most commonly in 4th, 5th and 6th decades with 20 % per decade). However, there were 3 cases (10 %) of patient's ages below normal. Previously, the incidence of males was more than females, but after reviewing all archived cases in the medical literature, it was found that the incidence of females is higher (18 cases out of 30, with percentage 60 %). Pathological diagnosis: 21 cases were lipoma (70 %), 4 cases were angiolipoma (13.33 %), 3 cases were fibrolipoma

Table 1

Summary of site, radiographic features and histological diagnosis of the published cases of Intraosseous lipoma of the jaw since 1948.

Authors	Year	Sex	Age	Site	Radiographic features	Histological diagnosis
Oringer	1948	F	37	Lower second molar	Well-defined radiolucency	Intraosseous Lipoma
Newman	1957	M	65	Associated to impacted third molar	Well-defined radiolucency	Fibrolipoma
Johnson	1969	M	21	Associated to impacted second and third molars	Well-defined radiolucency	Intraosseous Lipoma
Polte et al	1976	M	39	Second premolar to second molar	Moderate well-defined radiolucency	Angiolipoma
Lewis et al.	1980	F	56	Mandibular body	Multilocular well-defined radiolucency	Angiolipoma
Steiner et al.	1981	M	50	Right third molar	Well-defined radiolucency	Parosteal lipoma
Miller et al	1982	M	51	Impacted left third molar	Well-defined radiolucency	Intraosseous Lipoma
Heir and Geron	1983	F	43	Ramus	Well-defined radiolucency	Intraosseous Lipoma
Barker and Sloan	1986	F	53	Impacted right third molar	Well-defined radiolucency	Intraosseous Lipoma
Manganaro et al	1994	F	51	Posterior left mandible and mandibular ramus	Well-defined radiolucid/radiopaque	Angiolipoma
Koami et al	1995	M	59	Mandibular symphysis	Well-defined radiolucency	Intraosseous Lipoma
Sakashit et al	1998	M	17	Left Side of Maxilla	Well-defined radiolucency	Intraosseous Lipoma
Buric et al.	2001	F	62	Mandibular symphysis	Multilocular well-defined radiolucency	Intraosseous Lipoma
Keogh et al.	2004	F	56	Impacted right third molar	Well-defined radiolucency	Intraosseous Lipoma
Colella et al. [12]	2005	F	20	Posterior left mandible	Well-defined radiolucency	Intraosseous Lipoma
Darling and Daley	2005	F	22	Anterior mandible(not associated with the apex of the anterior teeth)	Well-defined radiolucency	Intraosseous Lipoma
Cakarar et al	2009	F	45	Anterior mandible (associated to the apex of the anterior teeth)	Well-defined radiolucency	Intraosseous Lipoma
Gonzales et al	2010	F	61	Left mandibular ramus	Radiolucency	Intraosseous Lipoma
Silva et al. [13]	2010	M	18	Right mandibular body	Well-defined radiolucency	Intraosseous Lipoma
Morais et al	2011	F	39	Upper left third molar	–	Intraosseous Lipoma
Hemavathy et al	2012	F	21	From the right mandibular lateral incisor to the left ramus	Well-defined radiolucency	Angiolipoma
Olguç et al. [14]	2012	F	48	Incisor area of the mandible	Radiolucency	intraosseous lipoma
Basheer et al	2013	M	15	Right mandibular	Radiopaque	Intraosseous lipoma
Castellani et al	2015	F	25	Right mandibular ramus	Radiolucency	Fibrolipoma
Waškowska et al. [6]	2017	M	32	Right body of the mandible	Well-defined radiolucency	intraosseous lipoma
Sanjuan et al. [15]	2017	F	50	Left mandibular ramus and condyle	Multilocular well-defined radiolucency	intraosseous lipoma
Cooper et al. [16]	2017	M	53	Right mandible	Well-demarcated unilocular radiolucency	spindle cell lipoma
Tabakovic et al. [17]	2018	F	43	Left side of Maxilla	Radiopaque	Intraosseous lipoma
Moghadam et al. [18]	2021	M	39	Left lateral incisor and canine of mandibular	Well-defined radiolucency	Fibrolipoma
Maksoud and Aoun [7]	2022	F	37	Anterior region of the mandible	Well-defined unilocular radiolucency	Intraosseous lipoma

(10 %) and one case each of Parosteal lipoma and spindle cell lipoma.

According to Milgram: the transformation of Lipoma to Liposarcoma should not be excluded, but the rate of Liposarcoma is mainly very low (1 case per 2.5 million people) [11], and the percentage of IOL is also low (0.1 %) and less than all of that is IOL in the jaws (30 cases).

Thus, the ratio of transformation of IOL in the jaws to Liposarcoma may be excluded so far due to the paucity of archived cases.

We conclude from this that we need to record and archive each case of IOL in the jaws to have a comprehensive idea of the transformation of this type of tumor towards malignancy, and the manifestations of the transformation clinically, radiologically and histologically. In addition, we have a lot of questions that we don't have an exact answer to yet. For example:

1. Was the long-term follow-up (more than 5 years) done for all cases of IOL and monitoring for any manifestations of transformation, recurrence and metastasis?

2. Were all archived lesions encapsulated?

3. Does the presence of the capsule affect the transformation to malignancy or not?

4. Does the sub-diagnosis of lipoma affect the rate of transformation or not?

These and other questions necessitate that we archive and write down everything we know about this type of tumor to increase medical knowledge about all these mysterious points and more.

Consent

Written informed consent was obtained from the patient for publication of this case report and accompanying photographs.

Sources of funding

We have no sponsors.

Ethical approval

Ethical approval has been exempted because this is a case report and no new studies or new techniques were carried out.

Registration of research studies

This paper is case report. The authors don't need to register this work.

Guarantor

Corresponding author is the guarantor for this case report.

Provenance and peer review

Not commissioned, externally peer-reviewed.

Patient perspective

Patient was quite happy with the surgical procedure and overall treatment.

CRediT authorship contribution statement

Nabil Kochaji: diagnosis of case and reporting, and paper writing.

Sulieaman Alhessani: literature review and paper writing.

Abdul Hadi Drbaa: surgery part of the work and following up patient.

Declaration of competing interest

Authors have no conflicts of interest.

Acknowledgements

None.

References

- [1] N. Burić, et al., Intraosseous mandibular lipoma: a case report and review of the literature, *J. Oral Maxillofac. Surg.* 59 (11) (2001) 1367–1371.
- [2] J.W. Milgram, Intraosseous lipomas. A clinicopathologic study of 66 cases, *Clin. Orthop. Relat. Res.* 231 (1988) 277–302.
- [3] J. Appenzeller, S. Weitzner, Intraosseous lipoma of os calcis: case report and review of literature of intraosseous lipoma of extremities, *Clin. Orthop. Relat. Res.* 101 (1974) 171–175.
- [4] M.A. Furlong, J.C. Fanburg-Smith, E.L. Childers, Lipoma of the oral and maxillofacial region: Site and subclassification of 125 cases, *Oral Surg. Oral Med. Oral Pathol. Oral Radiol. Endod.* 98 (4) (2004) 441–450.
- [5] S. Cakarar, et al., Intraosseous lipoma of the mandible: a case report and review of the literature, *Int. J. Oral Maxillofac. Surg.* 38 (8) (2009) 900–902.
- [6] J. Waškowska, et al., Intraosseous lipoma of the mandibula: a case report and review of the literature, *Open Med.* 12 (1) (2017) 45–49.
- [7] C. Maksoud, G. Aoun, Intraosseous lipoma: a report of a case in the mandibular symphysis region, *Cureus* 14 (3) (2022).
- [8] R.A. Agha, et al., The PROCESS 2018 statement: updating consensus preferred reporting of CasE series in surgery (PROCESS) guidelines, *Int. J. Surg.* 60 (2018) 279–282.
- [9] A. Sanjuan, et al., Condylar intramedullary intraosseous lipoma: contribution of a new case and review of the literature, *J. Clin. Exp. Dent.* 9 (3) (2017), e498.
- [10] P.V. Keogh, D. McDonnell, M. Toner, Intraosseous mandibular lipoma (IML): a case report and review of the literature, *J. Ir. Dent. Assoc.* 50 (3) (2004) 132–134.
- [11] A. Jones, et al., Lipoma or liposarcoma? A cautionary case report, *J. Plast. Reconstr. Aesthet. Surg.* 65 (1) (2012) e11–e14.
- [12] G. Colella, et al., ZEBRA XXVI part 2. Intraosseous lipoma, *J. Endod.* 29 (8) (2003) 535–537.
- [13] A. Sadio, et al., Lipoma gástrico: una causa rara de hemorragia digestiva Alta, *Rev. Esp. Enferm. Dig.* 102 (6) (2010) 398–400.
- [14] N. Büyükyüz, et al., Intraosseous lipoma of the mandible: a case report and review of the literature, *Int. J. Oral Maxillofac. Pathol.* 3 (2012) 26–30.
- [15] A. Sanjuan, et al., Condylar intramedullary intraosseous lipoma: contribution of a new case and review of the literature, *J. Clin. Exp. Dent* 9 (3) (2017) e498–e502.
- [16] T.J. Cooper, et al., Intraosseous spindle cell lipoma of the mandible: case report, *Br. J. Oral Maxillofac. Surg.* 55 (8) (2017) 839–840.
- [17] S. Tabakovic, et al., Intraosseous lipoma of the maxillary tuberosity: a case report, *J. Stomatol. Oral Maxillofac. Surg.* 119 (2) (2018) 151–153.
- [18] S. Atarbashi-Moghadam, et al., Clinicoradiographic Features and Histopathologic Variations of Intraosseous Lipoma: Report of a Case and Review of the Literature. *Case Reports in Dentistry* 2021, 2021.