

Incidental Finding of Leiomyoma in Mayer-Rokitansky-Kuster-Hauser Syndrome

Journal of Investigative Medicine High
Impact Case Reports
Volume 9: 1–4
© 2021 American Federation for
Medical Research
DOI: 10.1177/23247096211014690
journals.sagepub.com/home/hic


Oyetokunbo Ibidapo-Obe, MD¹, Jerome Okudo, MD² ,
and Oladunni Filani, MD³

Abstract

Mayer-Rokitansky-Kuster-Hauser (MRKH) syndrome is a sexual developmental disorder. In this disorder, there is a congenital absence of the uterus and vagina with normal external genitalia. The etiology is not well understood. Variations of this condition exist that may include congenital abnormalities and psychological problems. In this article, we discuss the case of a 47-year-old African American female who presented with acute renal failure, solitary right kidney, and a pelvic mass extending from the pelvis to the right hypochondrium determined to be a fibroid. The patient was managed by a multidisciplinary team, dialyzed, and planned for removal of the mass. While understanding the low probability of having fibroids without a uterus, fibroids should not be excluded from such patients. It is also important to consider the emotional and psychological well-being of such patients.

Keywords

Mayer-Rokitansky-Kuster-Hauser syndrome, MRKH, leiomyoma, Mullerian duct

Introduction

Mayer-Rokitansky-Kuster-Hauser (MRKH) syndrome is associated with an absence or incomplete development of the Mullerian duct.¹ Three different types of this syndrome may exist: (1) the uterus and upper vagina are absent; however, fallopian tubes and normal ovaries exist; (2) ovarian or kidney malformation and no aplasia or hypoplasia of the uterus and vagina; (3) kidney dysfunction in association with other congenital anomalies (skeletal, cardiac, and auditory).² Familial clustering of this syndrome in conjunction with congenital anomalies may suggest a genetic link. While hormone levels may be normal in these patients, there may be hormone deregulation in which some patients have hyperandrogenemia and hyperprolactinemia. Luteinizing hormone (LH) and follicle-stimulating hormone (FSH) are normal in MRKH syndrome, which may indicate appropriate ovarian function. Testosterone levels are in the normal female range.

The incidence is 1 in 5000 female births.³ As a result of hormonal dysregulation, secondary sex characteristics may be affected with resultant amenorrhea during the onset of puberty. This condition is the second most common cause of primary amenorrhea after ovarian failure in reproductive aged women.⁴ Psychological issues include low self-esteem, emotional distress, depression, rejection, among others.⁵⁻⁷

Very few cases of MRKH have been described in the medical literature.

Case Description

A 47-year-old African American female with HIV, hypertension, hepatitis B, and hepatitis C presented to the emergency room with severe right-sided chest pain, nonproductive cough, and fever for 2 days. She had never had a menstrual period. She smoked one half pack of cigarettes, cocaine, and injected heroin daily for over 10 years. There was cachexia, prolonged expiratory phase on auscultation, and an abdominal mass extending from the pelvis to the right hypochondrium. Pelvic examination revealed a shallow vaginal canal,

¹The University of Texas Medical Branch, Galveston, TX, USA

²UCLA—Kern Medical, Bakersfield, CA, USA

³Howard University Hospital, Washington, DC, USA

Received December 20, 2020. Revised April 8, 2021. Accepted April 10, 2021.

Corresponding Author:

Jerome Okudo, Valley Fever Institute, UCLA—Kern Medical, 1700 Mount Vernon Avenue, Bakersfield, CA 93306, USA.

Email: jeromeokudo@yahoo.com



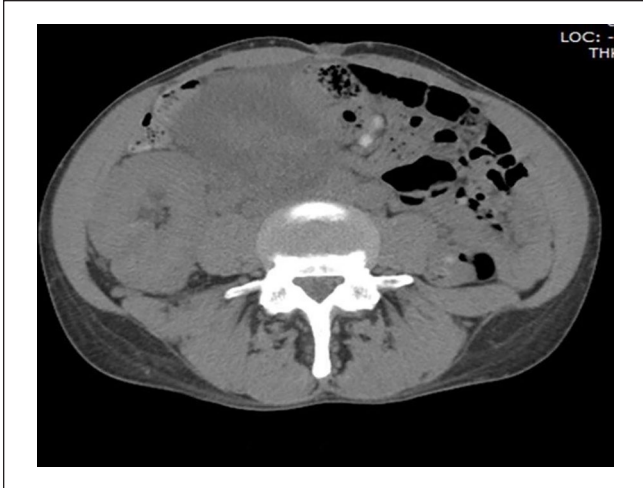


Figure 1. Computed tomography scan of abdomen and pelvis I: showing well-circumscribed, complex pelvic mass (19 cm × 11.7 cm × 9.6 cm dimensions) and a solitary right kidney.

and the cervix was not visualized. Chest X-ray showed right basilar infiltrate with a small right pleural effusion. Her blood urea nitrogen (BUN)/creatinine ratio was 40/4.9 (approximately 8). CA-125, α -fetoprotein, human chorionic gonadotropin (hCG), and lactate dehydrogenase (LDH) were all within normal limits. Colonoscopy was negative. On admission, the patient received azithromycin and felt better though found to have worsening renal function with BUN/creatinine persistently trending upward—BUN/creatinine at 63/5.9 and was started on dialysis. Computed tomography (CT) scan of abdomen and pelvis was done. Cystoscopy revealed obstruction of the right ureter. Right nephrostomy tube was placed to relieve obstruction.

CT scan showed well-circumscribed complex pelvic mass measuring 19 cm by 11.7 cm by 9.6 cm, and a solitary right kidney (see Figure 1). Pelvis mass biopsy revealed a well-differentiated smooth muscle tumor with no atypia or mitotic activity (see Figure 2). Tumor cells were positive for desmin and estrogen receptors, favoring smooth muscle origin. Pelvic ultrasound was consistent with a diagnosis of MRKH, showing a blind vagina and little to no uterus, with both ovaries appearing normal. MRKH syndrome was a top differential considering her solitary kidney and primary amenorrhea and excluded by pelvic scan and hormonal profile were the following: (LH and FSH) primary amenorrhea, androgen insensitivity syndrome (shallow vaginal canal and the cervix not visualized), cervical dysgenesis (vaginal examination), and gonadal dysgenesis (Turner's syndrome-no stigmata). No skeletal abnormalities were seen by magnetic resonance imaging (MRI). Attempts to replace nephrostomy tube with intra-ureteral stent were unsuccessful due to persistent compression by pelvic mass. She was discharged with stent in situ and scheduled for dialysis 3 times per week and for follow-up with gynecology within 1 week for removal of fibroid tumor for which she declined.

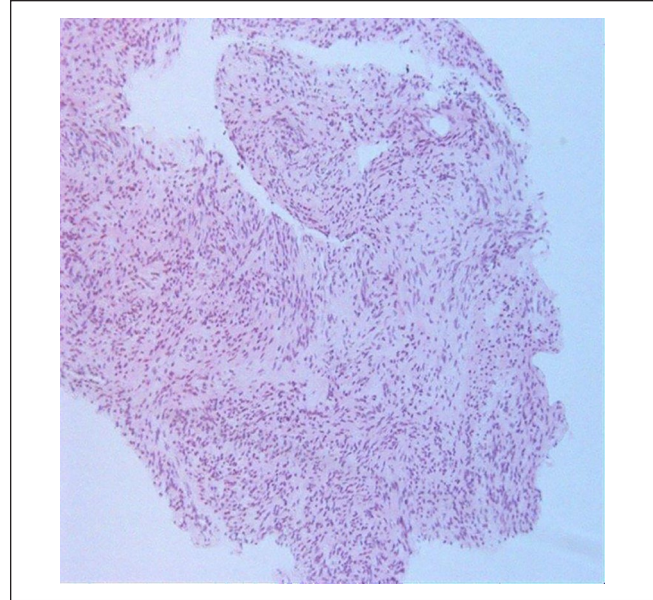


Figure 2. Low-power microscopy: tissue biopsy showing well-differentiated smooth muscle tumor with no atypia or mitotic activity.

Discussion

In a patient with MRKH syndrome, the proximal two thirds of the vagina do not develop and patients have some of the VACTERL-associated conditions that include but are not limited to the vertebra, heart, urogenital, and ear anomalies.^{1,3} Secondary sexual characteristics are present with a 46 XX karyotype.^{4,8} In order to make a definitive diagnosis, a clinical examination followed by pelvic ultrasonogram and MRI, and karyotype are required.^{1-4,8} For many patients, the initial presentation is normal female sexual characteristics with primary amenorrhea. According to medical literature, there are many causes of amenorrhea and MRKH syndrome is the second most common cause.^{4,8,9}

This syndrome has gone through multiple revisions in its description to capture the entire picture between 1829 and 1961. In 1829, Mayer described various vaginal anomalies not limited to duplications because of abnormal development of the Mullerian ducts. In 1838, Rokitansky described uterine and vaginal agenesis. Kuster in 1910 recognized renal abnormalities (renal ectopy or agenesis) and skeletal abnormalities. Hauser made the distinction between MRKH and testicular feminization in 1961.^{10,11} It may either be sporadic, familial, or genetic in etiology. Transmission is autosomal dominant, and multiple patients with this genetic condition may have variable presentation. A link between a loss-of-function mutation in the *WNT4* gene and MRKH has been described in the medical literature.^{11,12}

We present a case of Mullerian agenesis in a patient with a biopsy-confirmed large fibroid tumor, from the vestigial Mullerian remnant that grew large enough to obstruct her only right kidney resulting in dialysis dependency.

Our patient who had worsening renal function, solitary kidney, amenorrhea, and a pelvic mass was incidentally discovered to have MRKH with leiomyoma at index presentation with no documented history of MRKH. Recent cases of MRKH syndrome with fibroids showed that patients varied from ages 20 through 70 years and with no specific country predilection. Twenty-one percent of MRKH patients had a solitary kidney, but unilateral renal anomalies range from 30% to 50%.^{4,9} The congenital malformations observed in this patient suggested an MRKH-like phenotype.^{1,11}

In a review of the medical literature in 35 patients with MRKH and leiomyoma, the origin of leiomyoma in MRKH patients was the uterine remnant in 65% of patients.⁴ Other origins include multiple uterine remnants, fibrous myometrial bands, and the broad ligament, round ligament, vascular leiomyoma, and parametrial tissue.^{4,8} Leiomyomas can originate from the myometrial portion of the uterus. They are known to have fibromuscular tissue comprising smooth muscles (from a study of embryology, Mullerian ducts at the proximal ends have smooth muscle cells but are primarily endodermal in origin) and can grow because of estrogen stimulation; considering that patients with MRKH have ovaries with normal hormone levels, fibroids in these patients undergo the same patterns like in normal patients. In addition, it has been suggested that estrogen receptor sensitivity or concentration in the remnant tissue may be potentially responsible.

Surgical or nonsurgical treatment for MRKH is available, but this is dependent on individual needs, patient motivation, and available options.¹³ There are 2 main types of procedures: (1) A neovagina is created for patients who have signified psychological readiness for sexual activity.¹¹ The physiological defects are both medically and surgically treatable, permitting sexual function.¹³ With assisted reproductive techniques and surrogacy, MRKH syndrome patients can reproduce.¹⁴ (2) An already identified and prepared canal lined with bowel as mucous membrane is utilized for vaginal replacement.¹⁵ Adherence to a home dilation schedule and recommending consistent condom use to prevent infections such as HIV and human papilloma virus are key. Regular examinations should be performed to assess for vaginal stenosis.¹⁵

The patient's polysubstance abuse made her unstable in the hospital setting and complicated any inpatient plans to treat her and this reflected in her subsequent loss to follow-up. There is a growing need to explore the emotional and psychological well-being of MRKH patients because of their unique experiences,⁵⁻⁷ because they feel rejection, depression, hindrance of independence in younger women, loss of self-esteem, anxiety, loss of identity, and feeling other than. Many patients receive a diagnosis of MRKH because of primary amenorrhea in adolescence. It is appropriate to receive psychological intervention during the transition from adolescence to adulthood; however, our patient did not receive this.⁵⁻⁷ Management should be multidisciplinary and should be tailored to specific needs for specific patients.

Declaration of Conflicting Interests

The author(s) declared no potential conflicts of interest with respect to the research, authorship, and/or publication of this article.

Funding

The author(s) received no financial support for the research, authorship, and/or publication of this article.

Ethics Approval

Our institution does not require ethical approval for reporting individual cases or series.

Informed Consent

Written informed consent was obtained from the patient for their anonymized information to be published in this article.

ORCID iD

Jerome Okudo  <https://orcid.org/0000-0002-2183-7024>

References

1. Folch M, Pigem I, Konje JC. Mullerian agenesis: etiology, diagnosis, and management. *Obstet Gynecol Surv.* 2000;55:644-649.
2. Hong-Xin P, Guang-Nan L. Phenotypic and clinical aspects of Mayer-Rokitansky-Küster-Hauser syndrome in a Chinese population: an analysis of 594 patients. *Fertil Steril.* 2016;106:1190-1194.
3. Hoo PS, Norhaslinda AR, Reza JNS. Rare case of leiomyoma and adenomyosis in Mayer-Rokitansky-Küster-Hauser syndrome. *Case Rep Obstet Gynecol.* 2016;2016:3725043.
4. Blontzos N, Iavazzo C, Vorgias G, Kalinoglou N. Leiomyoma development in Mayer-Rokitansky-Küster-Hauser syndrome: a case report and a narrative review of the literature. *Obstet Gynecol Sci.* 2019;62:294-297.
5. Weijenborg PTM, Kluijvers KB, Dessens AB, Kate-Booij MJ, Both S. Sexual functioning, sexual esteem, genital self-image and psychological and relational functioning in women with Mayer-Rokitansky-Küster-Hauser syndrome: a case-control study. *Hum Reprod.* 2019;34:1661-1673.
6. Patterson CJ, Crawford R, Jahoda A. Exploring the psychological impact of Mayer-Rokitansky-Küster-Hauser syndrome on young women: an interpretative phenomenological analysis. *J Health Psychol.* 2016;21:1228-1240.
7. Ernst ME, Sandberg DE, Keegan C, Quint EH, Lossie AC, Yashar BM. The lived experience of MRKH: sharing health information with peers. *J Pediatr Adolesc Gynecol.* 2016;29:154-158.
8. Wehbe GS, Bitar R, Zreik T, Samaha M, Walter C, Sleiman Z. Intra-peritoneal leiomyoma of the round ligament in a patient with Mayer-Rokitansky-Küster-Hauser (MRKH) syndrome. *Facts Views Vis Obgyn.* 2016;8:233-235.
9. Amaratunga T, Kirkpatrick I, Yi Y, Karlicki F. Ectopic pelvic fibroid in a woman with uterine agenesis and Mayer-Rokitansky-Küster-Hauser syndrome. *Ultrasound Q.* 2017;33:237-241.

10. Renuka M, Goyal A, Bhardawaj M. Fibroid with unilateral streak ovary in Mullerian agenesis! A rare case report. *Int J Reprod Contracept Obstet Gynecol.* 2018;7:3392-3396.
11. Bignon-Lauber A, Konrad D, Navratil F, Schoenle EJ. A WNT4 mutation associated with Mullerian-duct regression and virilization in a 46, XX woman. *N Engl J Med.* 2004;351:792-798.
12. Egbe TO, Kobenge FM, Arlette MMJ, Nyemb JE, Mbu RE. A case of Mayer-Rokitansky-Küster-Hauser syndrome in a low-resource tertiary hospital in Douala, Cameroon. *SAGE Open Med Case Rep.* 2019;7:2050313X19830817.
13. Heller-Boersma JG, Edmonds DK, Schmidt UH. A cognitive behavioural model and therapy for utero-vaginal agenesis (Mayer-Rokitansky-Küster-Hauser syndrome: MRKH). *Behav Cogn Psychother.* 2009;37:449-467.
14. Bean EJ, Mazur T, Robinson AD. Mayer-Rokitansky-Küster-Hauser syndrome: sexuality, psychological effects, and quality of life. *J Pediatr Adolesc Gynecol.* 2009;22:339-346.
15. Hensle TW, Shabsigh A, Shabsigh R, Reiley EA, Meyer-Bahlburg HF. Sexual function following bowel vaginoplasty. *J Urol.* 2006;175:2283-2286.