

L5 vertebrectomy for the surgical treatment of tumoral and traumatic lesions of L5 vertebra

Tuncay Kaner,¹ Tunc Oktenoglu,²
Mehdi Sasani,² Ali Fahir Ozer³

¹Neurosurgery Department, Pendik State Hospital; ²Neurosurgery Department, American Hospital; ³Neurosurgery Department, Koc University School of Medicine, Istanbul, Turkey

Abstract

We retrospectively reviewed the clinical characteristics and the surgical results of seven patients treated with L5 vertebrectomy. The pathologies, clinical characteristics, preoperative and postoperative radiological findings, surgical techniques, and instrumentation for seven patients operated on between 1998 and 2009 are presented in this article. Biopsies were performed on all patients except those involving trauma. Patients were followed up at three-month intervals in the first year, at 6-month intervals in the second year, and on a regular basis afterward. One patient had a traumatic L5 burst fracture; the other six had tumoral pathologies in the L5 vertebrae. One tumoral lesion was a chordoma, another was a hemangioma, and the remaining four were metastatic lesions. Radiotherapy and chemotherapy were performed for the metastatic tumor patients during the postoperative period. Patients with renal cancer and chordoma survived for 3 years; patients with lung cancer and bladder cancer survived for 1 year; and patients with breast cancer survived for 16 months. The lumbosacral region presents significant stabilization problems because of the presence of sacral slope. In our opinion, if the lesion involves only the L5 vertebra, anterior cage-filled bone cement or bone graft should be performed, as dictated by the pathology and posterior transpedicular instrumentation. If the lesion involves the L4 vertebra or the sacrum and the L5 vertebra, the instrumentation can be extended to cover other segments with sacral attachments. The present cases involved only L5 vertebra and treatment with short-segment stabilization covering the anterior and posterior columns.

Introduction

Using an anterior approach to the patholo-

gies in L5 vertebrae is challenging because of the anatomical features of the lumbosacral junction.¹ In addition, the lumbosacral junction of the spine has special features in terms of spinal biomechanics, as this region carries the maximum load of the spine and is also a transitional region that joins the dynamic lower lumbar region with the relatively motionless sacrum and pelvis. Because of the sacral slope, the L5 vertebra is affected by sliding and compressive forces.¹ Ensuring stabilization in the junctional regions of the spine is difficult.² In the lumbosacral region, even greater difficulties are encountered when attempting to adapt the weight of the entire body to the pelvis in a healthy way. In this region, because only the anterior or posterior approaches are insufficient, L5 vertebrectomy with anterior and posterior rigid short-segment stabilization should be performed using an anterior approach in the same surgical session to provide 360 degrees of spine stabilization.^{1,3-5} Short-segment stabilization is adequate if the pathology involves only the L5 vertebra.

Metastatic or primary tumors, trauma, and infection are prominent pathologies of the L5 vertebrae.

In this retrospective review, we discuss the pathologies, clinical features and results of applied surgery in seven patients treated with L5 vertebrectomy with anterior and posterior rigid short-segment stabilization.

Materials and Methods

Patients

We retrospectively reviewed seven patients who were treated with an L5 vertebrectomy in our clinic from 1998 to 2009 and evaluated the follow-up results. The average age of the seven patients (five females and two males) was 52 (ranging from 35 to 68). One patient had a traumatic burst fracture of L5, one had an L5 chordoma, one had a hemangioma, and the other four had metastatic tumors (metastatic bladder cancer, breast cancer metastasis, renal cancer metastasis, and lung metastasis). Preoperative and postoperative direct X-ray radiographs, computerized tomography (CT), and magnetic resonance imaging (MRI) were performed on all patients. For surgical planning, preoperative biopsies were performed on all patients with tumoral lesions. Preoperative tumor embolization was used only in the hemangioma patient. Patients were followed up at three-month intervals during the first year, six-month intervals during the second year, and regularly after the second year. The ages, pathologies, symptoms, and clinical features; preoperative and postoperative radiological findings; applied surgical techniques;

Correspondence: Ali Fahir Ozer, Neurosurgery Department, Koc University School of Medicine, Rumelifeneri Yolu, 34450 Sariyer, Istanbul, Turkey.
Tel. +90.212.338.11.76 - Fax: +90.212.338.11.68.
E-mail: alifahirozer@gmail.com

Key words: L5 vertebrectomy, short-segment stabilization, lumbosacral region pathologies, spinal neoplasm, fifth lumbar burst fracture, instability of the lumbosacral region.

Received for publication: 21 September 2011.

Revision received: 3 January 2012.

Accepted for publication: 6 January 2012.

This work is licensed under a Creative Commons Attribution NonCommercial 3.0 License (CC BY-NC 3.0).

©Copyright T. Kaner et al., 2012
Licensee PAGEPress srl, Italy
Orthopedic Reviews 2012; 4:e10
doi:10.4081/or.2012.e10

complications; and instrumentation used in the seven patients who were treated with an L5 vertebrectomy are reviewed and summarized in Table 1.

Surgical technique

In tumor patients, the first stage of the operation laminectomy was performed, and whole pedicles were removed to the vertebral corpus; L4-S1 transpedicular instrumentation was then performed. In the second stage, the patient was turned over to a supine position, and a transperitoneal approach was used to better manipulate the L5 vertebra. Muscles were spread from the corpus, and a total corpectomy was performed. The appropriate cages were applied and filled with bone cement. The entire operation was performed under a surgical microscope.

In the hemangioma patients, the same procedure was performed; the only difference was that the cages were filled with bone grafts.

Results

The mean follow-up period was 46.3 months (range, 12 to 128 months). Intraoperative complications did not occur, and all patients were mobilized early in the postoperative period. In postoperative follow-ups and control radiographs, no complications, such as screw malposition or instrumentation insufficiency occurred, and no patient was submitted to revision surgery. Postoperative radiotherapy plus chemotherapy were performed in metastatic tumor patients. Despite postoperative radio-

Table 1. Patient data.

Patient No.	Age/Sex	Year of Operation	Clinical Symptoms	Pathology	Treatment	Follow-up
1	57/M	2004	LBP	L5 Renal ca metastasis	AEC+PRS, radiation therapy and chemotherapy	Died in year 3
2	35/F	1998	LBP and bilaterally sciatica	L5 Burst fracture	Anterior stabilization+ fusion with bone graft and posterior long rigid stabilization	Asymptomatic at year 12
3	65/F	2005	LBP	L5 Lung ca metastasis	AEC+PRS, Radiation therapy and chemotherapy	Died in the 12 th postoperative month
4	55/F	2007	LBP	L5 Bladder metastasis	AEC+PRS, radiation therapy and chemotherapy	Died in the 12 th postoperative month
5	68/M	2004	LBP and right sciatica	L5 chordoma	AEC+PRS; no adjuvant therapy after surgery	Recurrence 2 yr after surgery; radiation therapy and chemotherapy after recurrence; died in the 3 rd postoperative year
6	40/F	1994	LBP	L5 breast ca metastasis	Anterior stabilization with the Rezaian system+ PRS; radiation therapy and chemotherapy	Died in the 16 th postoperative month
7	42/F	2008	LBP	Hemangioma	AEC+ fusion with autograft and PRS	Asymptomatic at 1 yr

AEC, anterior expandable cage; PRS, posterior rigid stabilization; LBP, low back pain; Ca, cancer.

therapy and chemotherapy, the patient who was operated on for breast cancer metastasis (40/F) died during postoperative month 16; patients who were operated on for lung cancer metastasis (65/F) (Figure 1) and bladder cancer metastasis (55/F) died during postoperative month 12; the patient who was operated on for renal cancer metastasis (57/M) died in postoperative year 3. The disease listed was the cause of death in all cases. The patient who was operated on for chordoma (68/M) (Figure 2) did not receive radiotherapy after the first operation; consequently, a recurrence was observed two years later. The patient received radiotherapy and chemotherapy after the recurrence but was not admitted for reoperation. The patient died during postoperative year 3. A fusion was observed in the posttraumatic L5 burst fracture patient (35/F) who had received L5 vertebrectomy and a tibia allograft with anterior interbody fusion (ALIF) and posterior rigid stabilization. This occurred in the first postoperative year, and the patient was living with no complaints at the time of this report. The patient with hemangioma (42/F) was under follow-up and was asymptomatic at one year (Figure 3).

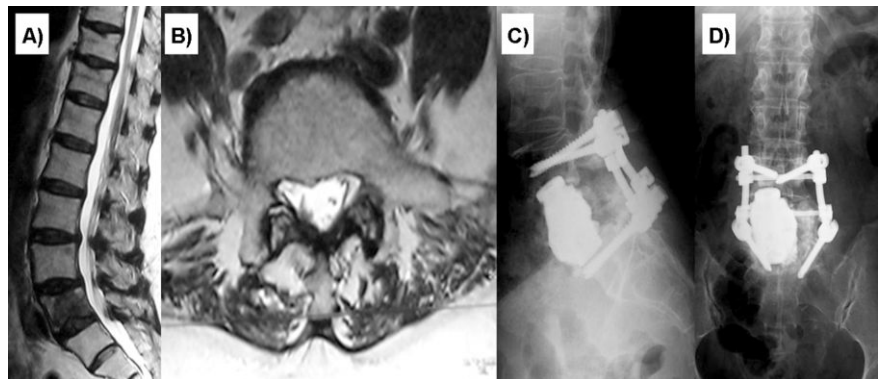


Figure 1. A 65-year-old female patient with lung cancer metastasis in her L5 vertebra (patient #3). A) Preoperative sagittal T2-weighted MR imaging of the patient; B) Preoperative axial T2-weighted MR imaging of the patient; C) Lateral radiographic view after the operation; D) Antero-posterior radiographic view after the operation.

sacrum and lumbosacral junction cause clinically complicated problems.^{1,2} Not only is the surgery difficult, but because of the biomechanical properties, careful stabilization is required.² In this region, trauma, infection, degenerative changes, scoliosis, and kyphosis with spondylolisthesis are quite common; however, neoplasm is extremely rare. We present one trauma case, five tumor cases and one hemangioma case from our institution. Compared with other regions of the spine, lumbosacral stabilization presents specific features.^{1,2,4-6} In this region, a mobile system is

connected to a fixed system together with a specific anatomical structure of very strong bands and muscle groups. Horizontal facet joints are found in this region where the anterior and posterior longitudinal ligaments are thickest and the masses of the muscle groups are greatest. As a driving force to the front, the effect of shear force on the last lumbar vertebra is excessive because of the sacral slope; this is not true for any other part of the spine.^{1,7,8} Therefore, stabilization here should be stronger than that applied to the other spinal segments.^{1,2,6,9} Throughout the entire

Discussion

Pathologies in the combined region of the

spine, the lumbosacral region exhibits maximum flexion and extension motion with an average of 17 degrees in the sagittal plane; however, while the rotation measures 1 degree, lateral bending does not exceed 3 degrees.⁹ The L5-S1 lumbar disc causing the lordosis is the most anterior curved disk in the entire spine and is the place with the most load due to the distribution of the power vectors in human beings, who move on two legs. The effect of high-level shear forces at this angular structure is excessive.⁷⁻⁹

Except for trauma patients, early diagnosed L5 neoplasm can be treated with radiotherapy and lumbosacral orthosis; On the other hand, the deterioration of spinal biomechanics and emergent instability make the surgery inevitable as long as the patient's general health status permits. However, using the anterior approach for the lumbosacral junction is difficult because of the anatomical features of the lumbosacral junction.¹ Such surgeries have high morbidity rates because of the vascular and neural anatomy and require the appropriate surgical experience. The aorta and vena cava bifurcate anteriorly to the L4 and S1 vertebrae; toward the middle of the spine, the internal iliac artery tends toward bifurcation, and the vein extends from the front of L5 toward the lateral sacral wings. In addition, the ventral bodies of L4 and L5 form the lumbosacral trunk and become sacral nerves in between the iliac vein and the sacroiliac joint. The sigmoid colon loses its meso in front of the sacrum and becomes still at the level of L3.

The center line of the body weight of erect people is toward the anterior of the vertebral column. The axial load on the body when vertical is the result of a combination of spinal axial compression and bending movement.¹⁰ The anterior column is the load-carrying portion of the spine and absorbs approximately 80% of the axial load.^{4,6,10,11} Because of angulation to the horizontal line, the effect of shear force on L5 vertebrae tends to prompt deformation compared with other vertebrae. Neoplasm of the spine destroys the structures of the anterior and/or posterior column and thus tends to cause early kyphotic deformities.⁴ Therefore, neoplasm or trauma of L5 vertebrae requires more rigid stabilization to resist forces that could disturb it. Building strong spinal stability requires powerful anterior and posterior construction.^{1,3,4}

In malignant cases the involvement of L5 vertebra significantly deteriorate the spine stabilization. , stabilization of the spine. If the pathology affects only the L5 vertebra, a circumferential stabilization containing both the vertebral and dorsal columns should be applied after a total L5 vertebrectomy to restore spine stability in the region with the greatest load. In cases of L5 pathology, short-segment lumbopelvic stabilization of the L4-S1 region is

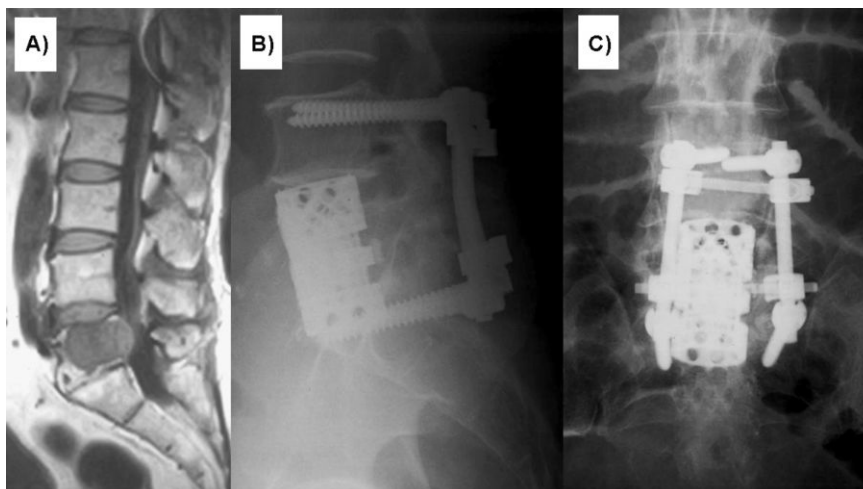


Figure 2. A 68-year-old male patient with a chordoma in his L5 vertebra (patient #5). A) Preoperative sagittal T1-weighted MR imaging of the patient; B) Lateral radiographic view after the operation; C) Antero-posterior radiographic view after the operation.

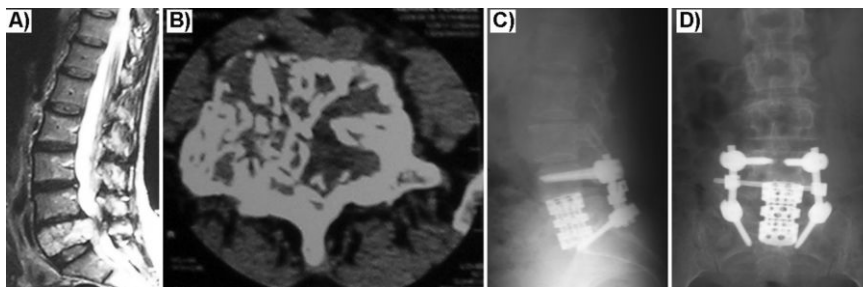


Figure 3. A 42-year-old female patient who had a hemangioma in her L5 vertebra (patient #7). A) Preoperative sagittal T2-weighted MR imaging of the patient; B) Preoperative axial CT imaging on the tumoral line of the L5 vertebra; C) Lateral radiographic view after the operation; D) Antero-posterior radiographic view after the operation.

sufficient.^{3,4} If L5 vertebral bone quality is insufficient or if pathology affects the L4 vertebra and/or sacrum together with the L5 vertebra, long segment stabilization with sacral attachments is needed to prevent high cantilever forces on the S1 screws that would cause the screws to pull out.^{2,12} The patients presented in this article had only L5 pathology; thus, we only performed the short-level technique but achieved 360-degree stabilization in all cases.

Harms and Tabasso reported that to regain spinal stabilization, anterior reconstruction aims to distract, while posterior stabilization devices apply compression.⁴ The authors also reported that in determining stabilization and reconstruction, the anterior and posterior elements must be well analyzed. Those that will contribute to the most appropriate reconstruction and stabilization should be selected.

Because of the impairment of anatomical and biomechanical properties, surgery on the neoplastic spine usually requires a combined

anterior and posterior approach. The anterior approach is first attempted to decompress the cord, excise the tumor anteriorly, restore the anterior support, and correct the kyphosis. Then, a posterior approach is performed for posterior decompression and tumor excision and to restore the physiological posterior tension band.⁴ In secondary malignant tumors of the spine, deformity (mostly kyphosis) is common because of the collapse of the invaded vertebral body.¹³ Anterior support is achieved with a bone graft in a vertebral fracture, whereas it is achieved using a titanium cylinder cage in secondary malignant tumors of the spine due to the patient's often limited life expectancy.⁴ Thus, titanium cages ensure immediate stability without requiring bony fusion. As presented in this study, the authors performed a bone graft in the vertebral fracture patient and titanium expandable cages in the secondary malignant tumor patients after L5 vertebrectomy according to the surgical technique of Harms and Tabasso.

Conclusion

The lumbosacral region presents significant stabilization problems because of sacral slope. L5 vertebrectomy is a treatment option to be used when conservative treatments prove to be useless in patients with severe pain in the lumbosacral junction and when pathologies lead to the loss of function and instability in that region. In our opinion, if the lesion involves only the L5 vertebra, anterior cage-filled bone cement or bone grafts should be performed as dictated by the pathology and posterior transpedicular instrumentation. If the lesion involves the L4 vertebra or sacrum and the L5 vertebra, instrumentation should be extended to cover other segments with sacral attachments. The present cases involved only the L5 vertebra and treatment with short-segment stabilization covering the anterior and posterior columns. Familiarity with the anatomy of this area and appropriate surgical experience are the most important factors in reducing surgical morbidity and increasing surgical success.

References

1. Bridwell KH. Management of Tumors at the lumbosacral junction. In: Margulies JY, Floman Y, Farcy J-PC, Neuwirth MG, eds. *Lumbosacral and Spinopelvic Fixation*. Philadelphia: Lippincott-Raven; 1996. p.109-122.
2. Benzel EC. *Biomechanics of spine stabilization. Regional nuances*. New York: Thieme (Copyright by AANS); 2001. p. 318-9.
3. Gurwitz GS, Dawson JM, McNamara MJ, et al. Biomechanical analysis of three surgical approaches for lumbar burst fractures using short-segment instrumentation. *Spine* 1993;18:977-82.
4. Harms J, Tabasso G. Instrumented spinal surgery. Principles and technique. Stuttgart: Thieme; 1999. pp 16-8, 95.
5. Shufflebarger HL, Grimm JO, Bui V, Thomson JD. Anterior and posterior spinal fusion. Staged versus same day surgery. *Spine* 1991;16:930-3.
6. Bergmark A. Stability of the lumbar spine: a study of mechanical engineering. *Acta Orthop Scand* 1989;230:1-54.
7. Dietrich M, Kurowski P. The importance of mechanical factors in the etiology of spondylolysis. A model analysis of loads and stresses in human lumbar spine. *Spine* 1985;10:532-42.
8. Farfan HF, Kirkaldy-Willis WH. The present status of spinal fusion in the treatment of lumbar intervertebral joint disorders. *Clin Orthop* 1981;158:198-214.
9. Stovall DO Jr, Goodrich JA, Lundy D, et al. Sacral fixation technique in lumbosacral fusion. *Spine* 1997;22:32-7.
10. Holdsworth FW, Hardy A. Early treatment of paraplegia from fractures of the thoracolumbar spine. *J Bone Joint Surg Br* 1953;35:540-50.
11. Klekamp J, Samii M. *Surgery of spinal tumors. Anatomy, spinal biomechanics*. Heidelberg: Springer; 2007.
12. Dalbayrak S, Yilmaz M, Kaner T, et al. Lumbosacral stabilization using iliac wings: a new surgical technique. *Spine* 2011;36:e673-7.
13. DeWald RL, Bridwell KH, Prodromas C, Rodts MF. Reconstructive spinal surgery as palliation for metastatic malignancies of the spine. *Spine* 1985;10:21-6.