

# Importance of effusion of blood under the dura mater in forensic medicine

## A STROBE – compliant retrospective study

Sigitas Chmieliauskas, PhD<sup>a,b,\*</sup>, Joginte Saule Anuzyte, MS<sup>a</sup>, Julita Liucvaikyte, MS<sup>a</sup>, Sigitas Laima, PhD<sup>a,b</sup>, Eleonora Jurolaica, MD<sup>b</sup>, Saulius Rocka, PhD<sup>c</sup>, Dmitrij Fomin, PhD<sup>a,b</sup>, Jurgita Stasiuniene, PhD<sup>a</sup>, Algimantas Jasulaitis, PhD<sup>a</sup>

### Abstract

Subdural hemorrhage is commonly associated with mechanical brain injury and has a correspondingly high mortality rate. Subdural hematomas may immediately provoke symptoms or may be initially asymptomatic, with further symptoms evolving rapidly and fatally.

The data regarding forensic autopsy of victims were obtained from The State Forensic Medicine Service of Lithuania between the years 2013 and 2016. A retrospective study was performed including 110 patients, whose cause of death was subdural hemorrhage. 95% confidence intervals were calculated.

It was calculated, that in cases of sudden death, after subdural hemorrhage was diagnosed, a higher concentration of ethyl alcohol in blood (mean  $2.22 \pm 1.3\%$ ) demanded a smaller amount of blood under the dura mater (mean  $81.6 \pm 60.5$ g) in order for the patient to die. It was also noted that hospitalized patients with subdural hemorrhage had a smaller concentration of blood ethyl alcohol (mean  $1.33 \pm 1\%$ ) and a larger amount of blood under the dura (mean  $135.6 \pm 82.9$ g).

Due to the toxic effect of ethyl alcohol, even a small amount ( $81.6 \pm 60.5$ g) of blood under the dura mater can determine a sudden death.

**Abbreviations:** GCS = Glasgow coma scale, PMNs = polymorphonuclears, RBCs = red blood cells, SDH = subdural hemorrhage.

**Keywords:** blunt trauma, brain injury, forensic medicine, histology, intoxication, subdural hematoma

## 1. Introduction

Brain injury can cause morphologic changes of brain's anatomical structures which lead to symptoms and outcomes.<sup>[1]</sup> More than 50% of all death cases encountered during forensic autopsy are associated with brain trauma. One of the most common complications of blunt head trauma is subdural hemorrhage (SDH). SDH is a result of bleeding from the veins between the dura mater and the arachnoid of the brain which occurs in about 30% of cases.<sup>[2,3]</sup> Arterial bleeding is more rapid, thus resulting in evident clinical symptoms and fatal outcomes.

The SDH may cause an increase of the intracranial pressure, leading to secondary brain tissue injury. Elderly patients and alcoholics are at risk of developing SDH, due to cerebral atrophy, anticoagulant treatment and a higher risk of falling. SDH may be misdiagnosed because of the absence of fractures, intracerebral hemorrhage, or early neurologic symptoms.<sup>[1–4]</sup>

The SDH are divided into acute, subacute, and chronic, depending on the bleeding rate and the amount of time elapsed since the blunt head trauma occurred. SDH can occur bilaterally or unilaterally, can be isolated or in combination with skull fractures, with or without cortical hemorrhage and clinical symptoms.<sup>[1–4]</sup>

There are different causes of SDH. The main cause of SDH is cortical hemorrhage (contusion injury) evident in 60% to 70% of cases. Less common causes are tearing of the bridging vein (2.5–20%), arterial injury (cortical part of the middle cerebral artery) (2.5–10%) and sinusoidal injury (4–9%).<sup>[2,4]</sup> In some cases, the source of SDH cannot be found, because early clinical symptoms are absent or a large amount of time has passed since the head trauma.

Depending on the source of bleeding, localization of the brain and bleeding rate, different mechanisms of pathogenesis are distinguished: recurrent “spontaneous” SDH, contusion-induced SDH, cortical lacerations associated with fissures, linear fractures, or depressed fractures of the skull can cause SDH and acceleration/rotational mechanisms.<sup>[1–4]</sup>

In forensic pathology, it is important to understand, which amount of SDH is clinically relevant to cause a sudden death. Furthermore, it is important to assess morphologic features of brain injury that lead to sudden death when patients are not hospitalized and do not receive neurosurgeon's examination.

Editor: Bernhard Schaller.

The authors have no conflicts of interest to disclose.

<sup>a</sup> Department of Pathology, Forensic Medicine and Pharmacology, Institute of Biomedical Sciences of the Faculty of Medicine of Vilnius University, <sup>b</sup> State Forensic Medicine Service, <sup>c</sup> Department of Neurology and Neurosurgery, Vilnius University, Vilnius, Lithuania.

\* Correspondence: Sigitas Chmieliauskas, Department of Pathology, Forensic Medicine and Pharmacology, Institute of Biomedical Sciences of the Faculty of Medicine of Vilnius University, Vilnius, M K Ciurlionio Str 21/27, Lithuania (e-mail: sigitas.chmieliauskas@mf.vu.lt).

Copyright © 2018 the Author(s). Published by Wolters Kluwer Health, Inc. This is an open access article distributed under the terms of the Creative Commons Attribution-Non Commercial License 4.0 (CCBY-NC), where it is permissible to download, share, remix, transform, and buildup the work provided it is properly cited. The work cannot be used commercially without permission from the journal.

Medicine (2018) 97:39(e12567)

Received: 29 December 2017 / Accepted: 30 August 2018

<http://dx.doi.org/10.1097/MD.00000000000012567>

## 2. Methods

### 2.1. Study design and data source

A retrospective study was performed including 110 patients, whose cause of death was a blunt head trauma with SDH. This research was designed as a retrospective cohort study and written in accordance to the Strengthening the Reporting of Observation studies in Epidemiology (STROBE) guideline. This study was approved by the Ethics Committee of Vilnius regional biomedical research. The patient and his representatives signed an informed consent. The data regarding forensic autopsy of victims were obtained from The State Forensic Medicine Service of Lithuania between the years 2013 and 2016. We acquired the data from Lithuanian health database ([www.esveikata.lt](http://www.esveikata.lt)) aiming at patients, whose cause of death was a blunt head trauma with SDH and alcohol intoxication. This Lithuanian health data set includes demographic information of patients, diagnosis, as well as information regarding the cause of death.

### 2.2. Identification of cases

Totally 110 patients were included. In 56 of cases, victims of head trauma died suddenly without receiving any medical treatment, while in 54 of cases patients were hospitalized. Patients were identified by International Classification of Diseases. In 71 of cases, victims were sober, and 39 were intoxicated by ethanol. The criteria for inclusion were cases of blunt head traumas with SDH, cases with/without linear fractures of the cranial vault, cases of blunt head trauma accompanied by alcohol intoxication (0.15–3.84%), cases of blunt head trauma with/without contusion, cases of blunt head trauma with/without bruising of the soft tissues. The cases of blunt head trauma with fractures of the basis of the skull or with multiple fracture fragments were excluded from the analysis. Victims that received hospitalization were evaluated using the Glasgow coma scale (GCS), ranging from 3 to 15. In each case, a close attention was paid to the amount of the effused blood under the dura mater. The circumstances of the head trauma were determined as accidental or as homicide. Toxicology tests for alcohol were performed routinely in every case. Information about possible crime place, probable time of death, and the presumable death mechanism was provided from the law enforcement agencies. Those cases admitted to the department of neurosurgery confirmed the history of head trauma, the exact manner how the trauma occurred and the exact time of the injury. The severity of the brain injury was also described in the hospital record.

### 2.3. Limitations

This study has certain limitations, which are described below. Firstly, the study subject was derived from Lithuania's population and the obtained parameters could not represent the state of the whole population worldwide. Secondly, the data selected for this analysis had a limited number of female patients. Thirdly, the selected patients were mostly middle-aged and older. The pediatric age characteristics were not obtained.

### 2.4. Statistical analysis

The collected data were processed using R software. To determine whether data were normally distributed, the Shapiro–Wilk test was used. Chi-squared test and Fisher exact test was performed to compare groups. Spearman correlation

coefficients were assessed. A weak correlation was defined as  $r$ -values  $< 0.39$ ; a moderate correlation with  $r$ -values from 0.40 to 0.69; and a strong correlation with  $r$ -values  $> 0.70$ . Additionally, 95% confidence intervals were calculated. Differences with  $P$ -values  $< .05$  were considered significant.

### 2.5. Histologic methods

To evaluate the time of injury, histologic examination of subdural hematomas was performed. Sections were cut and prepared for routine light microscopy. Histomorphologic features of the dura and the clot were examined using hematoxylin and eosin stain, Pearls' Prussian Blue reaction, to demonstrate ferric iron, and Masson trichrome for the detection of collagen fibers.

The hematoxylin and eosin stain consists of several procedures. The sections are hydrated with absolute alcohol within 7 minutes, following a further distillation with 90%, 70% ethanol, and distilled water for 7 minutes. The hematoxylin stain is applied for 6 minutes, following a continuous wash in running water for 5 minutes, cleaning with 96% ethanol for 1 minute. Secondly eosin and floxin solution is applied for 5 minutes. Finally, a quick dehydration with 70%, 90%, and absolute alcohol is being performed for 6 minutes. The nucleus is evident in blue-violet color; cytoplasm and matrix in different pink tones.

## 3. Results

The mean age of patients ( $n=110$ ) was  $55.1 \pm 17.2$  years, median 54 years. About 70.9% were men, and 29.1% were women. No statistically significant difference was found between mean male and female age ( $P < .05$ ).

In 51% of cases, victims of head trauma died suddenly without receiving any medical treatment, while in 49% of cases, patients were hospitalized. No statistically significant difference was found between men and women in these groups ( $P < .05$ ). However, a statistically significant difference was established while comparing the mean age of individuals that died suddenly ( $48.2 \pm 17$ ) and those who were hospitalized ( $60.1 \pm 16.8$ ) ( $P = .003$ ).

The majority (64.5%) of victims was sober. Mean concentration of ethyl alcohol in blood of those who were drunk was  $1.85 \pm 1.1\%$ , with maximum concentration at 3.84%. Statistically significant difference was found while comparing blood alcohol concentration in cases of sudden deaths  $2.22 \pm 1.3\%$  and hospitalized patients  $1.33 \pm 1\%$  ( $P < .05$ ). Thus meaning that after the blunt head trauma occurred, those who were less intoxicated by ethanol survived for a longer period.

Most common cause of head trauma was falling (60.9%). Other causes as blow on the head with blunt object (12.7%) and falling from a height (10.9%) occurred more rarely. In 57.4% of cases, skull fractures were identified. In 42.6% of cases, no skull fractures were found. In 83.6% of cases, focal cerebral contusions were visible. In 63.6% of cases, bleeding under the pia mater was determined. About 92% of patients that were hospitalized had symptoms of brain edema.

Effusion of blood under the dura mater was identified in 80% of cases. Mean amount of effused blood in grams was  $104.0 \pm 71.4$ g, with the maximum amount at 295g and a minimum amount at 10g (Fig. 1). In cases when sudden death occurred the mean amount of effused blood under the dura mater was  $81.6 \pm 60.5$ g, in cases with hospitalized patients, the mean amount of effused blood was  $135.6 \pm 82.9$ g ( $P < .05$ ). Unilateral SDH was found in 98% of cases and only 2% of cases had bilateral SDH.

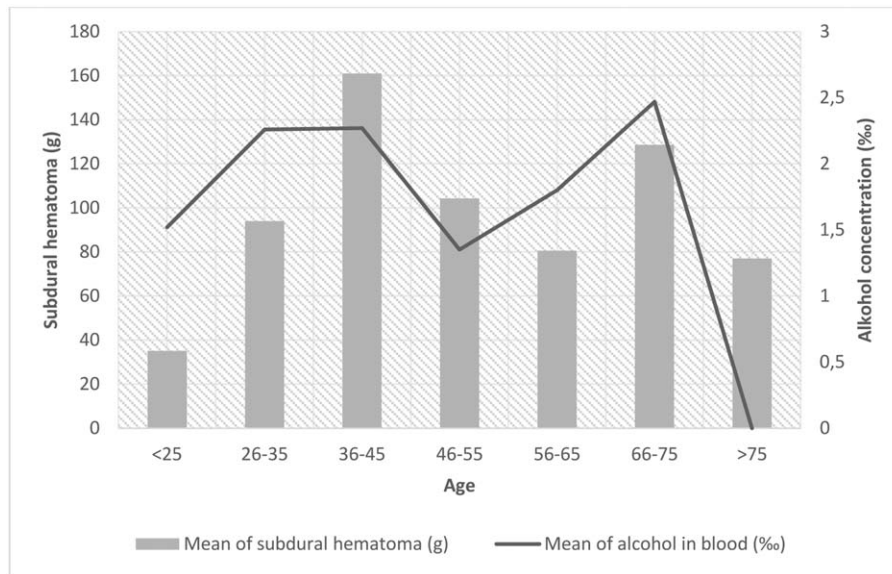


Figure 1. Subdural hematoma and alcohol concentration in blood.

The mean consciousness level of patients that were hospitalized was  $6.13 \pm 3.7$  scores on the GCS. Statistically significant negative correlation was observed between amount of effused blood under the dura mater in grams and level of consciousness in scores on the GCS ( $r = -0.45, P = .05$ ). A more severe condition scoring less on the GCS was established, when larger amount of effused blood was under the dura mater (Fig. 2).

Patients who were hospitalized after injury survived for average  $6.6 \pm 5.5$  days (Fig. 3). Statistically significant correlation was observed between duration of hospitalization and level of consciousness in GCS scores ( $r = 0.76, P = .04$ ). Hospitalized patients who scored less on the GCS survived for a shorter period of time.

Negative correlation was estimated between level of consciousness (in GCS scores) and blood alcohol concentration ( $r = -0.62,$

$P > .05$ ) (Fig. 4). Weak negative correlation between duration of hospitalization and blood alcohol concentration was observed ( $r = -0.33, P > .05$ ).

In 14.3% of cases of sudden death, when patients did not receive any medical help death occurred within 1 to 3 hours after the injury. In 8.9% of cases, death occurred between 3 and 6 hours after injury and in 30.4% of cases death occurred within 6 to 12 hours. These results were established based on the autopsy results.

#### 4. Discussion

According to the data from The State Forensic Medicine Service, in Lithuania, injuries with blunt objects are the 3rd (16%) most common cause of death from the unnatural causes, with a

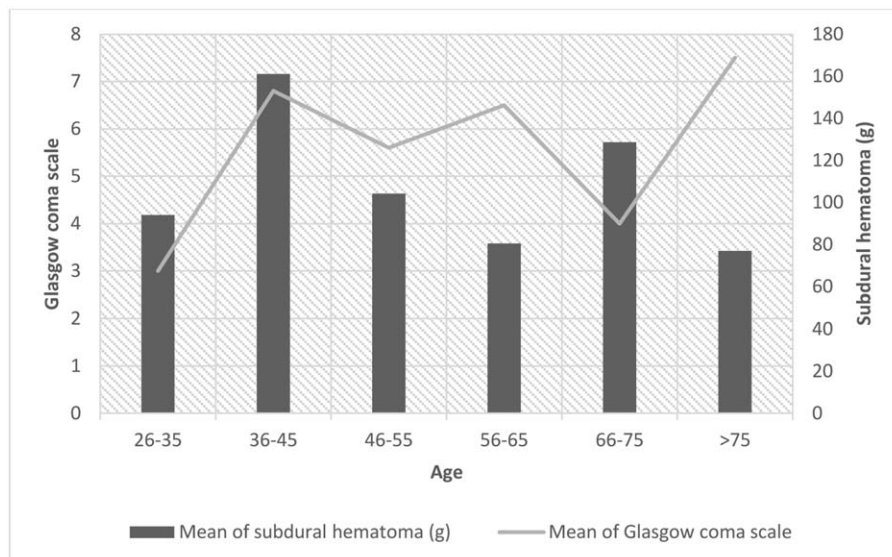


Figure 2. Subdural hematoma and Glasgow coma scale.

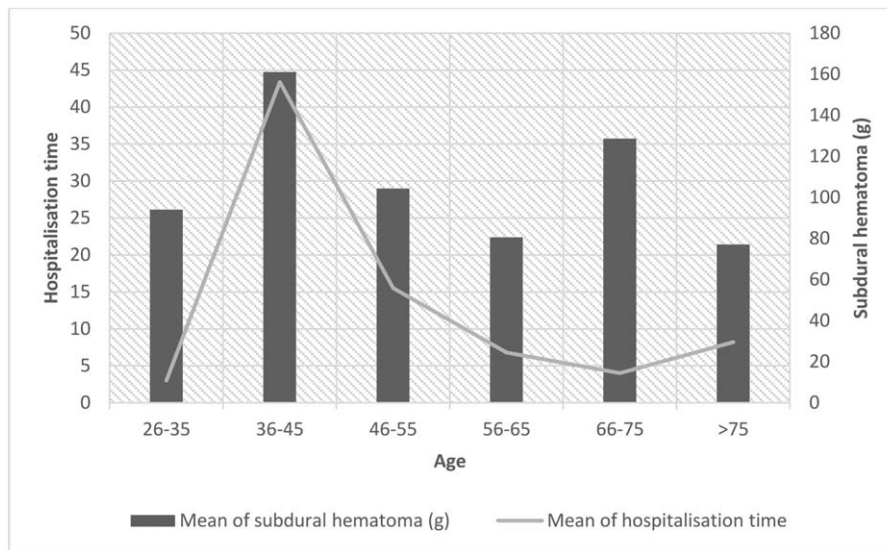


Figure 3. Subdural hematoma and hospitalization time.

male-to-female ratio of 2.44:1. Asphyxiation and intoxication are the most common causes of death.

Head injuries are the main cause of death and account for one-third to one-half of traumatic deaths. Head injuries may be divided into primary and secondary. Primary injury relates directly to the trauma; secondary injury refers to the complications: brain edema, compression of the brain, secondary hemorrhage, especially in the brain stem, and brain herniation.<sup>[4]</sup>

The SDH is the most common type of all traumatic intracranial mass lesions. Clinical symptoms of the subdural hematomas depend on their volume and compensatory mechanisms of the brain, and may be symptomatic or asymptomatic. In these cases, the symptoms may evolve in <72 hours and may be fatal. During adulthood SDH may be caused not only by the blunt head trauma but also of no reason when any traumatic event is present.<sup>[1]</sup>

It is very difficult to make forensic interpretations of the SDH age because of the different mechanism of the SDH, especially in the elderly. This may lead to incorrect forensic interpretations, detriment of the legal system, and accusation of nongUILTY individuals.<sup>[1,5]</sup>

Spontaneous subdural hematomas do occur, especially during infancy, under the influence of inherited and acquired coagulation disorders, during the process of birth, various inherited metabolism disorders, vascular anomalies, and within the range of shaken baby syndrome.<sup>[1,6-8]</sup>

Acute SDH, which is unilateral most of the time is found in serious head trauma cases (most have GCSs of 3-5) carrying a greater mortality rate in patients over the age 50.<sup>[1]</sup>

Fresh coagulated blood between the arachnoid mater and the dura mater is characteristic feature of acute SDH and can be

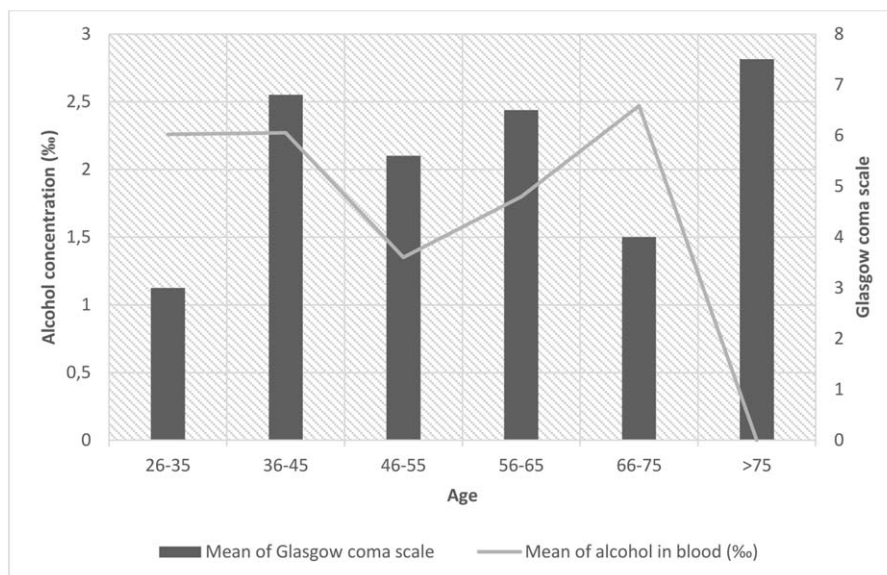


Figure 4. Glasgow coma scale and alcohol concentration in blood.

diagnosed by clinicians or pathologists during the first 3 days following the traumatic event.<sup>[2]</sup> The different localization of the hemosiderin-containing macrophages in the brain mater layers is an indicator of several bleeding episodes.<sup>[2]</sup>

The subacute phase of SDH begins 3 to 7 days after acute injury, but <3 weeks to the appearance of clinical symptoms.<sup>[2]</sup> Coagulation of the effused blood begins with the coagulation cascade. Firstly, it occurs with signs of leukocyte migration, ingestion of erythrocytes, and/or fagocytolysis as demonstrated by Fe-containing macrophages, as well as the formation of granulation tissue, collagenous fibers, macrophages, and endothelial cells.<sup>[2]</sup> A formed fibrin network holds the hematoma's components together.<sup>[2]</sup>

Chronic SDH develops after more than 3 weeks with clinical symptoms evolving very slowly. The morphology varies with accordance to survival time. In the chronic phase, cellular elements are often disintegrated, and the serous fluid remains in

the subdural space. The SDH is typically encapsulated by a neomembrane.<sup>[2,9-13]</sup>

The most frequent location of SDH is at or near the vertex of the brain near the midline, often reaching the lateral portion of the cerebral hemispheres into the Sylvian region, with considerably fewer hematomas occurring in the far anterior, posterior, inferior, midline, and posterior cerebral areas or posterior fossa. Acute posterior fossa hematomas are especially dangerous because of the limited mass effect.<sup>[1,14]</sup>

Forensic issues arise when interpretations are being established, regarding the age and speed of evolution of lesion, the kind of trauma, that could have produced it, the causal relationship to the death, the relation to symptoms observed, and the ability to diagnose the lesion by clinicians.<sup>[10,15-17]</sup> These issues involve determination of the manner of death as well as implications to possible criminal or civil legal actions in relation to the case.<sup>[17-19]</sup> During neurosurgical operation and autopsy, all findings should

**Table 1**  
**Macroscopic and histologic aging of subdural hematomas.**

Survival interval	Microscopic analysis of the subdural hematoma	Dural side	Arachnoid side	Macroscopic view of the subdural hematoma
<1 h	Intact spherical RBCs, no PMN infiltration	Thin layer of fibrin	Thin layer of fibrin, single leukocytes	Liquid blood
1-4 h	Intact RBCs, insubstantial PMN infiltration	Thin layer of fibrin, leukocytes	Thin layer of fibrin, single leukocytes	Several shiny, friable, fragile, not attached to the dura mater blood clots and liquid blood in a ratio of 1:1
4-12 h	Fagocytolysis of RBCs, loss of RBC's sharp contour and variability of staining, PMN infiltration, several macrophages	Thin layer of fibrin, leukocytes	Thin layer of fibrin, leukocytes	Organized shiny, friable, fragile, not attached to the dura mater blood clots and traces of liquid blood
12-24 h	Fagocytolysis of RBCs, loss of RBC's sharp contour and variability of staining, increased infiltration of PMN and macrophages	Early fibroblastic activity, leukocytes	Thin layer of fibrin, leukocytes	Solid, shiny, friable, fragile, not attached to the dura mater blood clots
24-48 h	Loss of RBC's sharp contour and variability of staining, substantial infiltration of PMN and macrophages, insubstantial hemosiderin infiltration	Early fibroblastic activity, leukocytes	Thin layer of fibrin, leukocytes	Solid, shiny blood clots sustaining their form, not firmly attached and easily removed from the dura mater
2-4 days	Hemoglobin loss of RBCs, PMN infiltration changed by infiltration of macrophages and fibroblasts, thin layer of fibrin, deposition of hemosiderin	2-4 layers of fibroblasts, leukocytes	Thin layer of fibrin, leukocytes	Solid, mat blood clots sustaining their form which are attached to the dura mater
5-10 d	Loss of RBC sharp contour and variability of staining, hollow RBC, neovascularization, substantial infiltration of macrophages, formation of neomembrane, intensive deposition of fibrin, formation of early collagen, hemosiderin-containing macrophages	12-14 layers of fibroblasts; neomembrane visible grossly when clot scraped away	Thin layer of fibrin, siderophages are visible on arachnoid side	Mat, brownish blood clots attached to the dura mater
11-15 d	Fagocytolysis of RBCs, active organization of clot with substantial depositions of fibrin and collagen, clot divided into sections, neovascularization, macrophages with hematoidin, proliferation of capillaries	Fibroblasts migrate around the edges of the clot, the membrane is as thick as the dura mater	Variably thin, earliest complete neomembrane; clot may be completely enveloped Hemosiderin-containing macrophages	Mat, tawny yellow blood clots which are attached to the dura mater. Capsule can be seen
16-20 d	Active organization of the clot with substantial depositions of fibrin and collagen, clot divided into sections, neovascularization, macrophages with hematoidin, proliferation of capillaries	The membrane is up to 1/2 of dural thickness	The membrane is up to 1/2 of dural thickness, hemosiderin-containing macrophages in the membrane	Tawny yellow blood clots with a mat capsule attached to the dura mater
21-30 d	Clot completely liquefied	Dura-like membrane, hemosiderin-containing macrophages in the membrane	Dura-like membrane	Mat, thin, thigh, tawny yellow capsule
1-3 mo	Clot completely liquefied; larger vessels permeate	Hyalinization of membranes, the collagen component is dominating over cells	Hyalinization of membranes, the collagen component is dominating over cells nearly thickness of dura	Matted, liquefied, tawny yellow capsule
3-6 mo	No original RBCs and only focal rebleeding	Hyalinized neomembrane	Hyalinized neomembrane	Thin, mousy brown capsule

PMN = polymorphonuclears, RBC = red blood cells.

be carefully documented.<sup>[20–27]</sup> A thorough description of the SDH, the volume of the hematoma, internal and external lesions is required. A sketch and photographs also are very useful. It is recommended to take several histologic samplings of the subdural hematoma with or without dura mater and any other visible lesions of the dura to collect all necessary forensic evidences.<sup>[1]</sup>

According to the data from The State Forensic Medicine Service, sudden death is caused by a smaller amount of SDH when accompanied by the toxic effect of ethyl alcohol and polymorphous brain injury.

When estimating the time of injury forensic pathologist must refer to both macroscopic and microscopic assessment of pathomorphologic changes (Table 1). The time course of SDHs is characterized by blood cell reaction, the process of fibroblast proliferation and collagen fiber synthesis.<sup>[1,2,4,28–31]</sup>

Furthermore, the understanding of the trigeminocardiac reflex is crucial for pathophysiologic explanation of death mechanism. The trigeminocardiac reflex is a well-known brainstem reflex that was first described in skull base surgery and neurosurgery by the senior author. The trigeminocardiac reflex is defined as the sudden onset of parasympathetic dysrhythmia, sympathetic hypotension, apnea, or gastric hypermotility during stimulation of any of the sensory branches of the trigeminal nerve. Intracranial blood clots distend the dura mater suddenly and aggressively and thus stimulate the trigeminal dural afferents postoperatively by initiating trigeminocardiac reflex. Stimulation of any of the trigeminal branches or nerve endings activates the afferent signals to the Gasserian ganglion and then to the sensory nucleus of the trigeminal nerve within the vicinity of the floor of the 4th ventricle. Small internuncial nerve fibers of the reticular formation connect the afferent to the efferent premotor neurons located primarily in the nucleus ambiguus and the dorsal motor nucleus of the vagus. The reflex pathway activates cardioinhibitory parasympathetic vagal neurons, thus completing the reflex arc.<sup>[32,33]</sup>

## 5. Conclusion

Totally 110 patients were included. In 56 of cases, victims of head trauma died suddenly without receiving any medical treatment, while in 54 of cases, patients were hospitalized. Patients were identified by International Classification of Diseases. In 71 of cases, victims were sober, and 39 were intoxicated by ethanol. During forensic autopsy when the cause of death was a blunt head trauma, several variables were estimated. The mean age was  $48.2 \pm 17$  years; the mean blood ethyl alcohol concentration was  $2.22 \pm 1.3\%$ , with intoxication ranging from a minimum of 0.16 to a maximum of 3.84%. The mean amount of blood under the dura matter was  $81.6 \pm 60.5$  g. The estimated mean age of the hospitalized individuals was  $60.1 \pm 16.8$  years, with a mean blood alcohol concentration of  $1.33 \pm 1\%$  (range of intoxication 0.15–2.78%) and a mean amount of blood under the dura mater being  $135.6 \pm 82.9$  g. The mean consciousness level was  $6.13 \pm 3.7$  scores on the GCS. Due to the toxic effect of ethyl alcohol, even a small amount of blood under the dura matter can determine a sudden death. Brain compression symptoms may be caused by smaller amount of effused blood in the presence of polymorphous brain injuries. In 57.4% of cases, skull fractures were identified. In 83.6% of cases, focal cerebral contusions were found. In 63.6% of cases, bleeding under the pia mater was detected. About 92% of patients had symptoms of brain edema.

## Author contributions

**Investigation:** Sigita Chmieliauskas, Joginte Saule Anuzyte, Julita Liucvaikyte, Sigita Laima, Eleonora Jurolaic, Saulius Rocka, Dmitrij Fomin.

**Methodology:** Jurgita Stasiuniene.

**Supervision:** Jurgita Stasiuniene, Algimantas Jasulaitis. Sigita Chmieliauskas orcid: 0000-0001-9104-9835

## References

- Leestma JE, Leestma JE, Thibault KL. *Forensic Neuropathology*. Chapter 6. Physical injury to the nervous system 2nd ed. Broken Sound Parkway, NW: CRC Press; 2008;442–66.
- Oehmichen M, Auer RN, König HG, et al. Chapter 7. Injuries of the brain's coverings. *Forensic Neuropathology and Neurology* Springer, Berlin:2006;126–40.
- Black M, Graham DI. Sudden unexplained death in adults caused by intracranial pathology. *J Clin Pathol* 2002;55:44–50.
- Haberland C. Chapter 12. Traumatic injuries of the central nervous system. *Clinical Neuropathology: Text and Color Atlas Demos*, New York:2007;126–270.
- Yamamura H, Morioka T, Yamamoto T, et al. Head computed tomographic measurement as a predictor of outcome in patients with subdural hematoma with cerebral edema. *Scand J Trauma Resusc Emerg Med* 2016;24:83.
- Biesbroek JM, van der Sprenkel JW, Algra A, et al. Prognosis of acute subdural haematoma from intracranial aneurysm rupture. *J Neurol Neurosurg Psychiatry* 2013;84:254–7.
- Barrios L, Clément R, Visseaux G, et al. A case of atypical chronic subdural hematoma: a spontaneous rupture of dural lymphoma nodule. *J Forensic Leg Med* 2014;22:145–7.
- Louhab N, Adali N, Laghari M, et al. Misdiagnosed spontaneous intracranial hypotension complicated by subdural hematoma following lumbar puncture. *Int J Gen Med* 2014;7:71–3.
- Gandhoke GS, Kaif M, Choi L, et al. Histopathological features of the outer membrane of chronic subdural hematoma and correlation with clinical and radiological features. *J Clin Neurosci* 2013;20:1398–401.
- Arán-Echabe E, Frieiro-Dantas C, Prieto-González Á. Chronic calcified subdural haematoma: armoured brain. *Rev Neurol* 2014;58:420–1.
- Tosaka M, Sakamoto K, Watanabe S, et al. Critical classification of craniostomy for chronic subdural hematoma; safer technique for hematoma aspiration. *Neurol Med Chir* 2013;53:273–8.
- Wittschieber D, Karger B, Niederstadt T, et al. Subdural hygromas in abusive head trauma: pathogenesis, diagnosis, and forensic implications. *AJNR Am J Neuroradiol* 2015;36:432–9.
- Almenawer SA, Farrokhhyar F, Hong C, et al. Chronic subdural hematoma management: a systematic review and meta-analysis of 34,829 patients. *Ann Surg* 2014;259:449–57.
- Lee J, Park JH. Clinical characteristics of bilateral versus unilateral chronic subdural hematoma. *Korean J Neurotrauma* 2014;10:49–54.
- Postema FA, Sieswerda-Hoogendoorn T, Majoie CB, et al. Age determination of subdural hematomas: survey among radiologists. *Emerg Radiol* 2014;21:349–58.
- Sieswerda-Hoogendoorn T, Postema FA, Verbaan D, et al. Age determination of subdural hematomas with CT and MRI: a systematic review. *Eur J Radiol* 2014;83:1257–68.
- Weigel R, Hohenstein A, Schilling L. Vascular endothelial growth factor concentration in chronic subdural hematoma fluid is related to computed tomography appearance and exudation rate. *J Neurotrauma* 2014;31:670–3.
- Sano R, Hirasawa S, Awata S, et al. Use of postmortem computed tomography to reveal acute subdural hematoma in a severely decomposed body with advanced skeletonization. *Leg Med (Tokyo)* 2013;15:32–4.
- Lynch MJ, Woodford NW. The role of post-mortem imaging in preliminary examinations under the Coroners Act 2008 (Vic): a forensic pathologist's perspective. *J Law Med* 2014;21:774–9.
- Orlando A, Levy AS, Rubin BA, et al. Isolated subdural hematomas in mild traumatic brain injury. Part 1: the association between radiographic characteristics and neurosurgical intervention. *J Neurosurg* 2018;15:1–0.
- Orlando A, Levy AS, Rubin BA, et al. Isolated subdural hematomas in mild traumatic brain injury. Part 2: a preliminary clinical decision support tool for neurosurgical intervention. *J Neurosurg* 2018;15:1–8.
- Wang J, Han F, Zhao Q, et al. Clinicopathological characteristics of traumatic head injury in juvenile, middle-aged and elderly individuals. *Med Sci Monit* 2018;24:3256–64.

- [23] Karibe H, Hayashi T, Hirano T, et al. Surgical management of traumatic acute subdural hematoma in adults: a review. *Neurol Med Chir (Tokyo)* 2014;54:887–94.
- [24] Miller JD, Nader R. Acute subdural hematoma from bridging vein rupture: a potential mechanism for growth. *J Neurosurg* 2014;120:1378–84.
- [25] De Vloot P, Nijs S, Verelst S, et al. Prehospital and intrahospital temporal intervals in patients requiring emergent trauma craniotomy. A 6-year observational study in a level 1 trauma center. *World Neurosurg* 2018;114:e546–58.
- [26] Franko LR, Sheehan KM, Roark CD, et al. A propensity score analysis of the impact of surgical intervention on unexpected 30-day readmission following admission for subdural hematoma. *J Neurosurg* 2017;22:1–9.
- [27] Prasad GL, Anmol N, Menon GR. Outcome of traumatic brain injury in the elderly population: a tertiary center experience in a developing country. *World Neurosurg* 2018;111:e228–34.
- [28] Walter T, Meissner C, Oehmichen M. Pathomorphological staging of subdural hemorrhages: statistical analysis of posttraumatic histomorphological alterations. *Leg Med* 2009;11:S56–62.
- [29] Cummings PM, Trelka DP, Kimberley M. Chapter 6. Injuries. *Atlas of Forensic Histopathology* Boston: Springer; 2010;80–92.
- [30] Murali GR, Dalbir S, Rakesh KV, et al. Dating of acute and subacute subdural haemorrhage: a histo-pathological study. *J Clin Diagn Res* 2016;10:HC01–7.
- [31] Al-Sarraj S, Mohamed S, Kibble M, et al. Subdural haematoma (SDH): assessment of macrophage reactivity within the dura mater and underlying haematoma. *Clin Neuropathol* 2004;23:62–75.
- [32] Spiriev T, Kondoff S, Schaller B. Cardiovascular changes after subarachnoid hemorrhage initiated by the trigeminocardiac reflex—first description of a case series. *J Neurosurg Anesthesiol* 2011;23:379–80.
- [33] Chowdhury T, Mendelowith D, Golanov E, et al. Trigemino-cardiac reflex: the current clinical and physiological knowledge. *J Neurosurg Anesthesiol* 2015;27:136–47.