

## CASE REPORT

# *Haemophilus parainfluenzae* endocarditis in a low-risk woman: a case report

Roberta Gagliardi<sup>1</sup>  | Caterina Sensi<sup>1</sup> | Giulio Flaminio<sup>2</sup> | Ettore De Canale<sup>3</sup> | Roberto Vettor<sup>1</sup> | Eugenio De Carlo<sup>1</sup>

<sup>1</sup>Department of Medicine, University of Padua, Padua, Italy

<sup>2</sup>Department of Molecular Medicine, University of Padua, Padua, Italy

<sup>3</sup>Azienda Ospedale Padova, Padova, Italy

## Correspondence

Roberta Gagliardi, Department of Medicine, University of Padua, Via Giustiniani, 2 - 35128 Padova, Italy.  
Email: roberta.gagliardi@studenti.unipd.it

## Abstract

*Haemophilus parainfluenzae* endocarditis is a rare but dangerous disease. With this work, we intend to show the importance of early diagnosis and appropriate treatment in order to avoid complications. We also highlight the importance of local epidemiology to choose antibiotic prophylaxis for high-risk procedures in selected predisposed patients.

## KEYWORDS

endocarditis, HACEK, *Haemophilus parainfluenzae*, infectious diseases

## 1 | INTRODUCTION

Infective endocarditis is a rare disease caused by the infection of the endocardium surface, with an annual incidence of 3–10/100,000 of the population.<sup>1</sup> The causative pathogens are in most cases bacteria, mainly *Streptococcus spp.* and *Staphylococcus spp.*. Bacteria of the HACEK group (*Haemophilus spp.*, *Actinobacillus actinomycetemcomitans*, *Cardiobacterium hominis*, *Eikenella corrodens* and *Kingella kingae*) are responsible of about 3% (0.8–6%) of the total cases of endocarditis.<sup>2–4</sup>

HACEK are fastidious Gram-negative bacteria that commonly colonize oral and upper respiratory tract, but also urogenital tract, in humans.<sup>2,5</sup> Endocarditis generally occurs in patients with predisposing factors such as cardiac conditions (bicuspid aortic valve, mitral valve prolapse, rheumatic valve disease, congenital heart disease, prior infective endocarditis, patients with implanted cardiac and prosthetic heart valves), other comorbidities (chronic kidney disease, especially when dialyzed,

chronic liver disease, malignancy, advanced age, corticosteroid use, poorly controlled diabetes, indwelling line for venous access, immunocompromised state), intravenous drug use, or previous dental procedures.<sup>1,3,6–8</sup> The clinical presentation is generally sub-acute. In accordance with the international guidelines, the treatment of choice is a third-generation cephalosporin (ceftriaxone), which leads to a favorable outcome in the 80–90% of cases, with or without cardiac surgery.<sup>5</sup> *Haemophilus parainfluenzae* belongs to the HACEK group and causes 27–35% of all HACEK endocarditis. Different studies show that HACEK endocarditis mainly affects young and middle-aged adults (mean age between 27 and 48 years)<sup>3,7–9</sup> and that the clinical presentation is usually sub-acute, with a long-time interval between the onset of symptoms and the diagnosis (34–37 days).<sup>5</sup> This delay in the diagnosis can also explain the large size of cardiac vegetations (>10 mm) and the high probability of embolization.<sup>5,6,10</sup> The involved valve is native in most patients and the common site of the infection is the mitral valve. The outcome with antibiotic

Roberta Gagliardi and Caterina Sensi contributed equally to this work.

This is an open access article under the terms of the Creative Commons Attribution-NonCommercial-NoDerivs License, which permits use and distribution in any medium, provided the original work is properly cited, the use is non-commercial and no modifications or adaptations are made.

© 2021 The Authors. *Clinical Case Reports* published by John Wiley & Sons Ltd.

therapy is favorable in most cases, 40–70% of all cases undergo cardiac surgery and the mortality rate is about 5–10%.<sup>5</sup>

## 2 | CASE DESCRIPTION

Summer of 2020, North-East Italy. A 48-year-old woman was admitted to our Internal Medicine Department for high fever up to 39°C and chills, symptoms that had been ongoing for 12 days, associated with malaise, neck stiffness and headache on the day of admission. Eight days before hospitalization, she was admitted to the Emergency and Acceptance Department of another hospital showing these same symptoms. According to the otolaryngologist evaluation, she started antibiotic therapy with amoxicillin/clavulanate 3 g per day, which was completed 2 days before admission to our facility, with temporary resolution of symptoms.

She also referred signs and symptoms of vaginitis and earache a few days before the onset of fever, however, both conditions had already spontaneously remitted. The relapse of high fever led her to seek further medical assistance. Multiple antigenic and molecular SARS-CoV-2 tests resulted negative.

The patient was healthy and immunocompetent, she did not regularly take any medications and had no significant medical history, except for mitral valve prolapse. Prior to admission, she had not undergone any procedures at risk such as dental treatment. Upon admission she was alert, with the following vital signs: blood pressure 115/70 mmHg, pulse 90 bpm rhythmic, respiratory rate 18 bpm, afebrile. Clinical examination showed only a mild apical systolic murmur, neurological examination was negative; laboratory tests showed leukocytosis (WBC  $14.6 \times 10^9/L$ ), increased C reactive protein (CRP 86 mg/L),

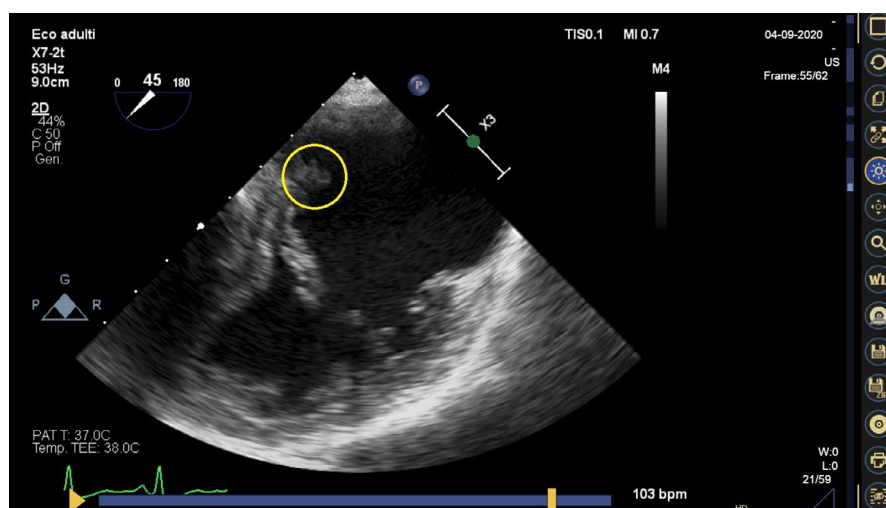
mildly increased I-troponin (TnI 18->57 ng/L) and urine test consistent with urinary tract infection (UTI).

Blood and urine cultures were taken upon admission and during hospitalization; antibiotic therapy with intravenous ceftriaxone at a dose of 2 g per day was initiated with rapid clinical response. ECG showed sinus rhythm without abnormalities. Taking into consideration her clinical history, symptoms, presence of systolic murmur, laboratory examinations and increased TnI levels we decided to investigate infective endocarditis.

A trans-thoracic echocardiogram showed a 15 mm vegetation on the atrial side of the posterior mitral-valve flap, confirmed by a trans-esophageal echocardiogram (Figure 1). The first two blood cultures showed the presence of *Haemophilus parainfluenzae* (susceptible to penicillins and cephalosporins), all other performed cultures proved to be negative. The method of identifying *Haemophilus parainfluenzae* was MALDI-TOF (Matrix-Assisted Laser Desorption Ionization Time-of-Flight); the device was the VITEK<sup>®</sup> MS of bioMérieux.

Eventually, we were able to diagnose definite infective endocarditis according to modified Duke criteria, with two major criteria (typical microorganism consistent with IE from two separate blood cultures and vegetation on echocardiogram examination).<sup>1</sup>

Abdomen ultrasonography did not show any peripheral embolization. During hospitalization, the patient did not present symptoms and signs of meningitis, such as headache and neck stiffness, or focal neurological signs. The day before her discharge she had an episode of blurred vision that regressed in a few seconds, not accompanied by other symptoms like nausea, vomiting, photophobia, or lethargy. The neurological examination was negative. However, we performed *fundus oculi* examination and brain and neck CT scan to exclude meningitis or cerebral embolization; both examinations resulted negative.



**FIGURE 1** Trans-esophageal echocardiogram showing a vegetation on the atrial side of the posterior mitral-valve flap

The patient completed 6 weeks of antibiotic treatment with i.v. ceftriaxone; she repeated blood cultures every 2 weeks for 3 months and a trans-thoracic echocardiogram, which resulted negative. There was no need for cardiac surgery, but follow-up was recommended.

### 3 | DISCUSSION

Our patient showed the most common features of *H. parainfluenzae* endocarditis (young age, large vegetation on the mitral valve, both more common in women)<sup>3,7-9,11</sup> and she presented a predisposing condition, even though mitral prolapse is not included among those classified as at highest risk. Nevertheless, this case of infective endocarditis lacked a clear causative event, although the absence of risk factors is rare but not unique with *H. parainfluenzae* endocarditis.<sup>2,12</sup> In particular, the patient did not undergo any dental procedure before hospital admission.

History of recent culprit procedures is a possible causative event of bacteremia and it is generally more common in females than in males. Rheumatic valvular disease, comorbidities, and complications are also more frequent in women, but our patient did not present any of these characteristics.<sup>11</sup> The diagnosis was prompted by the apparently inexplicable TnI levels elevation and this allowed us to start the therapy early. TnI levels are related to endocarditis prognosis.<sup>13,14</sup> Many studies demonstrate the association between TnI levels elevation and a worse prognosis, including in-hospital stay, 1-year mortality and other negative outcomes such as heart failure, cardiac abscess, valve replacement, central nervous system events, and intracranial hemorrhage. As reported in the literature, there is an inverse relationship between survival and increased troponin levels. This marker can indicate myocardial involvement of infection, embolization of septic material through the coronary arteries, and local invasion with the formation of cardiac abscess; it can also correlate with severe sepsis. This association shows the importance of TnI as a prognostic factor in endocarditis.<sup>13-16</sup> The absence of embolic complications may be explained by the relatively short period between the onset of symptoms and the beginning of adequate therapy (12 days, much shorter than the mean 34-37 days reported in the literature<sup>5</sup>), and probably by the previous amoxicillin/clavulanate treatment.

As for the origin of the infection, we suspect either a urinary tract or an ear infection; urinary test was consistent with UTI, but urinary culture came up negative. Nevertheless, routine laboratory protocol does not include CHOC agar medium, which is necessary to isolate *Haemophilus spp.*<sup>17</sup> In case of an ear infection, supported

by the history of earache, we would consider UTI as a collateral event.

In conclusion, our patient was at low risk for endocarditis. It is important to assess patients at highest risk and to indicate prophylaxis before dental procedures that involve manipulation of gingival tissue, manipulation of the periapical region of teeth, or perforation of the oral mucosa, as recommended by the most recent guidelines.<sup>18</sup>

### 4 | CONCLUSION

*Haemophilus parainfluenzae* endocarditis is a rare but serious disease. The pathogen causes subacute endocarditis and embolic complications are common. We suggest that even with fast resolution of fever with antibiotic regimen, the presence of elevated and suspect TnI levels should prompt further investigations, especially in younger patients without clear risk factors.

This case also supports the importance of blood and urinary sampling for cultures before the initiation of antibiotic regimens.

In the rather unusual case just described, empiric therapy with amoxicillin-clavulanate probably avoided an adverse clinical course even if it was not able to completely eradicate the infection.

*Haemophilus parainfluenzae* frequently colonizes the upper respiratory tract in human,<sup>2,5</sup> and thus, endocarditis may follow dental procedures: it is important that dentists consult local epidemiology on antibiotic resistance in order to select the best antibiotic prophylaxis in selected patients at high risk who undergo certain dental procedures.

### ACKNOWLEDGMENTS

We are grateful to the patient for her consent to the publication of this case report.

### CONFLICT OF INTEREST

None of the authors has a conflict of interest.

### AUTHOR CONTRIBUTIONS

RG, CS, and EDC: were actively involved in the clinical care of the patient and wrote the manuscript. EDCan and GF: reviewed microbiological aspects of the manuscript. RV: reviewed the manuscript. All of the authors read and approved the manuscript.

### ETHICAL APPROVAL

The authors declare there are no competing interests. This case report was written with the consensus of the patient. No patient identifiable data have been reported in the article.

## CONSENT

Patient consent has been signed and collected in accordance with the journal's patient consent policy.

## DATA AVAILABILITY STATEMENT

Data available on request due to privacy/ethical restrictions.

## ORCID

Roberta Gagliardi  <https://orcid.org/0000-0002-4275-2783>

## REFERENCES

- Rajani R, Klein JL. Infective endocarditis: a contemporary update. *Clin Med (Lond)*. 2020;20(1):31-35.
- Christou L, Economou G, Zikou AK, Saplaoura K, Argyropoulou MI, Tsianos EV. Acute haemophilus parainfluenzae endocarditis: a case report. *J Med Case Rep*. 2009;3:7494.
- Chambers ST, Murdoch D, Morris A, et al. HACEK infective endocarditis: characteristics and outcomes from a large, multinational cohort. *PLoS One*. 2013;8(5):e63181.
- Menegueti MG, Machado-Viana J, Gaspar GG, Nicolini EA, Basile-Filho A, Auxiliadora-Martins M. Ischemic stroke and septic shock after subacute endocarditis caused by Haemophilus Parainfluenzae: case report. *J Clin Med Res*. 2017;9(1):71-73.
- Revest M, Egmann G, Cattoir V, Tattevin P. HACEK endocarditis: state-of-the-Art. *Expert Rev Anti Infect Ther*. 2016;14(5):523-530.
- Raza SS, Sultan OW, Sohail MR. Gram-negative bacterial endocarditis in adults: state-of-the-Heart. *Expert Rev Anti Infect Ther*. 2010;8(8):879-885.
- Brouqui P, Raoult D. Endocarditis due to rare and fastidious bacteria. *Clin Microbiol Rev*. 2001;14(1):177-207.
- Ambrosioni J, Martinez-Garcia C, Llopis J, et al. HACEK infective endocarditis: epidemiology, clinical features, and outcome: a case-control study. *Int J Infect Dis*. 2018;76:120-125.
- Faure E, Cannesson O, Schurtz G, et al. Haemophilus parainfluenzae endocarditis in young adults. *Med Mal Infect*. 2017;47(1):58-60.
- Darras-Joly C, Lortholary O, Mainardi JL, Etienne J, Guillevin L, Acar J. Haemophilus endocarditis: report of 42 cases in adults and review. Haemophilus endocarditis study group. *Clin Infect Dis*. 1997;24(6):1087-1094.
- Elamragy AA, Meshaal MS, El-Kholy AA, Rizk HH. Gender differences in clinical features and complications of infective endocarditis: 11-year experience of a single institute in Egypt. *Egypt Heart J*. 2020;72(1):5.
- Lynn DJ, Kane JG, Parker RH. Haemophilus parainfluenzae and influenzae endocarditis: a review of forty cases. *Medicine*. 1977;56(2):115-128.
- Postigo A, Vernooij RWM, Fernández-Avilés F, Martínez-Sellés M. Cardiac troponin and infective endocarditis prognosis: a systematic review and meta-analysis. *Eur Heart J Acute Cardiovasc Care*. 2021;10(3):356-366.
- Thoker ZA, Khan KA, Rashid I, Zafar. Correlation of cardiac troponin I levels with infective endocarditis & its adverse clinical outcomes. *Int J Cardiol*. 2016;222:661-664.
- Lorson W, Veve MP, Heidel E, Shorman MA. Elevated troponin level as a predictor of inpatient mortality in patients with infective endocarditis in the Southeast United States. *BMC Infect Dis*. 2020;20(1):24.
- Gucuk Ipek E, Guray Y, Acar B, et al. The usefulness of serum troponin levels to predict 1-year survival rates in infective endocarditis. *Int J Infect Dis*. 2015;34:71-75.
- Diedrich LK, Manby CL. Haemophilus species as a urinary tract pathogen. *Lab Med*. 2017;48(1):e1-e3.
- Otto CM, Nishimura RA, Bonow RO, et al. 2020 ACC/AHA Guideline for the Management of Patients With Valvular Heart Disease: executive summary: a report of the American College of Cardiology/American Heart Association Joint Committee on Clinical Practice Guidelines. *Circulation*. 2021;143(5):e35-e71. Erratum in: *Circulation*. 2021 Mar 9;143(10):e784.

**How to cite this article:** Gagliardi R, Sensi C, Flaminio G, De Canale E, Vettor R, De Carlo E. *Haemophilus parainfluenzae* endocarditis in a low-risk woman: a case report. *Clin Case Rep*. 2021;9:e05066. <https://doi.org/10.1002/ccr3.5066>