



Percutaneous Grafting and Screw Fixation in Patients with Scaphoid Nonunion*

Enxerto percutâneo e fixação de parafusos em pacientes com não consolidação do escafoide

Muhittin Sener¹ Eyup Cagatay Zengin² Sertac Saruhan³

¹Department of Orthopedics and Traumatology, Izmir Atatürk Training and Research Hospital, Izmir, Turkey

²Department of Orthopedics and Traumatology, Gaziosmanpaşa University, Tokat, Turkey

³Department of Orthopedics and Traumatology, Izmir Bozyaka Training and Research Hospital, Izmir, Turkey

Address for correspondence Sertac Saruhan, MD, Department of Orthopedics and Traumatology, Izmir Bozyaka Training and Research Hospital, Izmir, Turkey (e-mail: cssaruhan@yahoo.com).

Rev Bras Ortop 2022;57(3):437–442.

Abstract

Objective The aim of the present study was to analyze the clinical and radiological results of patients with type-V cystic scaphoid nonunion who were treated with percutaneous grafting and screw.

Methods A total of 11 patients were treated with a percutaneous bone graft with screw fixation. The criteria for inclusion in the study were a type-V scaphoid nonunion and age > 18 years old. Those with humpback deformity, arthritis, ligament damage determined on magnetic resonance imaging, or avascular necrosis (AVN) in the nonunion fragment were excluded from the study.

Results The mean follow-up time was 36 months (range: 15–53 months). At the final follow-up examination, the mean visual analogue scale score was 1.06 (range: 0–2.3). Postoperatively, the mean extension was 61.6° (44–80°), flexion 66° (60–80°), radial deviation 12° (7–20°), and ulnar deviation 25° (20–34°). The mean grip strength of the operated hand was found to be 94%, compared with the healthy side. The results obtained in the Mayo Modified Wrist Score were poor in 2 patients, good in 2 and excellent in 7 (64%). With the exception of 2 patients, union was obtained radiologically in 9 patients, with a mean of 12.6 weeks (range, 8–16 weeks).

Conclusion Percutaneous grafting and screw fixation cannot replace open surgery in cases with deformity, shortening, humpbacking, or in long term nonunions; however, it is a reliable and effective treatment method in selected cases, such as Slade & Dodds type-V cystic nonunion.

Keywords

- ▶ scaphoid bone
- ▶ fracture fixation, internal
- ▶ bone grafting
- ▶ bone screws

* Work developed at Department of Orthopaedics and Traumatology, Izmir Atatürk Training and Research Hospital, Izmir, Turkey.

received
June 8, 2020
accepted
September 17, 2020
published online
April 19, 2021

DOI <https://doi.org/10.1055/s-0041-1724077>.
ISSN 0102-3616.

© 2021. Sociedade Brasileira de Ortopedia e Traumatologia. All rights reserved.
This is an open access article published by Thieme under the terms of the Creative Commons Attribution-NonDerivative-NonCommercial-License, permitting copying and reproduction so long as the original work is given appropriate credit. Contents may not be used for commercial purposes, or adapted, remixed, transformed or built upon. (<https://creativecommons.org/licenses/by-nc-nd/4.0/>)
Thieme Revinter Publicações Ltda., Rua do Matoso 170, Rio de Janeiro, RJ, CEP 20270-135, Brazil

Resumo

Objetivo O objetivo do presente estudo foi analisar os resultados clínicos e radiológicos de pacientes com não consolidação do escafoide do tipo 5 que foram tratados com enxerto percutâneo e parafuso.

Métodos Um total de 11 pacientes foram tratados com enxerto ósseo percutâneo com fixação de parafuso. O critério de inclusão no estudo foi não união do escafoide do tipo 5. Foram excluídos do estudo aqueles com deformidade corcunda, artrite, dano ligamentar determinado por ressonância magnética ou necrose avascular (NAV) no fragmento de não consolidação.

Resultados O tempo médio de seguimento foi de 36 meses (intervalo: 15–53 meses). No exame final de seguimento, o escore médio de escala visual analógica foi de 1,06 (intervalo: 0–2,3). No pós-operatório, a extensão média foi de 61,6° (44–80°), flexão 66° (60–80°), desvio radial 12° (7–20°) e desvio ulnar 25° (20–34°). A força média de aderência da mão operada foi de 94% em comparação com o lado saudável. Os resultados obtidos no *Mayo Modified Wrist Score* foram ruins em 2 pacientes, bons em 2 e excelentes em 7 (64%). Com exceção de 2 pacientes, a consolidação foi confirmada radiologicamente em 9 pacientes com média de 12,6 semanas (intervalo: 8–16 semanas).

Conclusão Enxerto percutâneo e fixação de parafusos não podem substituir a cirurgia aberta em casos de deformidade, encurtamento ou acordundamento, ou em não consolidação a longo prazo; no entanto, é um método de tratamento confiável e eficaz em casos selecionados, tais como a não consolidação do tipo 5 de Slade e Dodds.

Palavras-chave

- ▶ osso escafoide
- ▶ fixação interna de fraturas
- ▶ enxerto ósseo
- ▶ parafusos ósseos

Introduction

Scaphoid nonunion is defined as a bone union that does not occur within a period of 6 months or more from the injury.¹ Although there are varying rates of union, non-union develops in ~ 10% of all scaphoid fractures, and it is associated with factors such as the localization of the fracture, degree of displacement, and time when treatment is initiated.² Other factors, such as a high rate of retrograde blood flow, that the bone being covered in cartilage to a large extent, and presence of high deforming forces, affect the nonunion of scaphoid fractures.³

Slade and Dodds³ classified scaphoid nonunions according to anatomic and physiological characteristics. According to this classification, patients with > 5 mm and < 10 mm bone resorption in the nonunion line, with cyst formation and preserved scaphoid alignment, are defined as type V.³ It has been reported that grafting is necessary to obtain union in these types of patients in whom the perfusion of the nonunion fragment is good.³ The primary aim of treatment is to provide mechanical compression and stable fixation with osteoinductive material to increase the union.

Although a widely used approach is to open the nonunion area, some authors have reported that a closed technique, rather than open surgery, can be successfully used.^{4,5} In this approach, the fibrocartilaginous tissue in the nonunion line works as a mesh, and the percutaneously placed screw holds the bone graft tightly in the nonunion region. Although Slade and Dodds³ described the percutaneous grafting and screw fixations technique in detail, to the best of our knowledge,

there are no clinical studies for type-V cystic nonunions in the literature on this technique.

The aim of the present study was to analyze the clinical and radiological results of patients with type-V cystic scaphoid nonunion who were treated with percutaneous grafting and screw.

Methods

Approval for the study was granted by the local ethics committee under the number 14/11/2018–395. A retrospective evaluation was made of patients who presented at our clinic with scaphoid nonunion between 2014 and 2017. A total of 11 patients were treated with a percutaneous bone graft with a headless compression screw fixation.

The criteria for inclusion in the study were a type-V scaphoid nonunion despite at least 6 months having passed since the injury and patient age > 18 years. Those with cyst area < 5 mm in computed tomography (CT), humpback deformity, arthritis, ligament damage, or avascular necrosis (AVN) in the nonunion fragment determined on magnetic resonance imaging were excluded from the study. All patients were evaluated regarding lateral and ulnar deviation on preoperative posteroanterior radiographs, the amount of bone resorption, the presence of cystic formation, and scaphoid alignment on thin section CT. The tests were interpreted by a radiologist blinded to the study and by the surgeon who performed the operation.

Functional and radiological evaluations were performed for the patients at the final follow-up examinations. Flexion-extension and ulnar-radial deviation were measured with a

goniometer. Grip strength was measured with a model SH 5001 Jamar hand dynamometer (Saehan Corporation, Masan, South Korea). The comparison percentage was recorded by measuring the operated and nonaffected hands in the same position. The functional scores were evaluated with the Mayo Modified Wrist Score. According to this score, patients are evaluated on a scale of 0 to 100, with 0 to 60 points being poor, 60 to 80 being fair, 80 to 90 being good, and 90 to 100 being excellent. Residual pain was evaluated on a visual analogue pain score, according to which 0 corresponded to no pain and 10 to intolerable pain.

Surgical Technique

All operations were performed by the hand surgeon under general anesthesia and with the use of a tourniquet. The volar approach was preferred for patients with the nonunion line in the scaphoid waist region, and dorsal approach was preferred for proximal, and waist regions close to the proximal. If a volar approach was preferred, the wrist was moved into extension and supported from below with a towel. After the placement of a guidewire at the base of the thenar eminence, the guidewire was advanced, taking the proximal pole center as the target under anterior-posterior and lateral fluoroscopy imaging. If a dorsal approach was preferred, the wrist was taken into hyperflexion. The tendons were protected by making a small incision so as not to damage the extensor tendons from the dorsal. By moving the fluoroscopy device into a horizontal position, the beams were obtained vertical to the wrist during imaging. To locate the central axis of the scaphoid, the wrist was taken into flexion and pronation until the scaphoid poles were at the same level under posteroanterior imaging. By making a small incision from the center of the scaphoid, the guidewire was advanced percutaneously under fluoroscopy guidance to the proximal pole. To prevent the wire bending during this process, the wrist was held in flexion. After good reduction was observed under fluoroscopy, the guidewire was pushed toward the distal part.

The distal end of the guidewire was advanced until it made contact with the distal cortex (► Fig. 1A, 1B). The screw

length was measured using a second wire of equal length, then a screw 2 mm shorter than the measured value was selected. Continuing to hold the wrist in the flexion position, the drilling stage began under fluoroscopy guidance. Using a cannulated drill, the nonunion line and distal pole were reamed under fluoroscopy guidance, beginning over the proximal pole over the guidewire in the central axis. At this stage, great care was taken not to pass the distal cortex of the distal pole and not to damage the fibrocartilaginous tissue around the nonunion line.

The drill was removed, and the percutaneous grafting stage was started. A cancellous graft was harvested from the iliac wing on the contralateral side to the affected hand. To reduce morbidity while harvesting the graft, the Acumed Bone Graft Collection System (Acumed, Hillsboro, OR, USA) was used. Sufficient amount of cancellous bone graft was obtained by entering with a 6-mm trephine from a mini-incision.

In the percutaneous grafting stage, the specially designed grafting cannula with a diameter of 3 mm was passed tightly over the guidewire in the wrist and advanced from the proximal pole as far as the nonunion line (► Fig. 2A, 2B). After placing the cancellous graft in the funnel-shaped entry of the cannula, the cancellous graft was advanced to the nonunion region with the help of a central trochar (► Fig. 3A). The nonunion line was continuously checked under fluoroscopy at this stage. Grafting was made until the radiolucent nonunion line appeared radio-opaque (► Fig. 3B). The cannula was removed, and the guidewire in the central axis was left in place.

Then, the fixation stage was started. An Acutrak 2 standard headless compression screw system (Acumed) was selected for implantation. The headless compression screw of length and thickness previously defined over the guidewire was placed on the scaphoid.

Postoperatively, a thumb-supporting cast was applied to all the patients, and after four weeks, follow-up was continued for a further four weeks in a splint. After removal of the cast, wrist exercises were initiated.

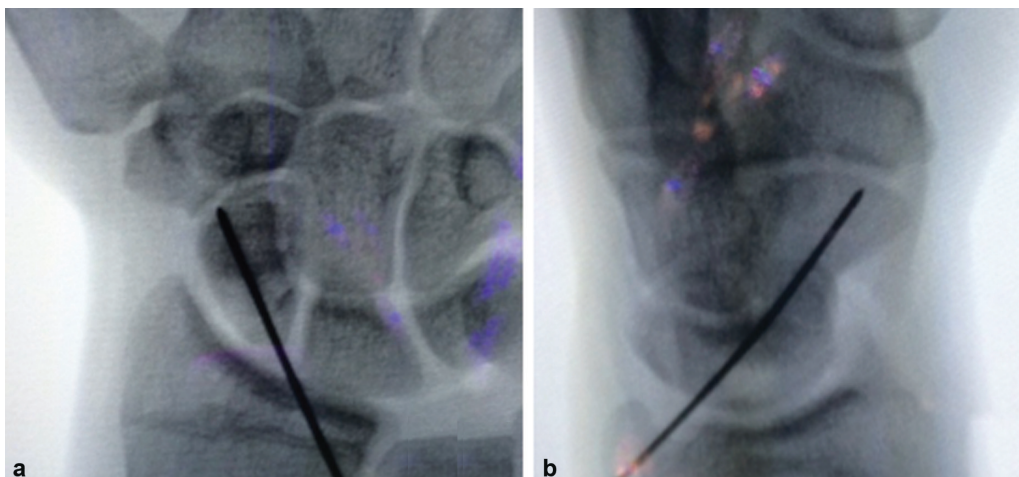


Fig. 1 (a) Final guidewire placement in anteroposterior view. The wire is centered on the proximal pole. (b) The lateral view demonstrates the proper starting point of the guidewire.

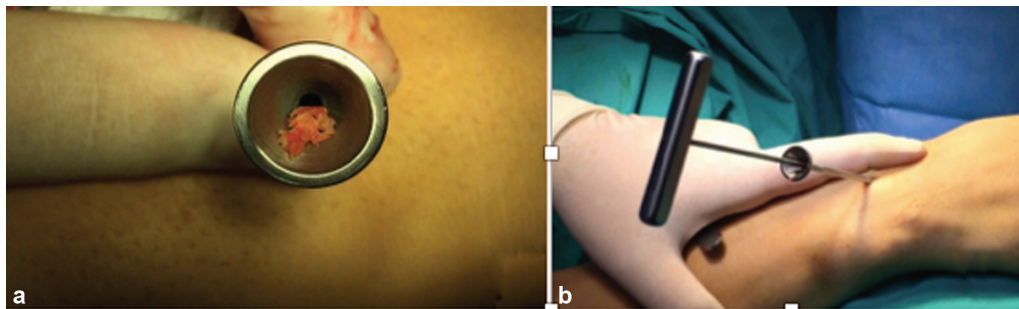


Fig. 2 (a) Placing the cancellous graft in the funnel shaped entry of the cannula. (b) Cancellous graft was advanced to the nonunion region with the help of a central trochar.

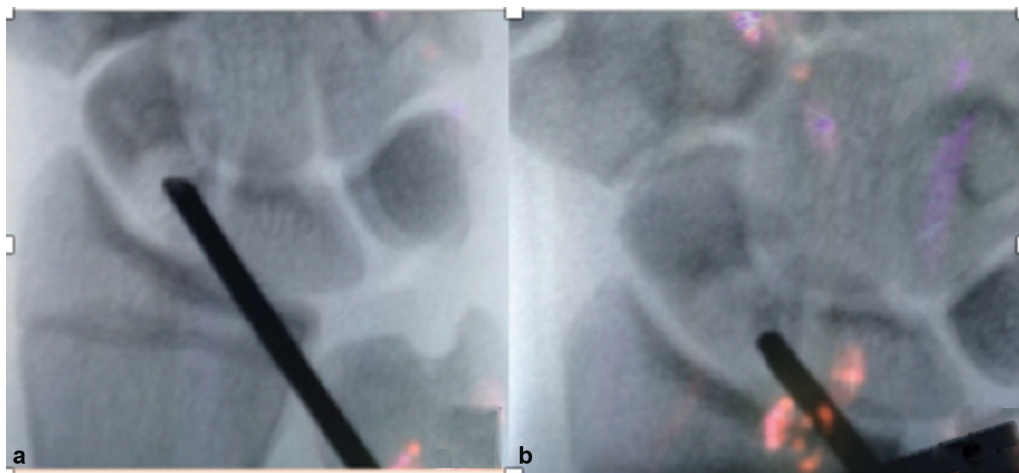


Fig. 3 (a) The fluoroscopic imaging used to monitor the progress of the percutaneous bone grafting. Anteroposterior view shows the radiolucent zone of the scaphoid nonunion. (b) After percutaneously placed bone grafting, the fluoroscopic image shows the radiolucent zone becoming radiopaque.

Radiographic evaluation was performed at 4 weeks postoperatively, and then repeated every 4 weeks until union.

This was verified by the presence of bone trabeculation crossing the fracture site and absence of tenderness. Union was confirmed immediately thereafter by multislice CT.

Results

Of the total 11 patients, a volar approach was used in 3 patients and a dorsal approach in 8. All patients included in the study were male with a mean age of 22 years (range: 19–29 years). The operated hand was the dominant side in seven patients and the non-dominant in four. The time from injury to surgical fixation was a mean of 15 months (range: 7–34 months). In 5 cases, the diagnosis had initially been missed, and in 6 cases, a thumb-supporting wrist plaster cast had been applied for a mean of 5.8 weeks (range: 4–9 weeks). There was no history of previous wrist surgery in any patient. Regarding the localization of the fracture, six were in the waist region and five in the proximal pole. All patients presented with the complaint of pain in wrist extension and tenderness in the snuffbox on palpation. The mean follow-up time was 36 months (range: 15–53 months). At the final follow-up, the VAS improved from a mean of 4.3 (3–6.3) to a mean of 1.06 (0–2.3). The mean preoperative range of movement was 41.8° (32–60°), 52.4°

(33–71°), 5.8° (0–16°), and 15.7° (11–27°) for extension, flexion, radial deviation, and ulnar deviation, respectively. The postoperative range of movement improved to means of 61.6° (44–80°), 66° (60–80°), 12° (7–20°), and 25° (20–34°) for extension, flexion, radial deviation, and ulnar deviation, respectively. Preoperatively, the Mayo modified wrist score was poor in 6 patients (54%), fair in 4 (36%), and good in 1 (10%). This improved to 7 excellent (64%), 2 good (18%), and 2 poor (18%) results at 1 year. The mean preoperative grip strength of the operated hand was found to be 82% compared with the healthy side. This improved 94% postoperatively. The functional scores were not statistically analyzed. With the exception of 2 patients, union was obtained radiologically in 9 patients, with a mean of 12.6 weeks (range, 8–16 weeks) (– Fig. 4A, 4B, 4C). In 2 patients, there was no union at 8 months postoperatively, and the complaints persisted, so open grafting and screws were applied with dorsal incision. Bone union was achieved in the postoperative 16th week in both patients.

Discussion

As a result of the percutaneous grafting and screws applied to the patients with type-V cystic scaphoid nonunion in this study, union and good–excellent functional results were obtained in 9 of the 11 patients with this technique.

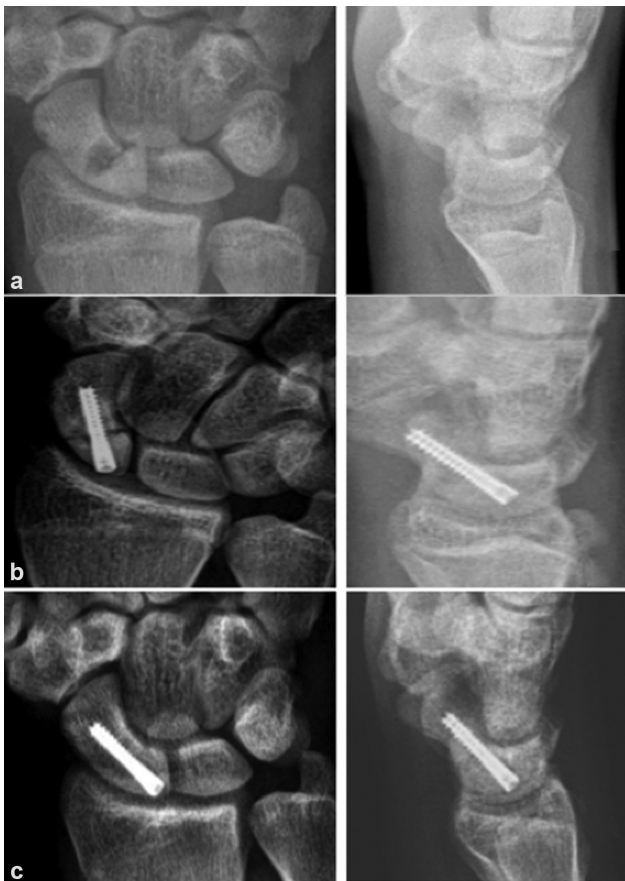

Fig. 4 (a) Preoperative wrist anteroposterior (AP) and lateral view showing Slade type-V scaphoid nonunion. (b) Wrist AP and lateral view 1 month after surgery. (c) Wrist AP and lateral view 1 year after surgery confirms bony union of the scaphoid.

The main aim of treatment in scaphoid nonunion is to obtain rigid fixation without disrupting circulation.⁶ Therefore, fixations made with less soft-tissue dissection with a minimally invasive technique has become widely preferred in recent years.^{7,8}

Closed drilling in the nonunion line using a percutaneous technique stimulates healing by removing fibrous tissue from the pseudoarthrosis line, and in cases in which there is excessive bone resorption, it allows closed grafting without damaging the scaphoid surface.^{9–11} According to the Slade and Dodds classification of scaphoid nonunions, which is of great use in minimally invasive surgical treatment, rigid fixation without grafting is recommended for early scaphoid nonunions without significant bone resorption (types I–III), while for late nonunions with significant bone resorption (types IV–V), it is recommended that grafting be applied in addition to rigid fixation.³ The percutaneous screw and closed grafting technique has been described in detail.³

Although there are authors in the literature who prefer percutaneous screw only or percutaneous grafting only in types IV–V nonunions, to the best of our knowledge there are no previous studies that have used the two techniques together in a patient series, as we aimed to do in the present study. Mahmoud et al. applied percutaneous screws with a volar approach without grafting to 14 patients diagnosed

with a type V (> 5 mm) scaphoid nonunion and reported that union developed in a mean of 10.8 weeks.¹² It was stated that union could be obtained without any need for grafting, irrespective of the size of the gap in nondisplaced fractures.¹² In this respect, the views of Mahmoud et al.¹² contrast with Slade.³ However, all the fractures in that study with a high rate of union were waist region fractures, and proximal pole fractures were not included in the study.¹² There are two studies in the literature that used a technique similar to ours. Ohta et al.¹³ report excellent results of six scaphoid fibrous nonunion treated by percutaneous fixation with curettage and bone grafting through the distal insertion hole of a fully threaded headless screw. Similarly, Bokhari et al.¹⁴ used a Jamshidi trocar needle for percutaneous grafting for 15 scaphoid fibrous nonunion. The difference between these two studies and ours is that they were performed in patients with fibrous non-union (Slade and Dodds type II) rather than cystic non-union.^{13,14} In a study, 33 patients with no hump-back deformity, AVN in the proximal pole, or arthritis, percutaneous grafting was applied with corticocancellous peg, cancellous graft harvested from the iliac wing and no additional fixation, and union was obtained at a rate of 76%.¹⁵

In the current study, union was obtained in 9 of 11 patients. Of the 6 patients with nonunion in the waist region, union was obtained in all cases, and of the 5 patients with proximal pole nonunion, union was achieved in 3. Grafting was applied to patients with significant bone resorption (5–10 mm), as recommended by Slade, and it was thought necessary to apply additional fixation independently of the graft selection.³

When the two patients where union did not develop were examined, the fractures were seen to be extremely proximal, and the nonunion could be attributed to the proximal fragment being very small.

The preoperative localization of the nonunion is critical for the outcome. While studies of nonunions located only in the waist region have reported union rates of 92 to 100%, this rate falls to 64% in proximal pole nonunions.^{10–12,16} Proximal pole fractures are not an absolute contraindication for percutaneous grafting and screw application. However, in patients with a very proximal fracture and a small fragment, other treatment options may be considered.⁸

The major advantages of this technique are that there is no need for soft-tissue dissection, and fixation and grafting can be applied without damaging the scaphoid surface or the fibrocartilaginous membrane around the nonunion line. Thus, the blood supply of the scaphoid, which is already poor, is not further disrupted. Another minimally invasive method is arthroscopic-assisted bone grafting. Gvozdenovic et al.⁸ compared arthroscopically-assisted bone grafting with percutaneous screw fixation. They achieved similar high union rates in both groups but stated that the operation time was significantly higher in the arthroscopic group due to the learning curve of this technically more advanced method.⁸

A disadvantage of the percutaneous technique is that it requires the frequent use of fluoroscopy. For this reason, possible harmful effects of radiation on the patient and surgical team should be kept in mind.

The limitations of this study may include the low number of patients, the absence of a control group for comparison, and the retrospective nature of the study.

Conclusion

In conclusion, although the present study included a low number of patients, it was seen that a Slade type-V cystic scaphoid nonunion could be successfully treated percutaneously. It is a reliable and effective treatment method in selected cases.

Informed consent was obtained from all individual participants included in the study.

All procedures performed in studies involving human participants were in accordance with the ethical standards of the institutional and/or national research committee and with the 1964 Helsinki declaration and its later amendments or comparable ethical standards. The Ethical approval and grant number of the study is 14/11/2018–395.

Financial Support

There was no financial support from public, commercial, or non-profit sources.

Conflict of Interests

The authors have no conflict of interests to declare.

References

- Ferguson DO, Shanbhag V, Hedley H, Reichert I, Lipscombe S, Davis TR. Scaphoid fracture non-union: a systematic review of surgical treatment using bone graft. *J Hand Surg Eur Vol* 2016;41(05):492–500
- Dias JJ, Brenkel IJ, Finlay DB. Patterns of union in fractures of the waist of the scaphoid. *J Bone Joint Surg Br* 1989;71(02):307–310
- Slade JF III, Dodds SD. Minimally invasive management of scaphoid nonunions. *Clin Orthop Relat Res* 2006;445(445):108–119
- Capo JT, Orillaza NS Jr, Slade JF III. Percutaneous management of scaphoid nonunions. *Tech Hand Up Extrem Surg* 2009;13(01):23–29
- Slade JF III, Geissler WB, Gutow AP, Merrell GA. Percutaneous internal fixation of selected scaphoid nonunions with an arthroscopically assisted dorsal approach. *J Bone Joint Surg Am* 2003;85-A(Suppl 4):20–32
- Günel I, Özçelik A, Göktürk E, Ada S, Demirtaş M. Correlation of magnetic resonance imaging and intraoperative punctate bleeding to assess the vascularity of scaphoid nonunion. *Arch Orthop Trauma Surg* 1999;119(5-6):285–287
- Aydın U, Thirkannad SM. Internal bone grafting for the treatment of scaphoid nonunions. *Tech Hand Up Extrem Surg* 2017;21(01):18–21
- Gvozdenovic R, Joergensen RW, Joerring S, Jensen CH. Arthroscopically assisted bone grafting reduces union time of scaphoid nonunions compared to percutaneous screw fixation alone. *J Wrist Surg* 2020;9(01):13–18
- Ernst SMC, Green DP, Saucedo JM. Screw fixation alone for scaphoid fracture nonunion. *J Hand Surg Am* 2018;43(09):837–843
- Merrell GA, Wolfe SW, Slade JF III. Treatment of scaphoid nonunions: quantitative meta-analysis of the literature. *J Hand Surg Am* 2002;27(04):685–691
- Kang HJ, Chun YM, Koh IH, Park JH, Choi YR. Is arthroscopic bone graft and fixation for scaphoid nonunions effective? *Clin Orthop Relat Res* 2016;474(01):204–212
- Mahmoud M, Koptan W. Percutaneous screw fixation without bone grafting for established scaphoid nonunion with substantial bone loss. *J Bone Joint Surg Br* 2011;93(07):932–936
- Ohta S, Ikeguchi R, Noguchi T, et al. Percutaneous fixation for scaphoid nonunion with bone grafting through the distal insertion hole of fully threaded headless screw. *J Hand Surg Asian Pac Vol* 2016;21(03):357–363
- Bokhari S, Hadi S, Hossain F, Ketzer B. The outcome of using jamshidi biopsy trochar needle in a novel technique for bone grafting in percutaneous internal fixation of scaphoid nonunion. *Open Access Maced J Med Sci* 2018;6(03):506–510
- Bullens PH, Driesprong M, Lacroix H, Vegter J. Treatment of scaphoid non-union with a percutaneous corticocancellous bone graft. *J Hand Surg [Br]* 2005;30(04):365–368
- Somerson JS, Fletcher DJ, Srinivasan RC, Green DP. Compression screw fixation without bone grafting for scaphoid fibrous nonunion. *Hand (N Y)* 2015;10(03):450–453