

Hydronephrosis after retroperitoneal laparoscopic dismembered Anderson–Hynes pyeloplasty in adult patients with ureteropelvic junction obstruction: A longitudinal analysis

Tadahiro Isoyama, Hideto Iwamoto, Seiya Inoue, Shuichi Morizane, Nobuyuki Hinata, Akihisa Yao, Masashi Honda, Takehiro Sejima, Atsushi Takenaka

Division of Urology, Department of Surgery, Tottori University Faculty of Medicine, Yonago, Japan

Article history

Submitted: June 30, 2013

Accepted: Jan. 15, 2014

Correspondence

Tadahiro Isoyama
Division of Urology
Department of Surgery
Tottori University Faculty
of Medicine
36–1, Nishimachi
Yonago 683–8504, Japan
phone: +81 859 38 6607
isoyamat@med.tottori-u.
ac.jp

Objective We evaluated the improvement of hydronephrosis longitudinally after laparoscopic dismembered Anderson–Hynes pyeloplasty in adult patients with ureteropelvic junction obstruction.

Material and methods Sixteen patients underwent laparoscopic pyeloplasty at our institution between January 2006 and June 2012. Hydronephrosis was assessed by ultrasound and intravenous pyelography at 3, 6, 12, 18, and 24 months after pyeloplasty.

Results The mean follow-up time was 24 months. Preoperative hydronephrosis was diagnosed as grade 2 and grade 3 in 8 patients each. Postoperative improvement of the hydronephrosis by one grade was observed in 56%, 73%, 67%, 50%, and 40% of patients at 3, 6, 12, 18, and 24 months, respectively. Improvement of the hydronephrosis by two grades was observed in 6%, 27%, 33%, 50%, and 60% of patients at 3, 6, 12, 18, and 24 months, respectively. In 5 of 12 patients (42%), hydronephrosis was still improving even after 12 months postoperatively.

Conclusions Adult patients demonstrate relatively rapid improvements in the degree of hydronephrosis after laparoscopic pyeloplasty and continue to improve for a long time.

Key Words: adult ♦ hydronephrosis ♦ laparoscopy ♦ pyeloplasty ♦ ultrasonography
♦ pelviureteric junction obstruction

INTRODUCTION

Laparoscopic pyeloplasty is considered a new gold standard for the treatment of ureteropelvic junction obstruction (UPJO). The indications for laparoscopic pyeloplasty are flank pain, infection, stone formation, and decreased renal function. Many studies have reported that laparoscopic pyeloplasty has an excellent success rate ranging from 90–98% [1–5]. Success is usually defined as improvement in hydronephrosis, as determined by ultrasound (US) or intravenous pyelography (IVP), and the improvement of function on diuretic renography along with a decrease in washout time. Although diuretic

renography may be the most accurate modality with which to evaluate surgical outcome, renal US is more commonly used for long-term follow-up because it is less invasive and more cost-effective. Renal US is performed regularly to document the progressive improvement of hydronephrosis after pyeloplasty. Although there have been some published reports on the longitudinal renal sonographic changes after this procedure in children [6, 7, 8], there is no similar report in adults.

We evaluated the improvement of hydronephrosis longitudinally using US and IVP after retroperitoneal laparoscopic dismembered Anderson–Hynes pyeloplasty for adult patients with UPJO.

MATERIAL AND METHODS

Material

Between January 2006 and June 2012, 16 patients with UPJO were treated by retroperitoneal laparoscopic dismembered Anderson–Hynes pyeloplasty at our institution. The group included 8 females (50%) and 8 males (50%) with a mean age of 30 years. All operations were performed by a single surgeon (T.I.). Flank pain was the presenting complaint for 15 patients (94%). Four patients (25%) presented with recurrent pyelonephritis. All 16 patients had UPJO as confirmed by renal US, IVP, retrograde pyelography, and a diuretic renal scan. The patients had the disease on the right side in 4 cases and on the left in 12 cases. Nine patients (56%) had crossing vessels identified at the time of surgery. Four patients (25%) had renal calculi associated with UPJO (Table 1).

Surgical procedure

Laparoscopic dismembered pyeloplasty was performed retroperitoneally under general endotracheal and epidural anesthesia. The patients were positioned in the lateral decubitus position. A 2-cm incision was first made at the midpoint between the 12th rib and the iliac crest in the middle axillary line. After a working space was created in the retroperitoneum by balloon dissector, a 12-mm blunt-tip trocar (camera port) was placed. The pneumoretroperitoneum was established at a pressure of 12 mmHg. A second 12-mm trocar was placed 7 cm dorsal to the camera port under laparoscopic guidance. A third 5-mm trocar was placed in the anterior axillary line at the level of the iliac crest, and a fourth 5-mm trocar was placed in the subcostal region at the anterior axillary line. The lateroconal fascia was incised along the quadratus lumborum muscle, which allowed for exposure of the psoas muscle and the posterior lamina of Gerota's fascia. The ureter was identified and dissected in the cephalad direction toward the ureteropelvic junction (UPJ). After dissection and clear visualization of the UPJO, a stay suture was placed in the medial edge of the renal pelvis and was pulled out through the abdominal wall using Endo Close™. The medial portion of the redundant pelvis was partially excised, and the proximal ureter was laterally spatulated with a 1.0-cm longitudinal incision. The renal pelvis was then dismembered with the proximal ureter and the stenotic segment of the UPJ was resected. A 6F ureteral stent was advanced into the ureter via the uppermost 5-mm port. The first suture, a 4-0 polydioxanone suture, was placed from the most interconnected portion of the renal pelvis to the most inferior point of the ure-

Table 1. Patient characteristics

Sex (male/female)	8/8
Mean age (y) (range)	30 (12–61)
Side of obstruction (left/right)	12/4
Symptom	
Asymptomatic (%)	1 (6%)
Flank or lumbar pain (%)	15 (6%)
Recurrent urinary tract infection (%)	4 (25%)
Concomitant renal calculi (%)	4 (25%)
Crossing vessels (%)	9 (56%)
Mean follow-up (mo)	24 (3–58)

teral spatulation. After the anterior anastomosis was completed, the same suture was applied to the posterior wall of the anastomosis. If a crossing vessel was identified during dissection of the ureter, it was preserved and the ureter was transposed anterior or posterior to the vessel. After hemostasis was confirmed, a 5-mm suction drain was placed in the retroperitoneum, and all wounds were closed. Pyelolithotomy was performed if there were associated stones. After the renal pelvis was transected, stones were removed individually under direct laparoscopic vision with the use of standard laparoscopic graspers.

Follow-up

The ureteral stent was removed at 4 weeks after surgery. Renal US was performed at 3, 6, 12, 18, and 24 months and IVP was performed at 6 and 12 months after surgery. The degree of hydronephrosis was graded as 0 to 3 according to Ellenbogen's grading system [9]. A diuretic renal scan was performed 1 year postoperatively. The procedure was considered successful when patients experienced the complete resolution of pain, improvement of hydronephrosis on US and IVP, and decreased half time clearance ($T_{1/2}$) as measured during a diuretic renal scan.

RESULTS

The mean follow-up time was 24 months. All patients reported a complete resolution of pain at 3 months postoperatively. Preoperative hydronephrosis was diagnosed as grade 2 and grade 3 in 8 patients each. The degree of hydronephrosis as determined based on US was identical to that determined based on IVP. The postoperative improvement of hydronephrosis was 63%, 100%, 100%, 100%, and 100% at 3, 6, 12, 18, and 24 months, respectively. No patient had worsening of hydronephrosis during follow-up. The postoperative improvement of hydronephrosis by one

grade was 56%, 73%, 67%, 50%, and 40% at 3, 6, 12, 18, and 24 months, respectively. Improvement in the degree of hydronephrosis by two grades was observed in 6%, 27%, 33%, 50%, and 60% of patients at 3, 6, 12, 18, and 24 months, respectively (Table 2). Complete resolution of the hydronephrosis was observed in 8 of 16 patients (50%). Hydronephrosis was still improving even after 12 months in 5 of 12 patients (42%) (Figure 1). $T_{1/2}$ improved in 9 of 12 patients (75%) as determined during the diuretic renal scan at 12 months (Table 3). Three patients experienced no changes in the results of the diuretic renal scan 1 year postoperatively. Among these patients, two patients had grade 2 and grade 3 hydronephrosis preoperatively. The degree of hydronephrosis decreased to grade 1 and grade 2 at 6 months, respectively, but no further improvement of hydronephrosis was observed at 24 months. In the third patient who had grade 3 hydronephrosis preoperatively, the degree of hydronephrosis decreased to grade 2 at 3 months and continued to decrease gradually until complete resolution was obtained at 24 months. This case was regarded as successful, although improvement could not be confirmed on the diuretic renal scan. The success rate was 87.5% (14/16 cases).

DISCUSSION

Laparoscopic pyeloplasty provides a minimally invasive alternative to the repair of UPJO. Laparoscopic pyeloplasty was introduced in 1993 by Schussler [10] and was developed worldwide as the first minimal option, which has been shown to reduce hospital stay while offering success rates equivalent to those of the open pyeloplasty [1, 11, 12].

Table 2. Rate of improvement in hydronephrosis as determined on US and IVP after laparoscopic pyeloplasty

	Total improvement	
	One grade	Two grade
3mo	10/16 (63%)	
	9/16 (56%)	1/16 (6%)
6mo	15/15 (100%)	
	11/15 (73.3%)	4/15 (26.7%)
12mo	15/15 (100%)	
	10/15 (66.7%)	5/15 (33.3%)
18mo	12/12 (100%)	
	6/12 (50%)	6/12 (50%)
24mo	10/10 (100%)	
	4/10 (40%)	6/10 (60%)

US = ultrasound; IVP = intravenous pyelography

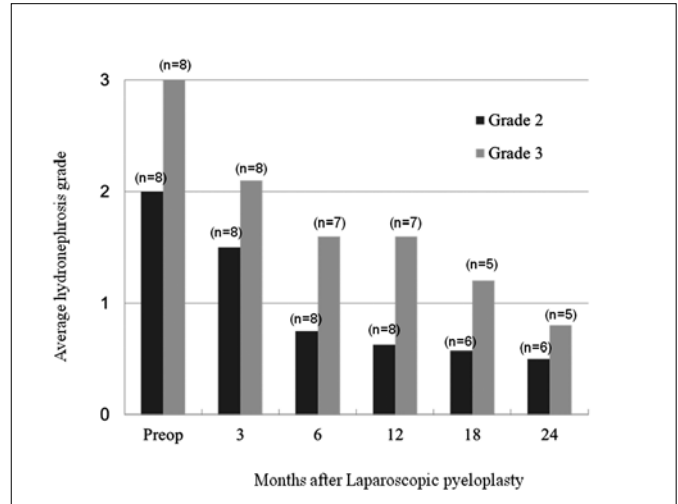


Figure 1. Postoperative changes in average hydronephrosis grade according to preoperative grade.

Laparoscopic pyeloplasty can be performed by either retroperitoneal or transperitoneal approach. An advantage in adopting retroperitoneal laparoscopic approach compared with transperitoneal counterpart for pyeloplasty is related to a more direct path to the UPJ and the low risk of injury to intraperitoneal organ. Conversely, the retroperitoneal approach has a limited working space that may increase the difficulty of reconstruction. Therefore, the choice depends on the surgeon's experience.

Renal US is a standard method for the identification of hydronephrosis. Whereas the magnitude of pelvic enlargement correlates statistically with the likelihood of obstruction, US cannot be used to diagnose obstruction because the degree of pelvic dilatation does not specifically indicate the presence or absence of obstruction, or predict whether the hydronephrosis will improve or worsen. US is meaningful for the evaluation of hydronephrosis when used only for serial measurements [6]. Therefore, the success of laparoscopic pyeloplasty is usually demonstrated radiographically by an improvement in drainage and/or function as visualized by the postoperative diuretic renogram and by decreased hydronephrosis on renal US.

In children, hydronephrosis persists for a long time after pyeloplasty. Amling [7] reported that only 38% of the kidneys improved during the first 6 months of follow-up, while 81% were improved 2 years postoperatively, and ultimate improvement to grade 0 or 1 was noted in only 19% of cases. Kis et al. [13] reported that 102 babies who underwent pyeloplasty were investigated by US at 6 and 12 months postoperatively. One year after surgery, the renal pelvis was smaller in 76% of cases, and renal parenchyma was normal or had increased in

Table 3. The change of T1/2 of the diuretic renal scan after laparoscopic pyeloplasty

Pt	T1/2 (min)	
	Preoperative	Postoperative
1	Unmeasurable	9.5
2	Unmeasurable	Unmeasurable
3	Unmeasurable	Unmeasurable
4	Unmeasurable	15.8
5	Unmeasurable	Unmeasurable
6	Unmeasurable	15.4
7	Unmeasurable	13.9
8	Unmeasurable	10.4
9	Unmeasurable	12.3
10	Unmeasurable	14.8
11	Unmeasurable	9.8
12	Unmeasurable	16.2

92% of cases. The authors reported that the resolution of hydronephrosis after surgery was quite slow in the first postoperative year, while the increase in the renal parenchyma was relatively rapid. In the series by Neste et al. [14], postoperative US and diuretic renograms were reviewed in patients monitored an average of 26 months after pyeloplasty. Improvement as determined using US was much more gradual than the change in renographic pattern with renographic improvement observed well in advance of that observed on the US. There has been no report on the longitudinal assessment of hydronephrosis after pyeloplasty in adults.

In our adult series, an improvement of hydronephrosis was observed in 10 of 16 patients (63%) at 3 months, and all cases showed improvement at 6 months after surgery. All patients were without symptoms or infection after 3 months, although hydronephrosis was still present in many patients for months. In 5 of 12 patients (42%), hydronephrosis was still improving gradually even after 12 months postoperatively, and the complete resolution of hydronephrosis was observed in 8 of 16 patients (50%). The results suggest that hydronephrosis starts to improve relatively earlier in adults than in children and continues to improve gradually over the long term. In children, hydronephrosis may be found as an abdominal mass. On the contrary, in adults, flank pain or urinary tract infection may be present. Since most adult UPJOs are symptomatic, adult patients are diagnosed relatively early when hydronephrosis has increased. For this reason, hydronephrosis in adults seems to be reversible at di-

agnosis. Hydronephrosis may improve rapidly and remain decreased for a long time after the obstruction was treated.

In most institutions, diuretic renogram is usually performed at 3 months and annually thereafter [1, 2, 11]. In our series, patients were followed up with US (with or without IVP) at 3, 6, 12, 18 and 24 months to assess morphologically, and diuretic renogram was performed at 12 months to assess functionally. Since the improvement in hydronephrosis and the improvement observed on the diuretic renal scan were not necessarily seen simultaneously, we recommend that patients who underwent laparoscopic dismembered pyeloplasty should undergo a diuretic renal scan at 12 months postoperatively and be followed-up at least 2 years postoperatively. Concerning the relation between US, IVP, and renal scan, the degree of hydronephrosis as determined based on US was identical to that determined based on IVP. There were three patients who experienced no improvement in the diuretic renal scan at 12 months. Among these patients, two patients had only one grade improvement of hydronephrosis during follow-up. One patient had gradual improvement of hydronephrosis even after 12 months and had complete resolution at 24 months. In this patient it could have been confirmed that $T_{1/2}$ decreased if the diuretic renal scan was performed at 24 months. These results showed that serial US showing improvement of hydronephrosis may be a good alternative to IVP or diuretic renal scan in the follow-up of UPJO patients who underwent laparoscopic pyeloplasty.

This study was limited by the number of patients. Longitudinal analysis of larger numbers of patients with hydronephrosis after laparoscopic pyeloplasty will be necessary.

CONCLUSIONS

The improvement of hydronephrosis after laparoscopic pyeloplasty is relatively gradual in adult patients. Although hydronephrosis had not changed in 37% of patients at 3 months, all cases showed improvement at 6 months, and continuous improvement was found in 40% of patients who were followed-up for more than 12 months. Hydronephrosis improves relatively more rapidly and for a longer period of time in adults compared to pediatric patients. However, a one-grade improvement in the degree of hydronephrosis does not necessarily represent true therapeutic success. Follow-up by diuretic renal scan as well as US is needed if improvement cannot be confirmed by diuretic renal scan at 12 months postoperatively.

References

1. Jarrett TW, Chan DY, Charambura TC, Fugita O, Kavoussi LR. Laparoscopic pyeloplasty: the first 100 cases. *J Urol.* 2002; 167: 1253–1256.
2. Moon DA, El-Shazly MA, Chang CM, Gianduzzo TR, Eden CG. Laparoscopic pyeloplasty: evolution of a new gold standard. *Urology.* 2006; 67: 932–936.
3. Shoma AM, El Nahas AR, Bazeed MA. Laparoscopic pyeloplasty: a prospective randomized comparison between the transperitoneal approach and retroperitoneoscopy. *J Urol.* 2007; 178: 2020–2024.
4. Bauer JJ, Bishoff JT, Moore RG, Chen RN, Iverson AJ, Kavoussi LR. Laparoscopic versus open pyeloplasty: Assessment of objective and subjective outcome. *J Urol.* 1999; 162: 692–695.
5. Türk IA, Davis JW, Winkelmann B, Deger S, Richter F, Fabrizio MD, Schönberger B, Jordan GH, Loening SA. Laparoscopic dismembered pyeloplasty—the method of choice in the presence of an enlarged renal pelvis and crossing vessels. *Eur Urol.* 2002; 42: 268–275.
6. Koff SA. Neonatal management of unilateral hydronephrosis. Role for delayed intervention. *Urol Clin North Am.* 1998; 25: 181–186.
7. Amling CL, O'Hara SM, Wiener JS, Schaeffer CS, King LR. Renal ultrasound changes after pyeloplasty in children with ureteropelvic junction obstruction: long term outcome in 47 renal units. *J Urol.* 1996; 156: 2020–2024.
8. Park S, Ji YH, Park YS, Kim KS. Change of hydronephrosis after pyeloplasty in children with unilateral ureteropelvic junction obstruction. *Korean J Urol.* 2005; 46: 586–592.
9. Ellenbogen PH, Scheible FW, Talner LB, Leopold GR. Sensitivity of gray scale ultrasound in detecting urinary tract obstruction. *Am J Roentgenol.* 1978; 130: 731–733.
10. Schussler WW, Grune MT, Tecuanhuey LV, Preminger GM. Laparoscopic dismembered pyeloplasty. *J Urol.* 1993; 150: 1795–1759.
11. Inagaki T, Rha KH, Ong AM, Kavoussi LR, Jarrett TW. Laparoscopic pyeloplasty: current status. *BJU Int.* 2005; 95: 102–105.
12. Janetschek G, Peschel R, Frauscher F. Laparoscopic pyeloplasty. *Urol Clin North Am.* 2000; 27: 695–704.
13. Kis E, Verebely T, Kovi R, Mattyus I. The role of ultrasound in the follow-up of postoperative changes after pyeloplasty. *Pediatr Radiol.* 1998; 28: 247–249.
14. Neste MG, du Cret RP, Finlay DE, Sane S, Gonzalez R, Boudreau RJ, Kuni CC. Postoperative diuresis renography and ultrasound in patients undergoing pyeloplasty. Predictors of surgical outcome. *Clin Nucl Med.* 1993; 18: 872–876. ■