

Evaluation of childhood solid pseudopapillary tumors of the pancreas

Alper Ozcan,¹ Ceyda Arslanoglu,² Ekrem Unal,¹ Turkan Patiroglu,¹ Mehmet Akif Ozdemir,¹ Kemal Deniz,³ Serdal Sadet Ozcan,⁴ Musa Karakukcu¹

¹Department of Pediatrics, Division of Pediatric Hematology and Oncology, Erciyes University, Faculty of Medicine, Kayseri, Turkey

²Department of Pediatrics, Erciyes University, Faculty of Medicine, Kayseri, Turkey

³Department of Pathology, Erciyes University, Faculty of Medicine, Kayseri, Turkey

⁴Department of Pathology, Training and Research Hospital, Kayseri, Turkey

ABSTRACT

OBJECTIVE: Solid pseudopapillary tumor (SPT) of the pancreas is an extremely rare primary tumor in the pediatric age group. It has a low malignant potential and the prognosis is good if radical resection of the tumor is performed. Local recurrence and distant metastasis has only rarely been reported following incomplete resection.

METHODS: A retrospective review of the medical records of 6 patients diagnosed as SPT according to a histopathological examination at the Children's Hospital of Erciyes University School of Medicine between 2010 and 2017 was performed. Demographic characteristics, tumor localization and size, diagnostic method, immunohistochemical staining features, and medical and surgical treatments employed were recorded.

RESULTS: There were 4 girls and 2 boys with the diagnosis of SPT included in this study. The mean age of the patients was 14 years (min-max: 13–16 years). The most common presenting complaint was abdominal pain. The mass lesion was at the head of the pancreas in 3 cases (50%) and the tail of the pancreas in the remaining 3 patients (50%). A Whipple procedure was performed in 3 cases, a distal pancreatectomy in 1, a distal pancreatectomy plus splenectomy in 1, and a subtotal pancreatectomy in 1 patient. Immunohistochemistry revealed positive staining for beta-catenin, keratin, CD56, vimentin, and CD10 in all cases.

CONCLUSION: SPT is a rarely seen pancreatic mass with low rate of malignancy. Diagnosis may be delayed due to its asymptomatic nature in most cases and a lack of descriptive symptoms. The survival rate is quite high after radical resection.

Keywords: Child; pancreas; pseudopapillary tumor.

Cite this article as: Ozcan A, Arslanoglu C, Unal E, Patiroglu T, Ozdemir MA, Deniz K. Evaluation of childhood solid pseudopapillary tumors of the pancreas. *North Clin Istanbul* 2018;5(3):207–210.

Solid pseudopapillary tumor (SPT) is one of the rarely seen primary tumors of the pancreas. In all age groups they constitute 2–3% of all primary pancreatic tumors [1]. They are more frequently seen in the second, and third decades of life, and in female children [2]. It was firstly defined by Frantz in the year 1959, and it was termed as papillary cystic tumor, solid cystic tumor, Frantz's tumor

[3]. In the year 1996, the World Health Organization designated the term "solid pseudopapillary tumor" for this tumor [4]. It has lower malignancy potential, and its prognosis is very good after radical resection. However local recurrence, and also distant metastasis were reported following incomplete resection [5]. Its pathogenesis has not been clarified completely yet. Some authors claimed that

Received: August 15, 2017 *Accepted:* October 03, 2017 *Online:* April 18, 2018

Correspondence: Dr. Musa KARAKUKCU. Erciyes Universitesi Tıp Fakültesi, Pediatrik Hematoloji ve Onkoloji Anabilim Dalı, Kayseri, Turkey.

Phone: +90 532 381 71 20 e-mail: mkkukcu@yahoo.com

© Copyright 2018 by Istanbul Provincial Directorate of Health - Available online at www.northclinist.com



this tumor has a hormonal origin, some others advocated that these tumors originate from ductal, acinar or primitive cells. Characteristically these tumors are bulky, however they are asymptomatic or have mild symptoms [6].

In this study, clinical characteristics, results of pathophysiologic, immunohistochemical analyses, and surgical treatment have been investigated.

MATERIALS AND METHODS

In this study the files of 6 patients who were diagnosed as SPT based on the histopathological examination of the specimen in Erciyes University Faculty of Medicine, Hospital of Children's Health and Diseases between the years 2010, and 2017 were retrospectively screened. Approval of Ethics Committee of Erciyes University Faculty of Medicine was obtained. Demographic characteristics,

location, and size of the tumor, diagnostic methods, immunohistochemical staining characteristics, medical, and surgical treatments applied were recorded. For immunohistochemical staining, beta-catenin, keratin, chromogranin, CD56, synaptophysin, vimentin, CD10, and cyclinD1 were used.

RESULTS

Six patients (4 female, and 2 male patients with a male/female ratio of 1:2) with a mean age of 14 (min-max 13–16) years who were histopathologically diagnosed as SPT between 2010, and 2017 were included in the study. Admission complaint of 5 (88%) patients was abdominal pain. Abdominal ultrasound (US) performed with the indication of hirsutismus revealed the presence of a mass which established the diagnosis of SPT. The mass lesion was localized on the head (n=3; 50%), and

TABLE 1. The characteristic features of the patients in the pediatric age group followed up with the diagnosis of SPT

Case	Age	Gender	Admission complaint	Location	Size (cm)	Imaging modality	Followup period (months)	Treatment
1	13	K	Abdominal pain	Tail of the pancreas	10	US-MRI	43	Distal pancreatectomy + splenectomy
2	13	E	Abdominal pain	Tail of the pancreas	10	US-MRI	76	Distal pancreatectomy
3	15	K	Abdominal pain	Head of the pancreas	9	CT-MRI	85	Whipple surgery
4	16	K	Hirsutismus	Head of the pancreas	5	US-MRI	96	Whipple surgery
5	16	K	Abdominal pain	Head of the pancreas	6	US-MRI	99	Whipple surgery
6	11	E	Abdominal pain	Tail of the pancreas	5	US-CT-MRI	30	Subtotal pancreatectomy

TABLE 2. The immunohistochemical characteristics of the patients in the pediatric age group followed up with the diagnosis of SPT

Case	Beta-catenin	Ceratin	Chromogranin	CD56	Synaptophysin	Vimentin	CD10	Cyclin D1	NSE
1	+	+	-	+	+	+	+	+	+
2	+	+	+	+	+	+	+		
3	+	+	-	+	-	+	+		
4	+	+	-	+	-	+	+		
5	+	+	-	+	-	+	+		
6	+	+	-	+	+	+	+		

tail (n=3; 50%) of the pancreas. US, and computed tomography (CT) were performed for the identification of the mass. All patients also additionally underwent magnetic resonance imaging (MRI). Median tumor diameter was 16.5 (5–10) cm. Liver function tests, cholestatic, and pancreatic enzymes were within normal limits. The patients were followed up for a median of 71.5 (30–96) months. We performed Whipple surgery (n=3), distal pancreatectomy (n=1), distal pancreatectomy and splenectomy (n=1), and subtotal pancreatectomy (n=1). Complication developed in one patient, and formation of a pseudocyst was also observed (Table 1). Samples harvested from 6 patients were subjected to immunohistochemical analyses. In all patients beta-catenin, ceratin, CD56, vimentin CD 10 staining positivity was detected. In one (16.3%) patient chromogranin, and in 3 (50%) patients synaptophysin positivity were detected (Table 2).

DISCUSSION

SPT is rarely seen in infants, and children, and constitutes 2–3% of all pancreatic tumors. Pediatric patients have a more improved prognosis when compared with adults [1]. Ten years ago very few studies were available on this subject. Standardization of terminology, and increase in the use of immunohistochemical staining, the level of awareness concerning these tumors has increased [8]. In a review performed with 292 patients with SPT median age of the patients at the time of the identification of the tumor was detected as 23.9 years with a male/female ratio of 1:9.4 [9]. In two separate studies performed on children, male/female ratios were found to be 1:27, and 1:2, respectively [8, 10]. In our study this ratio was 1:2, in compliance with the literature.

SPT generally leads an asymptomatic course or causes inexplicit symptoms as abdominal pain, and distension. Therefore they are incidentally detected during physical examination or with imaging modalities [11]. Liver function test results, levels of cholestatic, and pancreatic enzymes, and serum tumor markers are usually within normal limits [12]. In these patients exocrine, and endocrinological insufficiency has not been detected up to now [13]. Our five cases presented with nonspecific complaints as abdominal pain, and only physical examination, and imaging modalities revealed this intraabdominal mass. In our one patient with hirsutismus, polycystic ovary syndrome, incidental abdominal US detected an intraabdominal mass. Liver function test results, cholestatic, and pancreatic enzymes, hormonal evaluation of the all patients were found to be within

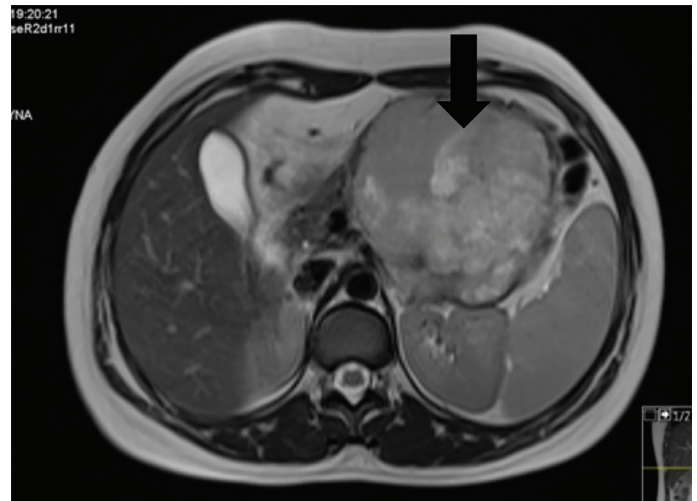


FIGURE 1. On axial T2- weighted images hyperintense heterogeneous giant solid mass in the body, and tail of the pancreas.

normal limits, and consistent with the diagnosis of polycystic ovary syndrome.

In the determination of pancreatic mass lesions, US is the first-line preference because of its lower cost, and lack of radiation exposure US may aid in the determination of the association of the mass with mesenteric, and splenic vessels, and Doppler US helps us to identify intratumoral vascularization [14]. Procacci et al. estimated diagnostic accuracy of CT in pancreatic tumors with cystic component as 60 percent. Although CT plays a major role in the diagnostic evaluation of cystic lesions of pancreas, when compared with MRI, some disadvantages of CT have been reported in demonstrating tissue characteristics as bleeding, cystic degeneration, and presence of a capsule [15, 16]. In our patients, firstly mass lesion was detected using US or CT, then MRI was used to make an initial radiological diagnosis of SPT (Fig. 1).

In children tumor is more frequently (60–70%) localized on the head of the pancreas contrary to its location in adults. In children SPT is localized in the head of the pancreas. However in adult patients SPT is mostly (80%) localized in the body, and the tail of the pancreas [17]. In the present study, contrary to literature findings mass lesion was located in the head of the pancreas in 50%, and in the tail of the pancreas also in 50% of the patients.

It has been reported that pancreatic SPT cells express exocrine, endocrine, mesenchymal, and epithelial cell markers in varying amounts [8]. SPT has a complex immune profile. In previous studies respective percentages of patients demonstrated positive staining with NSE (93%), vi-

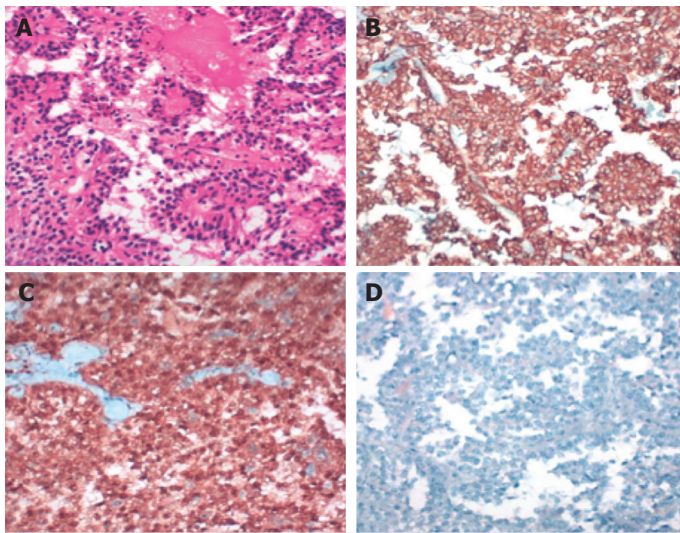


FIGURE 2. Microscopic appearance of pseudopapillary component of the tumor (A) staining with HE (B) Positive staining with vimentin (C) Nuclear, and cytoplasmic positive staining with B catenin (D) Negative staining with chromogranin.

mentin (90%), chromogranin A, cytokeratin, and synaptophysin [2, 8]. In another study performed with 11 pediatric patients with SPT, respective percentages of patients displayed positive staining with NSE (36%), chromogranin A (91%) [8]. However in the present study only one patient (16.3%) manifested positive staining with chromogranin. In all patients, positive staining with beta-catenin, keratin, CD56, vimentin CD 10 was detected. Synaptophysin positivity was detected in 3 (50%) patients (Fig. 2).

Surgical resection constitutes the basis of treatment.. In cases of radical resection of the tumor prognosis is generally good. Long-term survival, and recurrence rates were reported as 90, and 10%, respectively [18]. In 6 cases total surgical resection was achieved. Physical, and US examinations were maintained during follow-up period. During our average follow-up of 6 years any recurrence was not detected.

In conclusion, SPT is a rarely seen pancreatic mass with lower malignancy rates. Since it has nondescriptive characteristics, and asymptomatic course, diagnosis may be delayed. Survival rates are at a higher level when total surgical resection was performed.

Conflict of Interest: No conflict of interest was declared by the authors.

Financial Disclosure: The authors declared that this study has received no financial support.

Authorship Contributions: Concept – A.O., E.U., C.A.; Design – S.S.O., A.O.; Supervision – A.O., M.K., E.U.; Materials – C.A., K.D.,

S.S.O.; Data collection &/or processing – C.A., A.O., S.S.O., K.D.; Analysis and/or interpretation – A.O., M.K., E.U.; Writing – A.O., C.A., S.S.O.; Critical review – T.P., M.A.O.

REFERENCES

1. Sur YK, Lee JH, Kim JK, Park MJ, Kim B, Park MS, et al. Comparison of MR imaging features of solid pseudopapillary neoplasm of pancreas between male and female patients. *Eur J Radiol* 2015;84:2065–70.
2. Branco C, Vilaça S, Falcão J. Solid pseudopapillary neoplasm-Case report of a rare pancreatic tumor. *Int J Surg Case Rep* 2017;33:148–50.
3. Divarçı E, Dökümcü Z, Çetingül N, Nart D, Barbet FY, Ergün O, et al. Radical resection of the pancreas should not always be necessary in the surgical management of pancreatic solid pseudopapillary tumor in children. *Turk J Gastroenterol* 2017;28:214–8.
4. Klöppel G, Solcia E, Longnecker DS, Capella C, Sobin L. *Histological Typing of Tumours of the Exocrine Pancreas*. 2nd ed. Springer-Verlag Berlin Heidelberg; 1996.
5. Morita K, Urushihara N, Fukumoto K, Miyano G, Yamoto M, Nouse H, et al. Solid pseudopapillary tumor of the pancreas in children: surgical intervention strategies based on pathological findings. *Pediatr Surg Int* 2014;30:253–7.
6. Spătaru RI, Enculescu A, Popoiu MC. Gruber-Frantz tumor: a very rare pathological condition in children. *Rom J Morphol Embryol* 2014;55:1497–501.
7. Rebhandl W, Felberbauer FX, Puig S, Paya K, Hochschorner S, Barlan M, et al. Solid-pseudopapillary tumor of the pancreas (Frantz tumor) in children: report of four cases and review of the literature. *J Surg Oncol* 2001;76:289–96.
8. Park JY, Kim SG, Park J. Solid pseudopapillary tumor of the pancreas in children: 15-year experience at a single institution with assays using an immunohistochemical panel. *Ann Surg Treat Res* 2014;86:130–5.
9. Veras E, Mao TL, Ayhan A, Ueda S, Lai H, Hayran M, et al. Cystic and adenofibromatous clear cell carcinomas of the ovary: distinctive tumors that differ in their pathogenesis and behavior: a clinicopathologic analysis of 122 cases. *Am J Surg Pathol* 2009;33:844–53.
10. Jung SE, Kim DY, Park KW, Lee SC, Jang JJ, Kim WK. Solid and papillary epithelial neoplasm of the pancreas in children. *World J Surg* 1999;23:233–6.
11. Parelkar SV, Oak SN, Kapadnis SP, Sanghvi BV, Joshi PB, Sathe P, et al. Solid pseudo papillary tumor of the pancreas: An unusual tumor in children. *J Indian Assoc Pediatr Surg* 2013;18:38–40.
12. Erkişç S, Özşaraç C, Güldür E. Solid-Pseudopapillary Neoplasm of Pancreas: A Case report. *Turk Patoloji Derg* 2003;19:3–4.
13. Raffel A, Cupisti K, Krausch M, Braunstein S, Tröbs B, Goretzki PE, et al. Therapeutic strategy of papillary cystic and solid neoplasm (PCSN): a rare non-endocrine tumor of the pancreas in children. *Surg Oncol* 2004;13:1–6.
14. Shet NS, Cole BL, Iyer RS. Imaging of pediatric pancreatic neoplasms with radiologic-histopathologic correlation. *AJR Am J Roentgenol* 2014;202:1337–48.
15. Sallia R, Festa L, Butturini G, Tonsi A, Sartori N, Biasutti C, et al. Pancreatic cystic tumors. *Minerva Chir* 2004;59:185–207.
16. Cantisani V, Mortelet KJ, Levy A, Glickman JN, Ricci P, Passariello R, et al. MR imaging features of solid pseudopapillary tumor of the pancreas in adult and pediatric patients. *AJR Am J Roentgenol* 2003;181:395–401.
17. Escobar MA, Bond BJ, Schopp J. Solid pseudopapillary tumour (Frantz's tumour) of the pancreas in childhood. *BMJ Case Rep* 2014;2014. pii: bcr2013200889.
18. Çolak B, Çakır M, Çolak MH. Solid pseudopapillary tumor of the pancreas: A Case Report. *Genel Tıp Derg* 2013;23:23–5.