

## INTERSTITIAL LUNG DISEASE AND MICROSCOPIC POLYANGIITIS IN CHILEAN PATIENTS

*Pamela Wurmman, Francisca Sabugo, Fabian Elgueta, Macarena Mac-Namara, Karen Vergara, Daniela Vargas, Maria Luisa Molina, Juan Carlos Díaz, Hector Gatica, Annelise Goecke*

<sup>1</sup>Rheumatology section, Department of Medicine, Hospital Clínico Universidad de Chile, Santiago, Chile; <sup>2</sup>Imagenology Center, Hospital Clínico Universidad de Chile, Santiago, Chile

**ABSTRACT.** *Objective:* To describe the clinical and serological patients characteristics with Microscopic Polyangiitis (MPA) and Interstitial lung disease (ILD). *Methods:* Of all the patients with AAV diagnosed between 2007-2017 at the Hospital Clínico Universidad de Chile, those with MPA and ILD were selected and studied retrospectively. *Results:* All patients were Hispanic; median age at diagnosis 65 years (32-84). 59% were female. All were positive for p-ANCA, 16 patients for MPO. Most common manifestations were constitutional symptoms, weight loss and fever. CT-Scans patterns were Usual Interstitial Pneumonia (UIP) in 10 patients, Nonspecific Interstitial Pneumonia (NSIP) in 6 and fibrosis not UIP or NSIP pattern in 1. In 6 cases, ILD was diagnosed 0.5-14 years before MPA and concomitantly in 11. *Conclusions:* Although infrequent, Microscopic Polyangiitis should be suspected in patients with ILD particularly if extra-pulmonary manifestations that rise the possibility of a systemic illness are present, regardless of the time elapsed between the latter and the diagnosis of this type of lung involvement. (*Sarcoidosis Vasc Diffuse Lung Dis* 2020; 37 (1): 37-42)

**KEY WORDS:** microscopic polyangiitis, interstitial lung disease, ANCA vasculitis

### INTRODUCTION

Microscopic Polyangiitis is a systemic necrotizing vasculitis that predominantly affects small vessels in the absence of granulomas. It is associated to antineutrophil cytoplasmic antibodies (ANCA), with p-ANCA (perinuclear) fluorescence pattern and anti-myeloperoxidase (MPO) specificity. Immune

deposits are scarce or absent (1). Without treatment, the mortality rate in the first year of disease is approximately 80 %. With adequate therapy, survival rates are between 82-92% (2).

The clinical onset of MPA can be acute or protracted. Clinical manifestations vary in scope and severity. Besides musculoskeletal and constitutional symptoms, the most commonly involved systems are: kidney (80-100%), peripheral nervous system and skin (30%) (1).

Pulmonary involvement has been observed in 25-55% of patients. Its most frequent expression is alveolar hemorrhage, showing patchy ground-glass attenuation on high resolution CT scan in 90% of cases (3,4). More recently it has been recognized that interstitial lung disease (ILD) is a significant although infrequent clinical manifestation of MPA (5,6,7). A limited number of ILD associated with

Received: 11 December 2018

Accepted after revision: 4 February 2020

Correspondence: Pamela Wurmman, MD

Rheumatology section, Department of Medicine, Hospital Clínico Universidad de Chile Postal address: Santos Dumont 999, oficina 213D, Independencia, Santiago, Chile

Tel. 56-2-29788236

Fax 56-2-29789083

E-mail: pwurmman@hcuch.cl

MPA has been reported in the literature, two of them in Hispanic population (8,9). Therefore, the clinical and serologic characteristics and the prognosis of these patients is not completely known. Neither is clear if the clinical manifestations are different in patients of different genetic ancestry.

The aim of our study is to report the clinical and serological characteristics of 17 MPA Chilean patients with associated ILD and to compare them with other foreign series.

## PATIENTS AND METHODS

All patients with ANCA associated vasculitis (AAV) diagnosed by a Rheumatologist, that fulfill ACR or Chapell Hill (10,11) classification criteria, between 2007-2017 at the Hospital Clínico Universidad de Chile were studied. Patients with ILD, defined as diffuse parenchymal lung disease on CT scan with UIP or NSIP pattern were selected and followed. All patients had at least two High Resolution Lung CT scan, one at the moment of diagnosis and one after at least 3 months of therapy. The CT scans were re-analyzed by a pulmonary radiologist, who was aware of the diagnosis of vasculitis. Patients with other rheumatic diseases, drugs or toxic exposure that could explain the pulmonary involvement were excluded. Blood cell counts, ESR, blood chemistry and urinalysis were performed monthly in all our patients. Indirect immunofluorescence for ANCA, ELISA assay for MPO-ANCA and PR3-ANCA, detection of rheumatoid factor (RF), anti-citrullinated protein antibodies (ACPA), Antinuclear antibodies, antibodies to extractable antigens, complement and C-reactive protein (CRP), were performed according to the manufacturer's Instructions, at some point to every patient. None of our patients underwent lung biopsy. The Birmingham Vasculitis Activity Score (BVAS) was calculated at diagnosis.

Although this report is a retrospective study, all patients were studied and treated according to an institutional protocol for patients with severe vasculitis. Data are presented as percentages, medians and ranges.

Review of the clinical charts was performed and data were extracted on standardized forms, with the approval of the local Ethics Committee.

## RESULTS

101 Patients with AAV were diagnosed between 2007-2017 at the Hospital Clínico Universidad de Chile. 38 (37.6%) were MPA and 28 of them (73,6%) had pulmonary involvement. 17 had ILD. All patients were Hispanic; median age at diagnosis was 65 years (32-84). 59% were female. Clinical findings are summarized in Table 1. Most common manifestations at diagnosis were constitutional symptoms, weight loss and intermittent fever ( $> 38^{\circ}\text{C}$ ) in 100%, 70% and 70%, respectively. All patients had normocytic, normochromic anemia, high ESR (mean 83 mm/hr., range 33 - 120) and CRP (8-15 times above upper normal limit). All were positive for p-ANCA, 16 patients for MPO (titers between 23 and 100 IU; Normal  $<5$ ). The median BVAS score at diagnosis calculated in 16 patients was 15.18 (range= 13-28).

In 10 cases, ILD was diagnosed concomitantly with MPA. In the other 7 patients idiopathic pulmonary fibrosis was diagnosed 0.5 to 14 years before AAV. In these patients vasculitis associated-ILD was suspected when additional non-respiratory symptoms appeared leading to further study. 5 patient developed signs of pulmonary hemorrhage.

The patterns described at CT Scans were Usual Interstitial Pneumonia (UIP) in 10 patients and Nonspecific Interstitial Pneumonia (NSIP) in 6 patients. One patient did not meet the complete criteria of UIP or NSIP. Non specific radiographic finding that might suggest vasculitis etiology was found.

All except 3 patient received 6 monthly iv cyclophosphamide (CF) as induction therapy. One patient died soon after the diagnosis, in two patient CF was suspended due to severe infections. All patients started with prednisone [1 mg/kg/day]. In 5 patients with associated alveolar hemorrhage, mononeuritis multiplex or optic neuropathy, methylprednisolone pulses [1gram/day per 3 days] were administered prior to oral therapy. Maintenance therapy was carried out with Azathioprine [1.5-2 mg/kg/day], and corticosteroids in low doses [5-10 mg/day]. 2 patients with progressive lung involvement received Rituximab one with stabilization of the disease, the other without success, died 17 months after diagnosis. One patient received rituximab due to relapse with alveolar hemorrhage with good response.

All patients with neurological involvement remained with some degree of sequelae. Arthritis, cu-

**Table 1.** Clinical features in 17 MPA with ILD patients

Age	Sex	BVAS (Initial)	CT	Chronology ILD-MPA (month)	RN	MC	NS	MS	Treatment	Mortality
55	M	20	UIP	C	NO	NO	MM	M/S	CS/CF/AZ	NO
68	F	17	UIP/DAH	B (10)	NO	LR	PNP	M/A	CS/CF/AZ	NO
79	M	15	UIP	B (5)	NO	LR	PNP	M/S	CS/CF/AZ	NO
69	F	15	UIP	C	NO	LR	PNP	S	CS/CF/AZ	NO
77	F	19	UIP	C	GN	LR/CV	MM/SNHL	S	CS/CF/AZ	Śí
64	F	13	UIP	C	GN	LR	NO	M/A	CS/CF/AZ	NO
81	M	19	UIP	C	GN	NO	NO	NO	CS/CF/AZ	NO
84	F	22	UIP/DAH	C	RPGN	Oral Ulcers	NO	NO	CS/CF	Śí
63	F	22	UIP	B (168)	GN	NO	CNS/ SNHL	NO	CS/CF/AZ	NO
63	M	24	NSIP	B (24)	NO	NO	MM	S	CS/CF/AZ	Si
53	F	23	NSIP	C	GN	LR	NO	A	CS/CF/RX/AZ	Śí
68	F	13	NSIP/DAH	B (50)	NO	NO	PNP	M	CS/CF/PX/AZ	Śí
57	M	25	NSIP/DAH	C	RPGN	NO	PNP	NO	CS/CF/AZ	NO
78	M	19	Not UIP/Not NSIP	B(60)	NO	NO	SNHL	M/S	CS/CF/AZ	NO
54	F	16	NSIP	C	NO	LR	PNP	A	CS/CF/AZ	NO
32	F	28	UIP/DAH	B(84)	NO	CV	NO	NO	CS/CF/AZ	NO
54	M	NA	NSIP	C	GN	NO	NO	M	CS/CF/RX	NO

M: Male F: Female; Y: Yes N: No ;B: Before C: Concomitant ;ILD: Interstitial Lung Disease MPA: Microscopic Polyangiitis CT: Computed Tomography UIP: Usual Interstitial Pneumonia NSIP: Non Specific Interstitial Pneumoniae DAH: Diffuse alveolar hemorrhage; RN: renal GN: Glomerulonephritis RPGN: Rapidly progressive glomerulonephritis MC: Mucocutaneous LR: Livedo CV: Cutaneous vasculitis; NS: Nervous system MM: Multiple Mononeuritis PNP: Polyneuropathy SNHL: Sensorineural hearing loss CNS: Central nervous system ; MS: Musculoskeletal M: Myalgia S: Synovitis A: Arthralgia ;CS: Corticosteroids CF: Cyclophosphamide AZ: Azathioprine RX: Rituximab PX: Plasmapheresis

taneous manifestations and constitutional symptoms remitted with treatment without relapse.

5 of 17 patients analyzed, died. 3/5 (60%) with NSIP and 2 (40%) with UIP; 2 because of pulmonary infection, one from stroke, 1 from catastrophic respiratory failure due to disease progression and 1 died from unknown cause.

Survival analysis - Kaplan-Meier curve comparison of patients with AAV with and without ILD was performed. No statistically significant difference was found between two groups. (Figure 1)

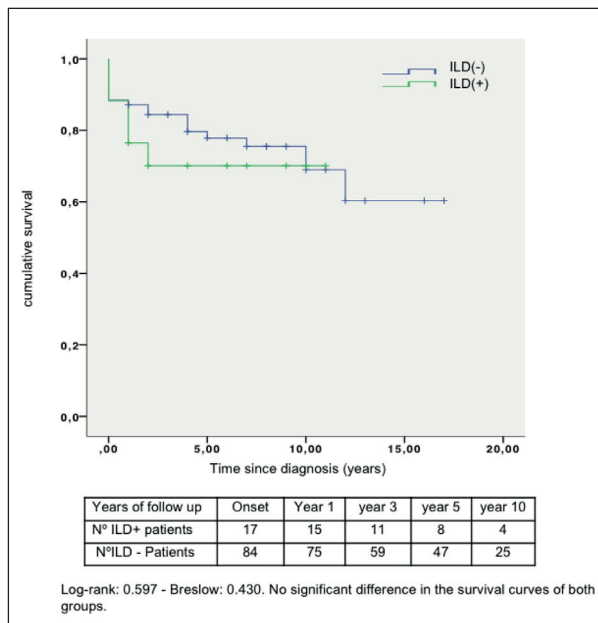


Fig. 1.

## DISCUSSION

Classically, MPA was described as a kidney-lung syndrome; however, during the last few years new forms of presentation, such as ILD, have been reported (5,12). To date, the clinical and pathological characteristics of ANCA associated ILD do not allow differentiate from idiopathic pulmonary fibrosis (IPF) (13). The prevalence of ANCA antibodies in patients with isolated IPF is estimated to be 8 to 36% (13,14,15). However, ILD associated to ANCA is not enough to diagnose AAV. The diagnosis also requires another clinical features that demonstrate vasculitis.

There is some data that suggests that the clinical phenotype of MPA differs with ethnicity so it is relevant to study clinical manifestations and outcomes of the disease in different populations (14,16). To our knowledge, there are only few cases of ILD associated to MPA reported in Hispanic population and our report has the biggest number of patients from South America (12)

The prevalence of ILD as a manifestation of MPA is thought to be low. However, different series report that among all MPA patients, ILD prevalence range from 2,7 to as high as 45%, with slight predominance in men, and 65 years as median age of presentation (14). We are reporting 17 cases of MPA

with ILD in Chilean patients. In our cohort, 44,7% of MPA patients had ILD, the median age at presentation was 64,6 years (32-84), and 59% were female. Demographic data are similar to Asiatic patients and slightly older than in the other two Latin American series (Table 2).

As described in the literature, ILD can precede or occur concomitantly with other vasculitic manifestations in 14-85% and 36-67% respectively (6,12,14,15). In our cohort 41,2% preceded and 58.8% appeared simultaneously with MPA. No patient developed new ILD after the MPA diagnosis. As shown on table 2 we found a higher percentage of NSIP (35%) on CT scan than other patterns.

In many of our patients, the association of fever, polyarthritis, cutaneous manifestations and peripheral neuropathy were the findings that led us to suspect systemic vasculitis, and the interpretation of lung involvement as a manifestation of MPA occurred afterwards. In all of our patients, nonspecific findings, such as anemia, high ESR and CRP, rather than ILD, contributed to raise the suspicion of systemic illness. It is important to point out that most of our patients had high titers of rheumatoid factor with negative ACPA. This lead to an initial misdiagnosis of rheumatoid arthritis in two of our patients.

It has been reported that between 80 and 100% of MPA patients have some degree of kidney involvement (1). Similar rates have been previously described in the series of ILD associated to AAV (5,6,14,15). Interestingly only 47% of our patients had clinical or laboratory expression of glomerular injury, and all of them had favourable outcome after treatment (Table 1).

The presence of ILD has been associated with poor prognosis and mortality in MPA (16,17). Reported mortality in ILD associated to AAV reaches 80 % (5,6,14,15). Factors associated with death in this patients are age at diagnosis of AAV, age at diagnosis of ILD, weight loss, eosinophil count and respiratory insufficiency. (17). In our series the mortality rate was 30 %. The higher percentage of NSIP pattern (35%) in our patients could explain the lower mortality rate compared with the predominance UIP pattern reported worldwide. In our cohort, we found no significant difference in mortality between groups with AAV with and without ILD, however this could be related to the sample size (Figure 1).

The age at diagnosis of our patients is similar

**Table 2.** Clinical and tomographic findings in worldwide series

Country	CHI	ARG	MEX	CHIN	JAP	USA	CAN	FRA	UK
N° patients	17	9	19	19	19	3	6	49	14
Age (mean)	64.6	58.4	54.2	63.6	66.2	72.3	69.8	68	67.3
Sex % (Female)	59	54.5	47.1	58	48	76.7	50	39	28.5
<b>Chronology ILD-MPA %</b>									
• Before	41.2	55,5	82,3	68,4	52,6	33,3	50	45	14.4
• Concomitant	58.8	54.5	17.7	31.5	47.3	76.7	33.3	21	64.2
• After	0	0	0	0	0	0	16.7	12	21.4
<b>CT %.</b>									
• UIP	59	88.8	100	100	100	0	100	57	57.1
• NSIP	35	0	0	0	0	0	0	7	7.1
• non UIP-NSIP	6	11.2	0	0	0	100	0	26	35.8
<b>Mortality %</b>	30	44.4	41.2	31	47	33.3	83.3	61	71

CHI: Chile ARG: Argentina MEX: México CHIN: China JAP: Japan USA: United States CAN: Canada FRA: Francia UK: United Kingdom. ILD: Interstitial Lung Disease MPA: Microscopic polyangiitis CT: Computed Tomography UIP: Usual Interstitial Pneumoniae NSIP: Non Specific Interstitial Pneumoniae.(7,14)

to what has been described in other series. However, in contrast with our results (female 59%), in European series a male predominance has been reported, 66,3% (5,13,16). The time of onset of pulmonary involvement is highly variable and could precede, be concomitant with or develop after other vasculitic manifestation. (Table 2)

ILD has been progressively described as a manifestation of MPA. Our reports suggest that the presence of constitutional symptoms, other parenchymal involvement, anemia, high ESR or CRP should raise the suspicion of AAV. In these patients testing for ANCA is of especial interest.

ILD associated to ANCA vasculitis might be a potentially treatable cause of ILD. Here we report the first series of ILD associated to MPA in Chilean patients. Further studies are warranted to determine specific clinical characteristics and best therapeutic approach in this newly described subset of MPA patients in different populations.

## REFERENCES

- Chung AS, Seo P. Microscopic Polyangiitis. *Rheum Dis Clin NA*. 2010;36:545-558.
- Mukhtya C, Flossmann O, Hellmich B, et al. Outcomes from studies of antineutrophil cytoplasm antibody associated vasculitis: a systematic review by the European League Against Rheumatism systemic vasculitis task force. *Ann Rheum Dis* 2008; 67:1004-10.
- Ando Y, Okada F, Matsumoto S, et al. Thoracic manifestation of myeloperoxidase antineutrophil cytoplasmic antibody (MPO-ANCA) related disease. CT findings in 51 patients. *J Comput Assist Tomogr*. 2004;28(5):710-6.
- Villiger PM, Guillevin L. Microscopic Polyangiitis: clinical presentation. *Autoimmun Rev*. 2010;9:812-9.
- Eschun GM, Mink SN, Sharma S. Pulmonary interstitial fibrosis as a presenting manifestation in perinuclear antineutrophil cytoplasmic antibody Microscopic Polyangiitis. *Chest* 2003;123:297-301.
- Tzelepis GE, Kokosi M, Tzioufas A, et al. Prevalence and outcome of pulmonary fibrosis in Microscopic Polyangiitis. *Eur Respir J*. 2010;36:116-121.
- Comarmond C, Crestani B, Tazi A, Hervier B, et al. Pulmonary fibrosis in antineutrophil cytoplasmic antibodies (anca)-associated vasculitis: a series of 49 patients and review of the literature. *Medicine (Baltimore)*. 2014;93:340-9.
- Flores-Suarez LF, Ruiz N, Saldarriaga Rivera LM, Pensado L. Reduced survival in Microscopic Polyangiitis patients with pulmonary fibrosis in a respiratory referral center. *Clin Rheumatol*. 2015;34:1653-4.
- Fernandez Casares M, Gonzalez A, Fielli M, Caputo F, Bottinelli Y, Zamboni M. Microscopic Polyangiitis associated with pulmonary fibrosis. *Clin Rheumatol*. 2015;34:1273-7.
- Leavitt RY, Fauci AS, Bloch DA, et al. The American College of Rheumatology 1990 criteria for the classification of Wegener's granulomatosis. *Arthritis Rheum*. 1990 Aug;33(8):1101-7.
- Jennette JC, Falk RJ, Bacon PA, et al. 2012 revised International Chapel Hill Consensus Conference Nomenclature of Vasculitides. *Arthritis Rheum*. 2013 Jan;65(1):1-11.
- Alba MA, et al. Interstitial lung disease in ANCA vasculitis. *Autoimmun Rev* (2017). Jul;16(7):722-729
- Nozu T, Kondo M, Suzuki K, et al. A comparison of the clinical features of ANCA-positive and ANCA-negative idiopathic pulmonary fibrosis patients. *Respiration*. 2009;77(4):407-15
- Arulkumaran N, Periselenis N, Gaskin G, et al. Interstitial lung disease and ANCA-associated vasculitis: a retrospective observational cohort study. *Rheumatology*. 2011;50:2035-43
- Foulon G, Delaval P, Valeyre D, et al. ANCA-associated lung fibrosis: analysis of 17 patients. *Respir Med*. 2008;102(10):1392-98.

16. Ahn JK, Hwang JW, Lee J, et al. Clinical features and outcome of Microscopic Polyangiitis under a new consensus algorithm of ANCA-associated vasculitides in Korea. *Rheumatol Int.* 2012;32:2979-86
17. Pulmonary Fibrosis in ANCA-associated Vasculitis. *Clin Rheumatol.* 1997;11(2):423-46.
18. Luqmani RA, Exley AR, Kitas GD, et al. Disease assessment and management of the vasculitides. *Baillieres Clin Rheumatol.* 1997;11(2):423-46.