

RHINOLOGY

Posterior lacrimal sac approach technique without stenting in endoscopic dacryocystorhinostomy

Dacriocistorinostomia endoscopica con approccio posteriore al sacco lacrimale senza utilizzo di stent

E. EMANUELLI¹, F. PAGELLA², G. DANÉ², A. PUSATERI², G. GIOURGOS², P. CARENA², E. ANTONIAZZI³, P. VERDECCHIA⁴, E. MATTI²

¹ Department of Otorhinolaryngology and Otologic Surgery, Azienda Ospedaliera - Policlinico of Padua, University of Padua, Italy; ² Department of Otorhinolaryngology, University of Pavia and Foundation IRCCS Policlinico "San Matteo", Pavia, Italy; ³ Department of Ophthalmology, University of Pavia and Foundation IRCCS Policlinico "San Matteo", Pavia, Italy; ⁴ Department of Ophthalmology, Azienda Ospedaliera - Policlinico of Padua, University of Padua, Italy

SUMMARY

The purpose of this study is to evaluate the effectiveness of endoscopic dacryocystorhinostomy by the posterior lacrimal sac approach without use of lacrimal stents or harvest of mucosal flaps as a valid surgical procedure for the treatment of an obstruction of the lacrimal pathways. A retrospective evaluation was conducted in a cohort of 75 patients between 2007 and 2011. A total of 78 endoscopic dacryocystorhinostomies were analyzed in 75 patients. After a mean follow-up of 25.7 months (minimum 12 months), 93.3% had a complete relief of symptoms after surgery. Our experience appears to confirm that the endoscopic posterior lacrimal sac approach with no stent insertion or mucosal flaps creation is a good alternative to other known endoscopic procedures.

KEY WORDS: Dacryocystorhinostomy • DCR • Epiphora • Endoscopy • Lacrimal sac • Posterior approach • Stent • Mucosal flap • Endoscopic surgery

RIASSUNTO

Scopo di questo lavoro è stato valutare l'efficacia della dacriocistorinostomia endoscopica con approccio posteriore al sacco lacrimale senza l'utilizzo di stent o di flap mucosi nel trattamento della patologia ostruttiva delle vie lacrimali. Un'analisi retrospettiva è stata condotta in un gruppo di 75 pazienti tra il 2007 e il 2011. Sono state analizzate un totale di 78 dacriocistorinostomie endoscopiche in 75 pazienti. Dopo un follow-up medio di 25.7 mesi (minimo follow-up 12 mesi), nel 93.3% si è assistito ad una completa risoluzione della sintomatologia clinica. La nostra personale esperienza conferma che la tecnica di dacriocistorinostomia endoscopica con approccio posteriore al sacco lacrimale senza l'utilizzo di stent o flap mucosi è una valida ed efficace alternativa chirurgica rispetto ad altre tecniche correntemente utilizzate.

PAROLE CHIAVE: Dacriocistorinostomia • DCR • Epifora • Endoscopia • Sacco lacrimale • Approccio posteriore • Stent • Flap mucoso • Chirurgia endoscopica

Acta Otorhinolaryngol Ital 2013;33:324-328

Introduction

Dacryocystorhinostomy (DCR) is a surgical procedure aimed, most commonly, at the relief of chronic epiphora, frequently observed in cases of chronic dacryocystitis and in patients with lacrimal sac or nasolacrimal duct (NLD) obstruction. Historically, ophthalmologists used an external approach (ex-DCR) for the relief of symptoms, with good results¹. This procedure, however, required some facial skin incisions and was not free of complications, such as disruption of the canthal ligaments with a consequent lacrimal pump dysfunction. The initial descriptions of an intranasal approach started to appear about a century

ago. The first to describe this latter technique theoretically were Caldwell, West and Mosher²⁻⁴. More recently, the first modern endoscopic endonasal procedure was described by McDonogh and Miering in 1989⁵. In recent years, with the development of new surgical instruments, treatment has evolved, and nowadays an endonasal endoscopic technique is the approach of choice in most cases. The principle on which the DCR procedure is based is the creation of a stoma between the medial wall of the lacrimal sac and nasal cavity. Multiple approaches to the sac and several technique modifications have been described for endoscopic dacryocystorhinostomy (en-DCR), the most frequent being the use of mucosal flaps, silicon st-

ents and peristomal injection of antimetabolites⁶⁻⁸. Our study reports the results of a 75 case cohort, treated by end-DCR using a posterior lacrimal sac approach as described by Metson, although without tube insertion⁹⁻¹¹. The scope of this report is to demonstrate that our technique offers comparable results, and thus is a valid alternative to other, similar endoscopic procedures.

Materials and methods

Patients

After approval by the Ethics Committee, a retrospective data review was performed on a group of patients that underwent endoscopic DCRs for acquired nasolacrimal duct obstruction between January 2007 and August 2011 (minimum follow-up: 1 year) in the ORL University Clinics of Pavia and Padua (Italy). This work updates the results of an oral presentation presented at the ERS & ISIAN Congress in Geneva in June 2010. Both centres applied a uniform policy for the management of nasolacrimal obstruction. The preoperative studies included: an accurate ophthalmological study, including probing of the lacrimal pathway and a lacrimal irrigation examination (through Jones I and II tests), an endoscopic endonasal evaluation and a computed tomography (CT) scan of the paranasal sinuses. Dacryocystography was usually not obtained, since nearly all patients had a previous examination by an expert ophthalmologist of our team to confirm the diagnosis. Patients with canalicular or common canalicular obstruction (pre-saccul stenosis) were excluded.

Operative technique

In all patients, surgery was performed after informed consent under general anesthesia in a slightly reversed Tren-

delenburg position (30°). Upon intubation we performed a decongestion of the nasal mucosa with pledgets soaked in xylometazoline hydrochloride 0.1% + oxybuprocaine chlorhydrate 0.01% solution and injection of 1% lidocaine with 1:100,000 epinephrine at the level of the head of the middle turbinate and the lateral nasal wall. When septal or middle turbinate anatomical variants blocking access to the lacrimal sac were present, such as deviations/spurs or concha bullosa, they underwent correction as the initial step; standard endoscopic sinus surgery was performed in cases of concomitant chronic rhinosinusitis or nasal polyposis. The projection of the lacrimal sac on the lateral nasal wall corresponds to the region of axilla of the middle turbinate. In cases of a prominent agger nasi cell covering the lacrimal sac (Fig. 1), the former was opened with cutting instruments (Fig. 2). Another important anatomical detail is the insertion of the uncinete process on the lateral nasal wall as detected on the CT scan; in particular, we observed two main cases: an anterior insertion along the frontal process of the maxillary bone/ventral lacrimal bone, and a posterior one along the dorsal part of the lacrimal bone. In the first case, an uncinectomy should precede the approach to the lacrimal fossa and sac; in the second case, the sac may be opened without an associated uncinectomy. Intraoperative localization of the lacrimal sac was enhanced by transillumination of the latter from a 20-gauge light pipe inserted (Karl Storz, Tuttlingen, Germany) through the inferior canaliculus and endoscopically detected on the lateral nasal wall. After successful exposure of the lacrimal bone, we proceeded with its removal using a diamond burr. Drilling was performed directly on the postero-medial wall of the lacrimal bone, in a medial to lateral direction, as the bony shell at

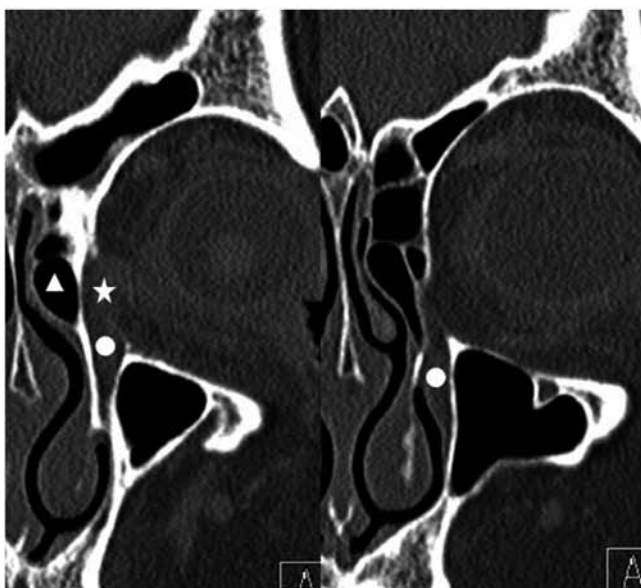

Fig. 1. Coronal CT scans (sequence) showing the relation between agger nasi (white triangle), lacrimal sac (white star) and nasolacrimal duct (white circle).

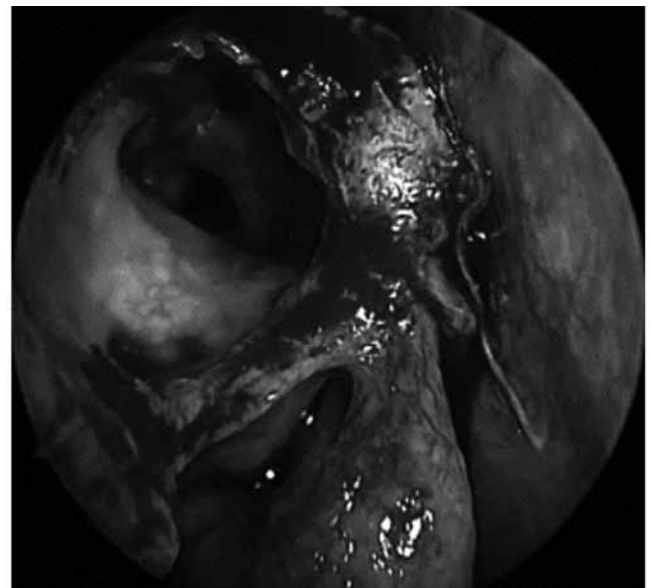


Fig. 2. Intraoperative pictures of a right-side agger nasi cell.

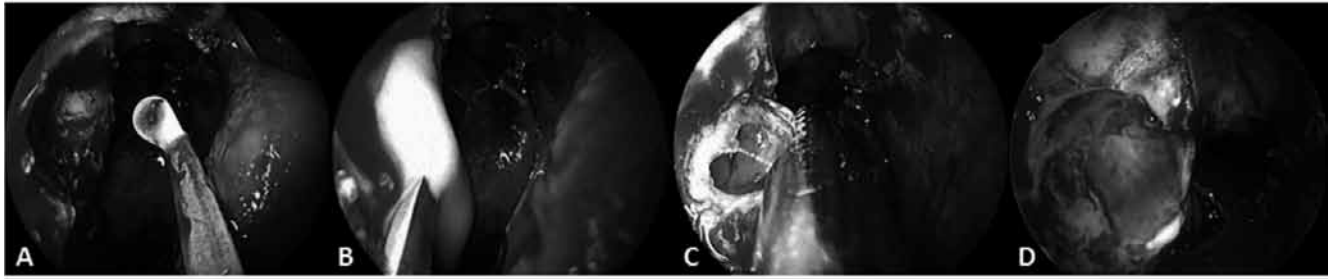


Fig. 3. Intraoperative sequence of a right-side endoscopic DCR: exposition of the lacrimal sac on the lateral nasal wall (A); incision of the medial wall of the latter with a round knife and the subsequent drainage of mucopurulent exudate (B); calibration of the stoma with microdebriders (C); dacryo-cysto-rhino-stoma at the end of surgery (D).

this point is thinner than its anterior part (Fig. 3). The lacrimal bone should be drilled until complete and adequate exposition of the lacrimal sac is obtained. Upon exposition, the sac was identified and its medial wall was put in tension by a probe inserted through the inferior canaliculus; the latter wall was then incised with a beaver, a sickle knife or the angled cutting forceps recently proposed by P. Castelnovo (Karl Storz, Tuttlingen, Germany). Subsequently, under both 0° and 45° scopes, a calibration of the dacryo-cysto-rhino-stomy was performed using microdebriders or cutting forceps, thus creating an ample dacryo-cysto-rhino-stoma (Fig. 4A). As a final step, the patency of the lacrimal pathways was checked with several saline irrigations. Nasal packing was performed only in cases of associated sinus surgery or septoplasty.

Postoperative care

Patients were usually discharged the day after treatment, and in cases of concomitant sinus surgery or septoplasty after two or three days postoperatively. All patients received broad-spectrum antibiotic therapy for one week after surgery. Topical nasal steroids were initiated some days after surgery and were prescribed for one month. Saline irrigations were recommended until the nasal mucosa was completely healed. The first endoscopic consultation was performed one week postoperatively, along with lacrimal irrigation. Subsequent endoscopic medications were performed at one, three, and six months and one year after surgery (Fig. 4B). Postoperative ophthalmologic evaluation performed at six months and one year included lacrimal irrigation, fluorescein dye disappearance test and Jones test I.

Results

The group consisted of 75 patients, 53 females (70.7%) and 22 males (29.7%) with a mean age of 58.2 years (range 25-84 years). Most patients reported epiphora as a result of chronic dacryocystitis, but we also observed cases of recurrent dacryocystitis and dacryocystocele. All patients included in this study had post-saccal or saccal stenosis of the lacrimal pathways. In three patients (4%), surgery was performed bilaterally; thus we performed a total of 78

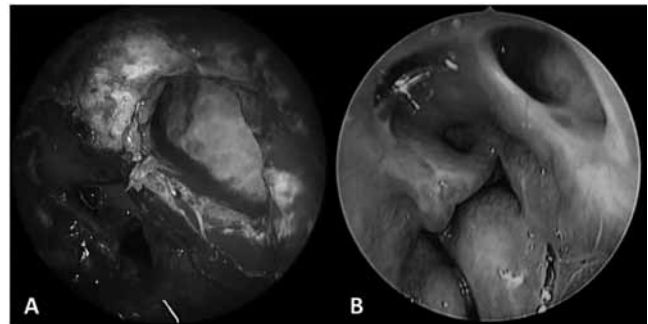


Fig. 4. (A) Surgical view of the left lacrimal sac's stoma at the end of the procedure. (B) Endoscopic postoperative control after six months showing a patent left lacrimal stoma.

DCRs. Within the cohort, 11 patients (14.7%) presented a positive medical history for previous surgery or facial trauma. To obtain correct access to the lacrimal fossa, we performed two septoplasties (2.7%) and 12 middle turbinate reductions (16%). Eight patients required additional endoscopic surgery to treat chronic rhinosinusitis or nasal polyposis (10.7%). No major intra- or post-surgical complications were observed. Follow-up ranged between 12 and 56 months (mean 25.7 months). Four patients (5.3%) developed a clinically asymptomatic synechia between the middle turbinate and the lateral nasal wall. We observed five cases of DCR-failure due to rhino-stomal scarring stenosis (6.7%), confirmed by ophthalmologic evaluation (positive fluorescein disappearance test and negative Jones I test). These patients successfully underwent revision endoscopic surgery (minimum follow-up 12 months). Finally, our success rate was 93.3% after endoscopic DCR.

Discussion

Historically, dacryocystorhinostomy is surgical procedure aimed at the restoration of patency of the lacrimal pathways through an external approach, as proposed by Toti and also described by Dupuy and Dutemps and Bourget^{1 6 12}. It is usually aimed at the relief of epiphora, the main symptom in most cases of chronic dacryocystitis, and on occasion with obstruction of the lacrimal sac or duct. In 1893, Caldwell was the first to suggest an intranasal approach to re-

store patency of the lacrimal pathways, followed by West and Mosher, who described a possible intranasal procedure to address lacrimal obstruction²⁻⁴. Subsequently, the first clinical study on an endoscopic DCR technique appeared in 1989 by McDonogh and Meiring⁵. In recent years, and along with the success of endoscopic sinus surgery, endoscopic DCR has proven to be a valid alternative to external approaches, as shown by many authors¹²⁻¹⁸. Disadvantages of external dacryocystorhinostomy include scarring of facial skin, risk of copious haemorrhage, and disruption of medial canthal anatomy. On the other hand, the main advantages of endoscopic techniques are the enhanced visualization through straight and angled scopes and the avoidance of unnecessary skin incisions, thus avoiding any functional damage to the orbicularis muscle.

Adequate selection of patients is a key point to obtain a good outcome rate: accurate ophthalmologic examination should be performed to distinguish between saccal, pre-saccal and post-saccal stenosis of the lacrimal pathways. CT scan is mandatory to show the anatomy and the variations of key structures such as the agger nasi and the uncinat process (Figs 1, 3)¹⁹. The success rate of the endonasal endoscopic approach, as reported in recent studies, is between 58% and 97%, which are lower than rates with external DCR (75-99%)^{7 12 13 15}. The most common cause of surgical failure in the former approach is a rhino-stomal stenosis¹³. In our personal experience, the success rate of endoscopic DCR (93.3%) falls within the range reported in the literature.

Within the endoscopic DCR group, there is much discussion in the literature today about technical details that may influence the functional results, incidence of complications and, finally, the rate of surgical failures. Among the most discussed are: surgical instrumentation²⁰, silicon tube stenting, use of mucosal flaps and peri-stomal injection of antimetabolites, such as mitomycin C. The ultimate objective of those technical variations is the patency of the new lacrimal drainage pathway and prevention of an eventual restenosis, and thus recurrence of symptoms. In a recent study, Naraghi et al. evidenced that the simple "punch technique", with the use of punch forceps for performing rhinostomy, preserves the advantages of endoscopic DCR while diminishing the expenses of powered or laser instrumentation with comparable results: they reported a 95% success rate on 100 cases of endoscopic DCRs²¹. Despite

the popularity of silicon stents, few studies have addressed this issue and described how it correlates with the surgical outcome. Allen, in 1989, highlighted that the use of silicon stents may increase the risk of surgical failure by stimulation of a peri-stomal granulomatous reaction²². More recently, other authors have agreed with Allen about stent utilization^{14 23-27}; however, some included a mucosal flap creation in their technique. The rationale of the mucosal flap is to boost primary intention healing and create a well-designed epithelialized surgical fistula. Recently, Khalifa et al. conducted the first prospective randomized controlled trial to compare the safety and efficacy of endoscopic DCR with double posteriorly based nasal and lacrimal flaps to conventional endoscopic DCR in adult patients; they concluded that the flap technique has a comparable success rate, operative time and safety profile, with a possibly better healing profile in terms of mucosal recovery, wound healing and less need for debridement²⁸. Moreover, there is insufficient evidence for the efficacy of mitomycin C or other antimetabolites in endoscopic DCR⁷. In fact, the results reported in the literature are controversial: some authors consider the application of mitomycin C safe and successful for surgical outcome^{29 30}; on the other hand, according to other reports, it has no proven beneficial effect on the success rate of the surgery^{31 32}.

We propose a variation of the procedure initially proposed by Metson and recently reported by other authors through the creation of a stoma along the posterior portion of the lacrimal sac; the theoretical basis of this proposal depends on the thickness of this bony portion, which is much thinner than its anterior counterpart¹⁵⁻¹⁷. Our variation, unlike Metson's technique, is based on the lack of lacrimal stenting. Based on the results of our experience, we propose posterior endoscopic DCR with no stent application as an alternative to other successful endoscopic approaches and with a comparable rate of complications and failures.

Conclusions

The posterior lacrimal sac approach technique without application of lacrimal stents for endoscopic DCR has been demonstrated to be a valid alternative to other endoscopic procedures. We observed an elevated high success rate in selected patients that is directly comparable to other

endoscopic techniques, even without the use of mucosal flap, lacrimal stent or topical postoperative administration of mitomycin C. The keys to a successful surgical outcome are adequate selection of patients, meticulous study of sinonasal anatomy and good experience in endoscopic sinus surgery.

Table 1. Demographic data and clinical features of patients.

Number of patients	75 pts (53 females; 22 males)
Age range	25-84 years (mean 58.2 years)
Positive medical history for previous surgery or facial trauma	11 pts (14.7%)
Septoplasties	2 pts (2.7%)
Middle turbinate reduction	12 pts (16%)
Endoscopic sinus surgery for CRS or NP	8 pts (10.7%)
Follow-up	12-56 months (mean 25.7 months)
Success rate of surgery	93.3%

References

- 1 Toti A. *Nuovo metodo conservatore di cura radicale delle suppurazioni croniche del sacco lacrimale*. Clin Med 1904;10:385-9.
- 2 Caldwell GW. *Two new operation for obstruction of the nasal duct, with preservation of canaliculi, and an incidental description of a new lacrymal probe*. N York M J 1983;57:581.
- 3 West JM. *A Window resection of the nasal duct in cases of stenosis*. Trans Am Ophthalmol Soc 1910;12:654-8.
- 4 Mosher HP. *Mosher-Toti operation on lacrimal sac*. Laryngoscope 1921;31:284.
- 5 McDonogh M, Meiring JH. *Endoscopic transnasal dacryocystorhinostomy*. J Laryngol Otol 1989;103:585-7.
- 6 Watkins LM, Janfaza P, Rubin PA. *The evolution of endonasal dacryocystorhinostomy*. Surv Ophthalmol 2003;48:73-84.
- 7 Leong SC, Macewen CJ, White PS. *A systematic review of outcomes after dacryocystorhinostomy in adults*. Am J Rhinol Allergy 2010;24:81-90.
- 8 Apuhan T, Yıldırım YS, Eroglu F, Sipahier A. *Effect of mitomycin C on endoscopic dacryocystorhinostomy*. J Craniofac Surg 2011;22:2057-9.
- 9 Metson R. *The endoscopic approach for revision dacryocystorhinostomy*. Laryngoscope 1990;100:1344-7.
- 10 Metson R. *Endoscopic surgery for lacrimal obstruction*. Otolaryngol Head Neck Surg 1991;104:473-9.
- 11 Metson R. *Endoscopic dacryocystorhinostomy-An update in techniques*. Otolaryngol Head Neck Surg 1995;6:217-20.
- 12 Codère F, Denton P, Corona J. *Endonasal dacryocystorhinostomy: a modified technique with preservation of the nasal and lacrimal mucosa*. Ophthal Plast Reconstr Surg 2010;26:161-4.
- 13 Kansu L, Aydin E, Avci S, et al. *Comparison of surgical outcomes of endonasal dacryocystorhinostomy with or without mucosal flaps*. Auris Nasus Larynx 2009;36:555-9.
- 14 Unlu HH, Gunhan K, Baser EF, et al. *Long-term results in endoscopic dacryocystorhinostomy: is intubation really required?* Otolaryngol Head Neck Surg 2009;140:589-95.
- 15 Ramakrishnan VR, Hink EM, Durairaj VD, et al. *Outcomes after endoscopic dacryocystorhinostomy without mucosal flap preservation*. Am J Rhinol 2007 21:753-7.
- 16 Lee KC. *Outcomes of posterior lacrimal sac approach in endoscopic dacryocystorhinostomy: review of 35 cases*. Am J Rhinol 2008;22:210-3.
- 17 Saratziotis A, Emanuelli E, Gouveris H, et al. *Endoscopic dacryocystorhinostomy for acquired nasolacrimal duct obstruction: creating a window with a drill without use of mucosal flaps*. Acta Otolaryngol 2009;129:992-5.
- 18 Pittore B, Tan N, Salis G, et al. *Endoscopic transnasal dacryocystorhinostomy without stenting: results in 64 consecutive procedures*. Acta Otorhinolaryngol Ital 2010;30:294-8.
- 19 Soyka MB, Treumann T, Schlegel CT. *The Agger Nasi cell and uncinat process, the keys to proper access to the nasolacrimal drainage system*. Rhinology 2010;48:364-7.
- 20 Nuhoglu F, Gurbuz B, Eltutar K. *Long-term outcomes after transcanalicular laser dacryocystorhinostomy*. Acta Otorhinolaryngol Ital 2012;32:258-62.
- 21 Naraghi M, Tabatabaie Mohammadi SZ, Sontou AF, et al. *Endonasal endoscopic dacryocystorhinostomy: how to achieve optimal results with simple punch technique*. Eur Arch Otorhinolaryngol 2012;269:1445-9.
- 22 Allen K, Berlin AJ. *Dacryocystorhinostomy failure: association with nasolacrimal silicone intubation*. Ophthalmic Surg 1989;20:486-9.
- 23 Smirnov G, Tuomilehto H, Teräsvirta M, Nuutinen J, Seppä J. *Silicone tubing after endoscopic dacryocystorhinostomy: is it necessary?* Am J Rhinol 2006;20:600-2.
- 24 Smirnov G, Tuomilehto H, Teräsvirta M, et al. *Silicone tubing is not necessary after primary endoscopic dacryocystorhinostomy: a prospective randomized study*. Am J Rhinol 2008;22:214-7.
- 25 Saeed BM. *Endoscopic DCR without stents: clinical guidelines and procedure*. Eur Arch Otorhinolaryngol 2012;269:545-9.
- 26 Callejas CA, Tewfik MA, Wormald PJ. *Powered endoscopic dacryocystorhinostomy with selective stenting*. Laryngoscope 2010;120:1449-52.
- 27 Al-Qahtani AS. *Primary endoscopic dacryocystorhinostomy with or without silicone tubing: a prospective randomized study*. Am J Rhinol Allergy 2012;26:332-4.
- 28 Khalifa MA, Ragab SM, Saafan ME, et al. *Endoscopic dacryocystorhinostomy with double posteriorly based nasal and lacrimal flaps: a prospective randomized controlled trial*. Otolaryngol Head Neck Surg 2012;147:782-7.
- 29 Dolmetsch AM. *Nonlaser endoscopic endonasal dacryocystorhinostomy with adjunctive mitomycin C in nasolacrimal duct obstruction in adults*. Ophthalmology 2010;117:1037-40.
- 30 Özkiris M, Özkiris A. *Endoscopic dacryocystorhinostomy not using canalicular silicone intubation tube with and without mitomycin C: a comparative study*. Eur J Ophthalmol 2012;22:320-5.
- 31 Zilelioğlu G, Uğurbaş SH, Anadolu Y, et al. *Adjunctive use of mitomycin C on endoscopic lacrimal surgery*. Br J Ophthalmol 1998;82:63-6.
- 32 Eshraghy B, Raygan F, Tabatabaie SZ, et al. *Effect of mitomycin C on success rate in dacryocystorhinostomy with silicone tube intubation and improper flaps*. Eur J Ophthalmol 2012;22:326-9.

Received: September 24, 2012 - Accepted: March 6, 2013

Address for correspondence: Fabio Pagella, Department of Otorhinolaryngology, University of Pavia and Foundation IRCCS Policlinico "San Matteo", viale Golgi 19, 27100 Pavia, Italy. Tel. +39 0382 526218. Fax +39 0382 528184. E-mail: tpagella@libero.it