

Long ureteric stricture replacement by buccal mucosa graft: an Armenian experience case series report

Arman Tsaturyan¹, Kristina Akopyan², Arthur Levonyan¹, Ashot Tsaturyan¹

¹Clinic of Urology, "Kanakaner – Zeytun" Medical Center, Armenia

²Center for Health Services Research and Development, School of Public Health, American University of Armenia

Citation: Tsaturyan A, Akopyan K, Levonyan A, Tsaturyan A. Long ureteric stricture replacement by buccal mucosa graft: an Armenian experience case series report Cent European J Urol. 2016; 69: 217-220.

Article history

Submitted: Dec. 18, 2015

Accepted: March 24, 2016

Published online: April 14, 2016

Corresponding author

Arman Tsaturyan
Clinic of Urology
"Kanakaner – Zeytun"
Medical Center
V. Papazyan 32
0012 Yerevan, Armenia
phone: +37 494 016 339
tsaturyanarman@yahoo.com

Introduction The aim of this study is to demonstrate the results of a case series concerning the replacement of long ureteric strictures using buccal mucosa grafts.

Material and methods Five patients (3 men, 2 women), with a mean age of 35 years old, underwent reconstructive ureteral surgery using buccal mucosa graft with omental wrapping during the period of 2010–2013. In all cases, the location of strictures was in the proximal ureters with the length of strictures varying from 2.5 to 5.0 cm.

Results We did not observe any major complications postoperatively. Two patients complained of constipation, which was resolved on the second day without any special treatment. Only one patient experienced fever (39°C) on the seventh day after the surgery due to inadequate drainage of the nephrostomic tube. Mean follow-up time was 39.6 months (range 26–52 months), mean hospital stay length was 10.6 days. Intravenous and antegrade urography were performed after removing JJ stents. Results were favorable without any signs of stricture. Repetitive ultrasound and radiologic imaging was performed at month 3, 6, 12 in the first year and every half-year thereafter. Intravenous urography showed no signs of strictures. Hydronephrosis was resolved in all patients by the sixth month following the surgery.

Conclusions Postoperatively, we observed favorable results in all patients in terms of absence of short term-surgical complications. This technique could be considered for patients with long ureteric strictures in whom ureteral replacement with bowel interposition or kidney auto-transplantation is contraindicated.

Key Words: ureteric strictures ↔ buccal mucosa grafting ↔ ureteroplasty

INTRODUCTION

Many conditions, both malignant and benign, can lead to the development of ureteral strictures. In cases where strictures are too long, it may not be reasonable to use treatment options such as excision, end-to-end anastomosis, ureterocystoneostomy, kidney mobilization, trasoureteroureterostomy, psoas-hitch or Boari flaps. More complex surgeries such as ureteric replacement with bowel interposition and kidney auto-transplantation might be required [1, 2]. These surgeries are associated with specific complications and require highly qualified surgical teams [1–4].

According to Armatys et al. the rate of short term complications for ureteric replacement with bowel interposition was 42.9%, including severe complications such as small bowel obstruction, myocardial infarction, acute renal failure, respiratory failure, wound infection and wound dehiscence [5]. In contrast, complications following kidney transplantation are vascular related and include innervation related and infection related complications.

This leaves space for exploration of safer surgical techniques to improve treatment outcomes. One of these techniques is ureteric replacement using buccal mucosa graft (BMG) proposed by Naude et al. [1, 2, 3, 6–9].

The aim of this study is to complement the limited research on applying ureteric replacement using buccal mucosa grafts in patients with ureteral strictures.

MATERIAL AND METHODS

In total, five patients underwent reconstructive ureteral surgery using buccal mucosa graft with omental wrapping in the period from November 2010 to January 2013. The mean age was 35 years old (from 26 to 45). In all the cases, the location of the stricture was in the proximal ureter with the length of the stricture varying from 2.5 to 5.0 cm.

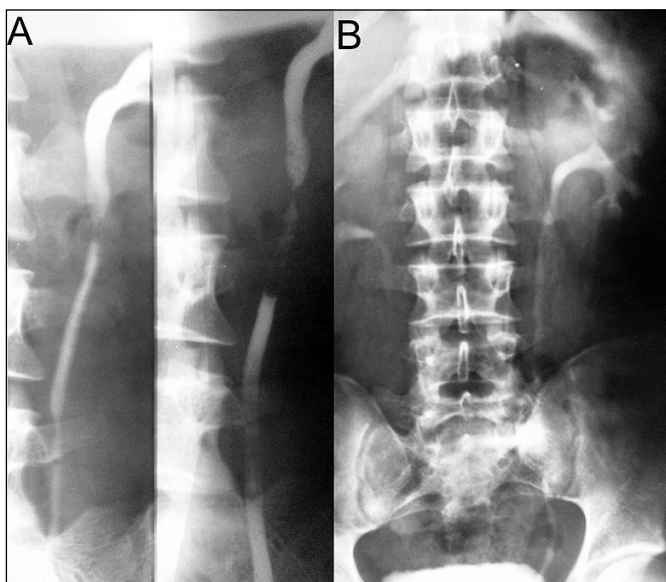


Figure 1. A radiogram of antegrade urography of a patient before (A) and after the surgery (B).

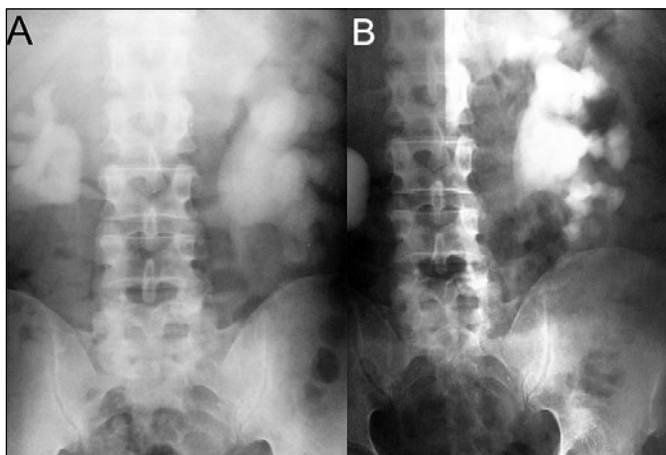


Figure 2. A radiogram of antegrade urography of a patient before (A) and a month after the surgery (B) with reduced hydronephrosis.

The cause of the stricture was knife injury (1 case), prior gynecological surgery (1 case), prior inter-abdominal surgery (1 case) and prior pyeloplasty (2 cases) (Table 1). The patient with knife injury had presented to the clinic with a nephrostomic tube, the remaining cases has hydronephrosis. For the diagnosis we used CT, intravenous and antegrade urography for all the cases (see available media in Figures 1, 2). For the assessment of complications, the Clavien complications grading system was used [10]. No patients were eligible to other surgical techniques due to the medical contraindications or the length of ureteric strictures. In addition, all patients were informed about the treatment options and gave their consent for it.

We used common surgical techniques for all the patients. The operating team performed the surgery under general anesthesia using nasal intubation.

We harvested the BMG from the inner cheek (length of 2–3 cm) using techniques described by Naude et al. The patients were then placed in the lateral lumbar position and an extraperitoneal approach was performed accessing the affected site of the ureter. We identified the sites of strictures and cut them in their entire length. A double J stent was placed into all ureters. The harvested mucosa grafts were laid down on the incised ureters and sutured into position using 4/0 polyglactin sutures. We mobilized the omentum in each case and wrapped it around the reconstructed site of the ureter. After meticulous hemostasis, the wound and urinary bladder were drained with an 18 Fr. latex tube and an 18 Fr. Foley catheter, respectively. The catheter was removed on the second day postoperatively. The drain was removed if no leakage from it was observed (mean duration was three days). Postoperatively we administered intravenous ceftriaxone for three days to every patient followed by ciprofloxacin (oral intake) for seven days. We removed the double J stents after four weeks.

RESULTS

No major complications (Clavien grade I and II) were observed postoperatively. Two patients complained of constipation, which was resolved on the second day without any special treatment. Only one patient experienced fever (38.7°C) on the seventh day after the surgery due to inadequate drainage of the nephrostomic tube. After administration of antipyretic treatment, the fever was reduced on the same day.

Mean hospital stay length was 10.6 days (range 10–12 days) and follow-up time was 39.6 months.

The team performed intravenous and antegrade urography after removing DJ stents. Results were favorable without any signs of stricture. Thereafter,

being sure that the drainage from the kidney was established, percutaneous nephrostomy of patient No.1 was removed. Repetitive ultrasound and radiologic imaging was performed at the third, sixth and twelfth months and every half-year thereafter. Hydronephrosis was resolved in four patients by the sixth month following the surgery. In one patient residual dilatation was observed on ultrasound during the entire follow-up period, however, it was without any radiographic or clinical signs. Intravenous urography showed no signs of strictures. In contrast, in three out of five patients, the stricture site was dilated on urography, which probably could be explained by the fact that buccal mucosa lacks a muscular layer.

DISCUSSION

Reconstructive surgery of extended ureteric strictures is still a hard task for urologists. While short

strictures may be treated using easier procedures, long ureteral strictures require more difficult techniques that subsequently carry an increased risk of morbidity and mortality. The use of BMG for treatment of long ureteric strictures was first described by Naude in 1999, in a case series report of 6 patients [4]. Thereafter, only a few articles have been published describing this technique in a case series of patients (Table 2). BMG has long been described for the treatment of long urethral strictures and is currently one of the best treatment modalities nowadays [2, 11, 12]. It has become the first choice treatment carrying 96% success rates among all free graft tissues [2].

The use of BMG for ureteral replacement is an easy procedure avoiding complications associated with bowel interposition and kidney auto-transplantation [2, 10]. Thick elastin-rich, hairless epithelium of buccal mucosa makes it more resistant to infections and sclerosing conditions. In addition, the healing of the

Table 1. Patients' characteristics, follow-up and complications

Patient No	Sex	Age	Length (cm)	Cause	Follow up months	Early complications (in-hospital)
1	M	26	4	Knife injury	52	Fever 38.7°C
2	F	38	5	Prior pyeloplasty	36	No
3	M	45	2.5	Intraabdominal surgery	47	Constipation
4	F	28	5	Removal of ovarian cyst	26	Constipation
5	M	38	4.5	Prior pyeloplasty	37	No

Table 2. Summary of publications utilizing similar techniques

Author year	N of patients	Type of the graft	Mean (Range) length of the stricture in cm	Developed complications	Follow-up in months	Additional procedure required in follow-up	Favorable outcome at the end of the follow up n/N	Time to relapse
Trapeznikova et al., 2014	8	"On lay"	5.1 (3.5–6.0)	No	3–72	Stone formation 6 months later – URS ³ (1 patient) Nephrectomy 1.5 years later (1 patient)	8/9 (88.9%)	6 months (1 patient)
Sadhu et al., 2011	1	"On lay"	8	No	6	None	1/1 (100%)	No relapse
Badawy et al., 2010	5	Tabularized	4.4 (3.5–5.0)	Fever 39°C (1 patient) Ileus for 2 days (1 patient)	14–39	None	5/5 (100%)	No relapse
Agrawal et al., 2010	1	"On lay"	7	No	3	None	1/1 (100%)	No relapse
Kroepf et al., 2009	6 (7) ¹	"On lay"	6.86 (3–11)	No	18–85 months	None	5/7 (71.4%)	17 months (1 patient) 39 months (1 patient)
Shah et al., 2003	5	"On lay"	7.5 (5.5–9.0)	No	12	None	4/5 (80%)	No relapse
Naude J.H. 1999	6	"On lay", Tabularized ²	N/A	No	3–72	None	6/6 (100%)	No relapse

¹One of the patients had 2 strictures, in total 7 grafting were done; ²In five patients "on lay" and in one patient tabularized graft; ³URS – ureterorenoscopy

donor site is fast and is associated with low morbidity and complications [2, 10]. Thin but highly vasculature lamina propria of the graft plus an abundant vasculature bed (wrapped omentum) provide ideal take-up conditions for the graft.

We started applying ureteral replacement with BMG after the successful outcome of our first patient who had had a knife injury of bowels and ureter, and in whom ureteral replacement with bowel interposition or kidney auto-transplantation was impossible because of extensive adhesions and sclerosis. Further literature revision showed favorable results of ureteral replacement with BMG, and we applied this technique to other patients who were not eligible to other surgeries due to the medical contraindications or long ureteric strictures.

The results of our study are comparable with the results of the few previously published articles [1, 3, 4, 6, 9, 10, 12]. All patients had satisfactory outcome after surgery during the follow-up period. No major

complications occurred in the postoperative period, thus resembling the results of previous case series. This case series report could not demonstrate the effectiveness of the technique due to the limited number of cases, retrospective nature of the study and short follow-up period. However, it gives strong ground to conduct further prospective research to assess effectiveness and appropriateness of the technique. In addition, the favorable outcomes are aligned with the results of previous reports, meaning that this technique could be explored as a treatment option, especially in those patients who are ineligible or unwilling to undergo complex surgical options.

CONFLICTS OF INTEREST

The authors declare no conflicts of interest.

ACKNOWLEDGMENTS

The authors would like to thank entire operating team of Clinic of Urology, "Kanaker – Zeytun" Medical Center, Armenia.

References

- Kroepfl D, Loewen H, Klevecká V, Musch M. Treatment of long ureteric strictures with buccal mucosal grafts. *BJU Int.* 2010; 105: 1452-1455.
- Badawy AA, Abolyosr A, Saleem MD, Abuzeid AM. Buccal mucosa graft for ureteral stricture substitution: initial experience. *Urology.* 2010; 76: 971-975.
- Naude JH. Buccal mucosal grafts in the treatment of ureteric lesions. *BJU Int.* 1999; 83: 751-754.
- Milonas D, Stirbys S, Jievaltas M. Successful treatment of upper ureteral injury using renal autotransplantation. *Medicina.* 2009; 45: 988-991.
- Armatys SA, Mellon MJ, Beck SD, Koch MO, Foster RS, Bihrlé R. Use of ileum as ureteral replacement in urological reconstruction. *J Urol.* 2009; 181: 177-181.
- Trapeznikova MF, Bazaev VV, Shibaev AN, Luk'ianchikov AG, Vinogradov AV. [Replacement plastic reconstruction of extended ureteral stricture using buccal mucosa autograft]. *Urologiia.* 2014; 2: 16-19.
- Agrawal V, Dassi V, Andankar MG. Buccal mucosal graft onlay repair for a ureteric ischemic injury following a pyeloplasty. *Indian J Urol.* 2010; 26: 120-122.
- Sadhu S, Pandit K, Roy MK, Bajoria SK. Buccal mucosa ureteroplasty for the treatment of complex ureteric injury. *Indian J Urol.* 2011; 73: 71-72.
- Shah SA, Ranka P, Visnagara M, Dodia S, Jain R. Use of buccal mucosa as onlay graft technique for benign ureteric strictures. *Indian J Urol.* 2003; 20: 28-32.
- Dindo D, Demartines N, Clavien PA. Classification of surgical complications: a new proposal with evaluation in a cohort of 6336 patients and results of a survey. *Ann Surg.* 2004; 240: 205-213.
- Singh A, Panda SS, Bajpai M, Jana M, Baidya DK. Our experience, technique and long-term outcomes in the management of posterior urethral strictures. *J Pediatr Urol.* 2014; 10: 40-44.
- Hoy NY, Kinnaird A, Rourke KF. Expanded use of a dorsal onlay augmented anastomotic urethroplasty with buccal mucosa for long segment bulbar urethral strictures: analysis of outcomes and complications. *Urology.* 2013; 81: 1357-1361. ■