

Circumferential-Surrounding (“Sandwich”) Meniscal Repair: A Salvage Technique to Save the Meniscus



Eduard Alentorn-Geli, M.D., M.Sc., Ph.D., F.E.B.O.T., F.A.C.G.M.E., Xavier Cuscó, M.D., Jordi Navarro, R.N., Roberto Seijas, M.D., Ph.D., David Barastegui, M.D., M.Sc., Ph.D., Gonzalo Samitier, M.D., Ph.D., F.E.B.O.T., Gilbert Steinbacher, M.D., Pedro Álvarez-Díaz, M.D., Ph.D., Jorge Ramírez, M.D., D.O., and Ramón Cugat, M.D., Ph.D.

Abstract: Meniscal injuries are extremely common in the general and athletic populations. The management strategy has switched from meniscectomy to meniscal-preserving techniques. It is nowadays extensively accepted that surgeons have to do their best to repair the meniscus and try to preserve as much tissue as possible. However, in many cases the tissue quality is poor and the tear pattern is complex. In such scenarios, meniscal repair has a lower success rate. In the present surgical technique, an arthroscopic all-inside circumferential-surrounding meniscal repair technique is presented. Any meniscal tissue or the meniscal rim is first debrided to a bleeding bed. Then, an all-inside device is used to create vertical sutures from capsule to capsule surrounding the entire meniscus (circumferential-surrounding). Care should be taken not to tighten the suture too much to avoid cutting the meniscal tissue. This easy and effective repair technique “packs” the meniscal tear fragments altogether and allows the surgeon to save the meniscus when facing with irreparable, degenerative, complex meniscus tears.

Meniscal injuries are extremely common in the general and athletic populations. Patient's age, activity level, meniscal tissue quality, tear pattern, and tear location are among most commonly involved factors to decide on conservative or surgical treatment. The management strategy when surgical treatment is recommended has switched from meniscectomy to meniscal-preserving techniques over the years. It is nowadays extensively accepted that surgeons have to

do their best to repair the meniscus and try to preserve as much tissue as possible.¹ This is because of the potential negative long-term impact on the articular cartilage (i.e., development of osteoarthritis) when meniscal tissue is removed. However, in many cases of poor meniscal tissue quality and complex tear patterns, the achievement of a stable repair technique with high success rate is not possible with standard repair techniques or configurations. The purpose of this Technical Note is to present an all-arthroscopic, all-inside meniscal repair technique able to save the meniscus in the most challenging scenarios.

Surgical Technique (With Video Illustration)

Intradural anesthesia typically is performed in all cases, and then a femoral or sciatic nerve block is added depending on the need for associated procedures (i.e., concomitant ligament reconstruction or osteotomy). The patient is placed in the supine position with the knee extended on the operating table for isolated meniscal injuries, or with the knee flexed and the leg and foot hanging over the end of the bed for cases in which associated procedures will be performed. The operative extremity is prepared and draped in the usual fashion for routine knee arthroscopy. The procedure is performed using a standard 30° arthroscope. The anterolateral portal is first created and a systematized

From the Instituto Cugat (E.A.-G., X.C., J.N., R.S., D.B., G.Sa., G.St., P.A.-D., R.C.); Fundación García Cugat (E.A.-G., X.C., J.N., R.S., G.Sa., G.St.); Mutuallitat de Futbolistas Españoles - Delegación Cataluña, Federación Española de Fútbol (E.A.-G., D.B., G.St., P.A.-D., J.R., R.C.); and Universitat Internacional de Catalunya, Sant Cugat del Vallès (R.S., D.B., P.A.-D., R.C.), Barcelona, Spain.

The authors report the following potential conflicts of interest or sources of funding: Smith & Nephew and BTI have made donations to Fundación García Cugat. Full ICMJE author disclosure forms are available for this article online, as [supplementary material](#).

Received March 30, 2020; accepted June 5, 2020.

Address correspondence to Ramón Cugat Bertomeu, M.D., Ph.D., Fundación García Cugat, Plaza Alfonso Comín 5, Planta -1, 08023 Barcelona, Spain. E-mail: calentornngeli@gmail.com

© 2020 by the Arthroscopy Association of North America. Published by Elsevier. This is an open access article under the CC BY-NC-ND license (<http://creativecommons.org/licenses/by-nc-nd/4.0/>).

2212-6287/20468

<https://doi.org/10.1016/j.eats.2020.06.008>

diagnostic arthroscopy is performed in the following sequence: suprapatellar pouch, patellofemoral joint, medial gutter, medial tibiofemoral compartment, intercondylar area, posteromedial compartment, lateral tibiofemoral compartment, and lateral gutter including popliteal hiatus. Then, the anteromedial portal is created to introduce the probe and palpate intraarticular structures: cartilage consistency, cruciate ligaments, and both menisci. Before undergoing the final meniscal procedure, the posterolateral compartment is inspected with the arthroscope in the anteromedial portal. The examination of both posterior compartments is necessary to completely evaluate the meniscal tear pattern and rule out meniscal or cartilage loose bodies.

Once the meniscal tear pattern has been precisely assessed, a decision on the type of meniscal repair is needed. If the surgeon determines that the regular meniscal repair configuration with sutures through the meniscal tissue is not possible, then the circumferential-surrounding technique is indicated. The first step is to assure an adequate quality of the capsule where meniscal sutures will be attached. This can be achieved with the probe, although sometimes one realizes about the poor capsule quality with the first all-inside meniscal repair because the anchor does not attach into the capsule. In cases of inappropriate tissue or in the rare situations in which the capsule is torn, the placement of the circumferential-surrounding sutures has to be adapted accordingly. In these circumstances (poor capsular tissue), achieving a strong repair should be a priority even if the sutures are not placed in the most adequate location for the tear location or pattern. In general, problems with the capsule tissue quality are uncommon. The next step is to debride the edges of any of the meniscal tear segments in the red–white or red–red zones and the meniscal rim to create a bleeding and healing bed. This can be achieved with either the shaver with extreme care to avoid meniscal tissue damage or removal, or by using a meniscal rasp (Fig 1). If the meniscal tissue is of too poor quality or the segment is too thin, meniscal edge debridement is not recommended. We use the all-inside FAST-FIX (Smith & Nephew, Andover, MA) device, but the technique can be performed with any other all-inside meniscal repair device or even with the inside-out or outside-in techniques.

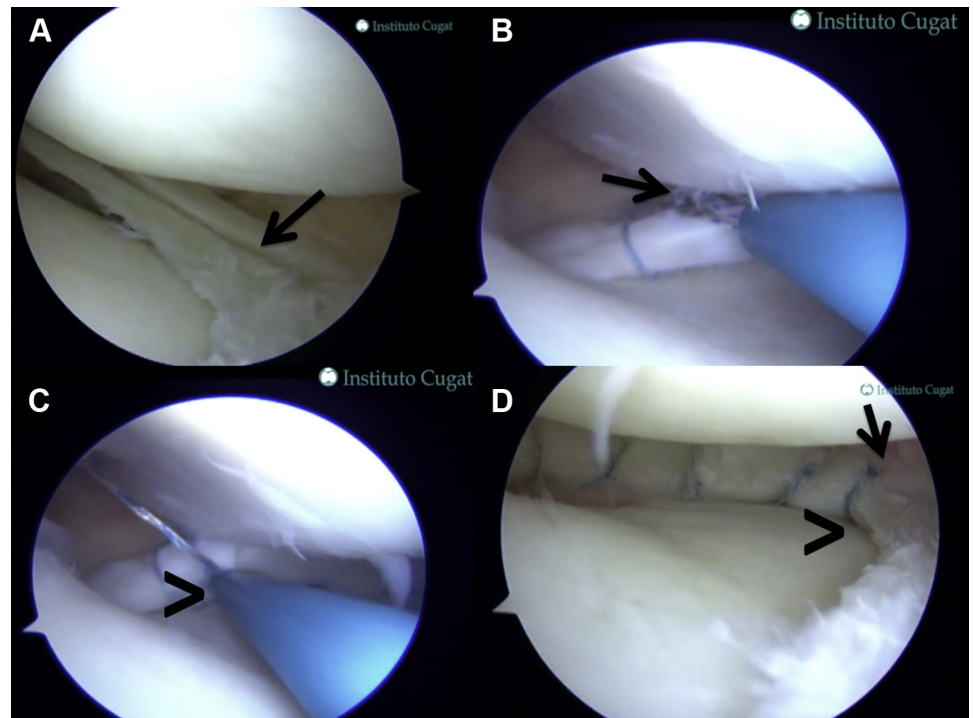
For tears affecting the posterior half of the body or the posterior horn, a first stitch is placed in the capsule right above the meniscus. It is important to feel the capsule when it is penetrated to realize about its ability to hold the meniscus sutures. Once the anchor is deployed, a second one is placed in the capsule just inferior to the meniscus and circumferentially surrounding the meniscus tear segment/s. Before tightening the suture, a probe is helpful to position the meniscal torn segments in the desired position and then a final tightening is performed. If a “bucket-handle” meniscal tear is faced, it is helpful

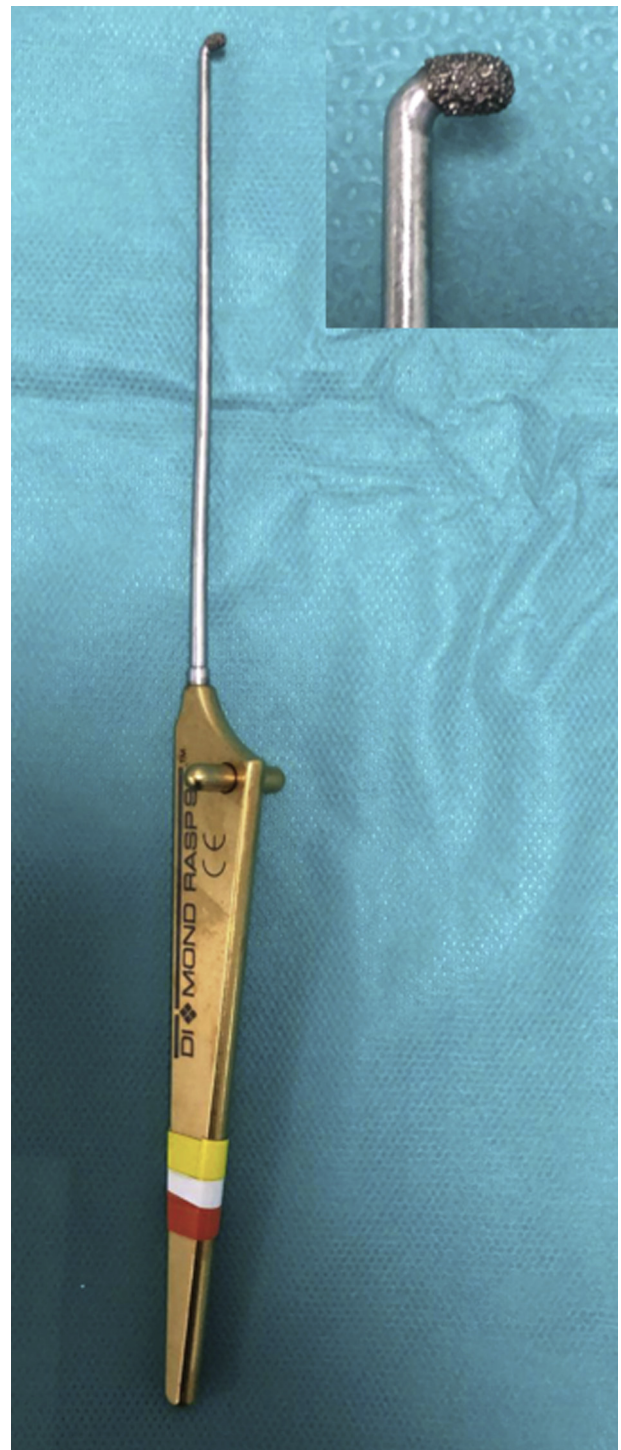

Fig 1. The ACUFEX meniscal diamond rasp (Smith & Nephew, Andover, MA).

that this first suture is placed in the corner between the posterior horn and the body of the meniscus. The shape of the meniscus is typically modified because the torn segments are “packed” together. The same procedure is repeated until no unstable meniscal segments are observed (Figs 2 and 3; Video 1).

Fig 2. Circumferential-surrounding meniscal repair technique. (A) Arthroscopic view from the anterolateral portal of a lateral meniscus of a left knee showing a vertical longitudinal tear (black arrow) affecting the white zone (A). (B) Arthroscopic view from the anterolateral portal of a medial meniscus of the right knee demonstrating the deployment of the first anchor of the FAST-FIX (Smith & Nephew, Andover, MA) all-inside meniscal repair device in the capsule above the meniscus (black arrow). (C) Arthroscopic view from the anterolateral portal of a medial meniscus of the right knee demonstrating the deployment of the second anchor of the FAST-FIX all-inside meniscal repair device in the capsule below the meniscus (black arrowhead). (D) Arthroscopic view from the anterolateral portal of a lateral meniscus of a left knee showing the final aspect of the meniscal repair with the meniscal suture to the capsule from above the meniscus (black arrow) all the way around the meniscus to the capsule below the meniscal tissue (black arrowhead).



For tears affecting the anterior half of the body or the anterior horn, the circumferential-surrounding technique is performed using an outside-in technique. The same principles are applied: careful evaluation of the capsular tissue and tear pattern, and preparation of an adequate bleeding bed and bleeding meniscal tear edges, if applicable. Then, a standard outside-in technique for meniscal repair is performed ([Video 1](#)). First, a thin needle is placed from the outside to mark the entry point perpendicular to the meniscus and flush and parallel to the joint line so that the meniscal shape is not modified when tightening. Then, a spinal or “Tuohy” needle is inserted also perpendicular to the meniscus and parallel to the inferior surface at the same level of the lower one. Then, a small skin incision is made and the initial thin needle is changed by a second spinal or “Tuohy” needle that will follow the same track. Once the needles are in the desired location, a size 0 absorbable PDS suture (Ethicon, Somerville, NJ) is placed in each needle and brought outside the joint through the “working” portal with a grasping device. The PDS

suture (Ethicon) is used as a transport suture to bring a 2/0 ULTRABRAID (Smith & Nephew) inside the joint and through the meniscal tear. Then a subcutaneous knot is made, and the procedure repeated for as much sutures as needed. The circumferential-surrounding meniscal repair has to be performed as the first procedure in cases where associated ligament reconstruction or osteotomy are needed. [Table 1](#) summarizes the step-by-step technique.

Discussion

The present article describes an easy and helpful technique to repair and preserve the meniscus in cases in which regular meniscal repair is not possible because of poor meniscal tissue quality and/or tear pattern. This method creates circumferential-surrounding sutures (“sandwich”-like construct) around the entire meniscus perimeter from the capsule above the meniscus to the capsule below the meniscus, thus “packing” the meniscal tear segments altogether. Despite the technique changes the normal shape of the meniscus free

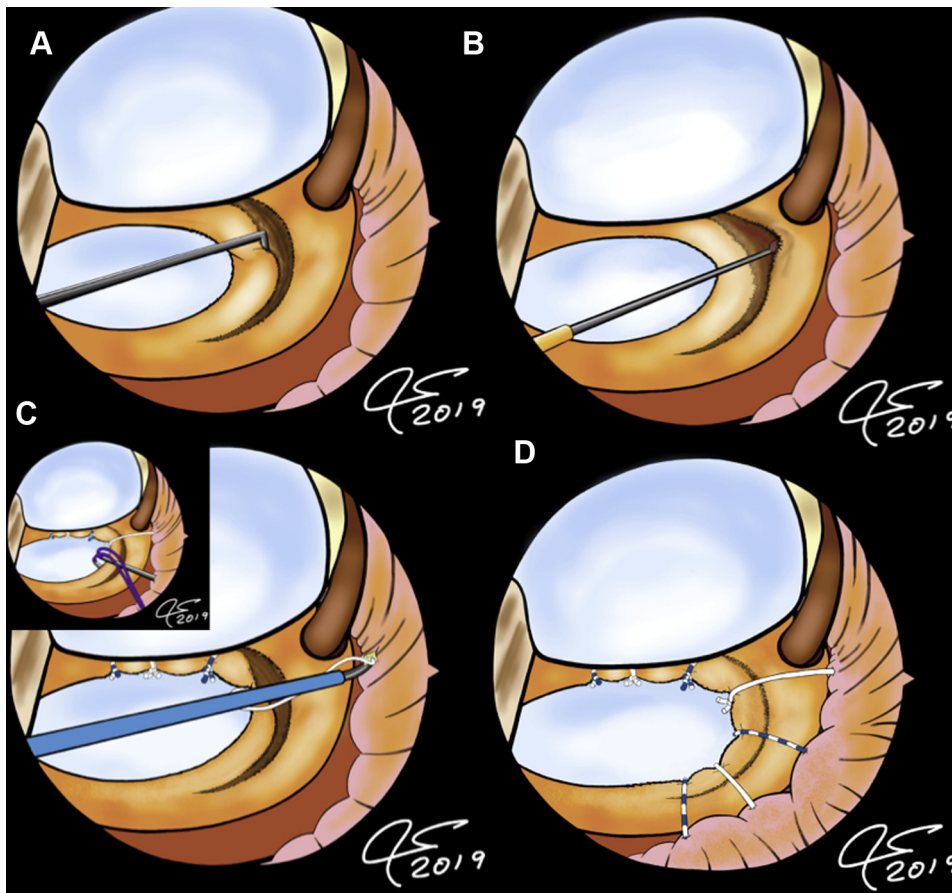


Fig 3. Illustration of the circumferential-surrounding meniscal repair technique. The repair begins with a careful evaluation of the tear pattern with the probe (A), followed by a preparation of the meniscal rim to a bleeding bed using the ACUFEX meniscal diamond rasp (Smith & Nephew) or a 4.5-mm shaver (B). Then the circumferential-surrounding technique is applied using both all-inside devices (as described in Fig 2) (C) and the outside-in technique (D), as needed taking into account the size of meniscal tear.

edge and requires a competent joint capsule, it allows the surgeon to save the meniscus when facing with irreparable meniscal tears.

There has been in the recent years an increase in the number of editorials written by well-known experts advising against meniscectomy and asking for a paradigm change toward saving the meniscus.¹⁻³ Moreover, since 2010 there has been an International Meniscus Meeting held every 3 years in which saving the meniscus has been a persistent request. It is well known that total or even partial meniscectomy results in radiographic evidence of knee osteoarthritis.⁴ In fact, it has been shown that meniscal repair does better than partial meniscectomy with long follow-up periods.⁵ Therefore, it is nowadays widely accepted that surgeons must make all efforts to preserve the meniscus tissue and try to repair over-resection,⁶ so a solution for irreparable meniscal tears is warranted.

The circumferential-surrounding meniscal repair is indicated in cases in which there is a vertical longitudinal tear within the white or red–white zones, double vertical longitudinal, horizontal cleavage, pedunculated, combined complex meniscal tears with

degenerated tissue, thin and/or poorly vascularized segments affected, absence of radial components, and competent joint capsule to which the suture can be attached. In these circumstances, regular through-the-meniscus repair is typically not possible because the meniscal tissue breaks as the suture is tighten. Because the circumferential-surrounding suture configuration is perpendicular to the longitudinal circumferential meniscal collagen fibers, if follows the same direction as radial tears and the repair technique is not therefore adequate for these injuries. However, in combined patterns, one may perform the circumferential-surrounding technique and then perform a trimming of the radial component.

The technique is not without risk of complications (Table 2). However, many of these risks are inherent to the arthroscopic meniscal repair rather than the presented technique itself.⁷ The risk of damaging the posterior neurovascular bundle is particularly concerning for tears of the lateral meniscus close to the posterior root.⁸ Massey et al.⁸ observed that this risk was especially high if the repair was being performed at 5 mm from the posterior root of the lateral meniscus and

Table 1. Summary of Key Points of the Surgical Technique

Step-By-Step Technique	Description of the Steps
Step 1: Definition of tear pattern and adequacy for the circumferential-surrounding meniscal repair technique	<p>Visualization: arthroscope in anterolateral portal.</p> <p>Instruments: probe from the anteromedial portal.</p> <p>Technique: the meniscal tear has to be defined in terms of tear size, stability of segments, location with respect to the meniscus area (posterior horn, body, and anterior horn) and vascularity zone (red-red, red-white, or white), and number of tear “lines.”</p>
Step 2: Evaluation of joint capsule	<p>Visualization: arthroscope in anterolateral portal or anteromedial portal as needed.</p> <p>Instruments: probe from the “working” portal.</p> <p>Technique: the joint capsule is palpated with the probe to assure a good holding strength when meniscal sutures are placed through. If the probe easily penetrates the capsule or it is obviously broken, the area cannot be used for the circumferential-surrounding repair.</p>
Step 3: Debridement of the meniscal tear edges to a bleeding bed, if applicable	<p>Visualization: arthroscope in anterolateral portal or anteromedial portal as needed.</p> <p>Instruments: meniscal rasp or shaver from the “working” portal.</p> <p>Technique: a meniscal rasp or shaver is used in any tear segment that can be debrided to a bleeding bed. If the tear size is thin or clearly away from any bleeding zone, this is not recommended to avoid damage of the meniscal tissue.</p>
Step 4: Meniscal repair	<p>Visualization: arthroscope in anterolateral portal or anteromedial portal as needed.</p> <p>Instruments: FAST-FIX (Smith & Nephew) for tears of the posterior horn or posterior half of the body, or “Tuohy” needles, 0 PDS suture (Ethicon, Somerville, NJ) and 2/0 ULTRABRAID (Smith & Nephew) for tears of the anterior half of the body and anterior horn.</p> <p>Technique:</p> <ul style="list-style-type: none"> • Tears of the posterior horn or posterior half of the body: All-inside circumferential-surrounding meniscal repair technique. First anchor deployed above the meniscus in the joint capsule, and the second one below the meniscus and perpendicular to it, going all the way around the perimeter of the meniscus. The probe is used before tightening to assure adequate meniscal tissue position. • Tear of the anterior half of the body or anterior horn: outside-in technique. Two “Tuohy” needles are used to pass a 0 PDS (Ethicon) transport suture that will be used to bring a 2/0 ULTRABRAID (Smith & Nephew) suture to secure the meniscus through a subcutaneous knot. The suture has to be placed perpendicular to the meniscus, and both the upper and lower needles have to be parallel to the joint line.
Step 5: Final check of stability of the repair	<p>Visualization: arthroscope in the anterolateral portal.</p> <p>Instruments: probe through the “working” portal.</p> <p>Technique: the probe is used to palpate all the meniscal repair area and rule-out unstable segments. If needed, additional sutures have to be placed until the meniscal tear area is all “packed” together.</p>

through the anterolateral portal. The authors observed that the repair was safer if it was 10 mm away from the root and performed through the anteromedial or transpatellar portal.⁸ Therefore, the most central suture of the posterior horn of the lateral meniscus should be performed through these portals and be as far away as possible, but as close as needed, to the posterior root. Another potential pitfall to highlight is the risk of meniscus free-edge cut-off when tightening the sutures. It is important to avoid over-tensioning the sutures and use a probe to create a small folding of the meniscal free edge so that the chances of cutting off through the tissue are decreased (Fig 2; Table 2). Table 2 summarizes some technical tips to avoid or decrease the risk of complications.

The technique has some potential disadvantages (Table 3), and there is no short-, mid-, and long-term clinical outcomes nor comparative studies with partial meniscectomy yet. However, it allows the surgeon to save the meniscus in irreparable meniscal tears and provide a stable meniscus with a great chance of healing by packing the tear segments together.

Conclusions

The circumferential-surrounding (“sandwich”) meniscal repair technique may be a good option for irreparable tears to save the meniscus in young and active individuals.

Table 2. Potential Pitfalls/Risks and Recommended Solutions for the Surgical Technique

Pitfalls/Risks	Solutions
Damage of articular cartilage in tight knees	<ul style="list-style-type: none"> • Percutaneous medial collateral ligament release for medial compartment. • Leg-holding device to optimize the varus-producing force for the lateral compartment.
Damage of meniscal tissue during examination or preparation for repair	<ul style="list-style-type: none"> • Careful creation of portals (using as many portals as needed for an optimum meniscal repair angle) and avoidance of extra-articular fluid extravasation. • Avoid forceful palpation maneuvers with the probe (meniscal tissue may strip off if it is very degenerated). • Debride meniscal tear edges to create a bleeding bed only if the tear line is in the red–white or red zones (potential for bleeding). • Debride meniscal tear edges to create a bleeding bed only if the meniscal segment is of enough thickness (typically more than 5 mm). • Use specific meniscal rasps instead of shaver. • If specific rasps are not available, the shaver should be used without suction to avoid meniscal tissue removal. • Use the shaver only if the compartment opens adequately (excessive pressure on the shaver to get into the tight space may create sudden joint penetration that can damage the meniscus or the cartilage). • Use the shaver discontinuously over the meniscal tissue (i.e., using a “biting” technique more than in a continuous manner).
Joint capsule damage during meniscal repair	<ul style="list-style-type: none"> • Assure that the all-inside device has completely penetrated the capsule and deployed the anchor before removing it (avoid unnecessary and excessive capsular tissue penetration maneuvers). • Use capsular zones with a better appearance and consistency during Step 2 (Table 1).
Damage of posterior neurovascular structures when performing meniscal repair close to the posterior roots (particularly for the lateral meniscus)	<ul style="list-style-type: none"> • The meniscal repair of zones close to the root should be performed with slightly more knee flexion to increase the distance between the meniscus and the posterior neurovascular structures. • Assure the popliteal fossa is not inadvertently compressed by any leg holders, padding, surgical table, or the assistant’s hand (the posterior neurovascular structures may be pushed toward the working area). • Grasp the all-inside meniscal repair devices with a finger in contact with the skin before penetrating the capsule (the finger will serve as a stop to prevent posterior overpenetration of the capsule). • Use the anteromedial or transpatellar portals as you get close to the posterior root when repairing the posterior horn of the lateral meniscus.
Meniscal free-edge cut-off by the sutures	<ul style="list-style-type: none"> • If the posterior meniscal area is repaired using an inside-out technique, have skilled assistance, adequate direct visualization, and use appropriate protectors before the needle comes out from the joint in the posterior aspect of the knee. • Before final tightening of the suture, use a probe to control the final position of the free edge. Ideally, the free edge should be folded so that the suture does not cut-off through the meniscal tissue.
Knot irritation or sensitive nerve complications in the outside-in technique for the anterior half of the body and anterior horn meniscal repairs	<ul style="list-style-type: none"> • Limit the number of subcutaneous knots to 3. • Use a low-profile and small-diameter suture (a 2/0 ULTRABRAID, Smith & Nephew, Andover, MA, is recommended). • Perform careful blunt dissection in the subcutaneous tissue with a hemostat and visually inspect for any obvious sensitive nerve branches before final knot tying.

Table 3. Advantages and Disadvantages of the Surgical Technique

Advantages	Disadvantages
Allows the surgeon to save the meniscus in irreparable meniscal tears (except radial tears).	Changes the normal shape of the meniscus.
Provides a stable meniscus by packing the tear segments together.	Requires a competent joint capsule. Suture may cut off the meniscal tissue if quality is very poor and/or excessive tension is applied when the knot is tied.

References

1. Seil R, Becker R. Time for a paradigm change in meniscal repair: Save the meniscus! *Knee Surg Sports Traumatol Arthrosc* 2016;24:1421-1423.
2. Lubowitz JH, Poehling GG. Save the meniscus. *Arthroscopy* 2011;27:301-302.
3. Pujol N, Beaufils P. Save the meniscus again! *Knee Surg Sports Traumatol Arthrosc* 2019;27:341-342.
4. Petty CA, Lubowitz JH. Does arthroscopic partial meniscectomy result in knee osteoarthritis? A systematic review with a minimum of 8 years' follow-up. *Arthroscopy* 2011;27:419-424.
5. Lee WQ, Gan JZ, Lie DTT. Save the meniscus—Clinical outcomes of meniscectomy versus meniscal repair. *J Orthop Surg (Hong Kong)* 2019;27:2309499019849813.
6. Beaufils P, Pujol N. Management of traumatic meniscal tear and degenerative meniscal lesions. Save the meniscus. *Orthop Traumatol Surg Res* 2017;103:S237-S244.
7. Austin KS, Sherman OH. Complications of arthroscopic meniscal repair. *Am J Sports Med* 1993;21:864-868. discussion 868-869.
8. Massey P, Parker D, Feibel B, Ogden A, Robinson J, Barton RS. Proximity of the neurovascular bundle during posterior-lateral meniscal repair: A comparison of the transpatellar, anteromedial, and anterolateral portals. *Arthroscopy* 2019;35:1557-1564.