

Endoscopic Treatment of an Idiopathic Pancreaticopleural Fistula

João Correia^a Rolando Pinho^a Elsa Francisco^b Luísa Proença^a
Carlos Fernandes^a Manuel Oliveira^b

^aGastroenterology and Hepatology Department, Centro Hospitalar de Vila Nova de Gaia/Espinho EPE, Vila Nova de Gaia, Portugal; ^bGeneral Surgery Department, Centro Hospitalar de Vila Nova de Gaia/Espinho EPE, Vila Nova de Gaia, Portugal

Keywords

Pancreas · Endoscopic retrograde cholangiopancreatography · Pseudocyst · Pleural effusion

Abstract

A 61-year-old man was diagnosed with an exudative pleural effusion with raised amylase and bilirubin levels. The patient had no previous history of acute pancreatitis or trauma and no clinical or radiological signs of chronic pancreatitis. On thoracoabdominal computed tomography, a pancreatic pseudocyst with a pancreaticopleural fistula was identified. Endoscopic retrograde cholangiopancreatography identified a ductal disruption site in the body of the pancreas. Pancreatic sphincterotomy and stent placement in the duct of Wirsung, combined with medical management, allowed fistula closure, pseudocyst reabsorption, and no relapse of the pleural effusion. The relevance of this case lies not only in its rarity but also as it highlights the importance of a multidisciplinary approach in such uncommon conditions. Optimal management of this condition is debatable due to the absence of prospective studies comparing medical, endoscopic, and surgical approaches.

© 2021 Sociedade Portuguesa de Gastrenterologia
Published by S. Karger AG, Basel

Tratamento endoscópico de uma fístula pancreatopleural idiopática

Palavras Chave

Pâncreas · Colangiopancreatografia retrógrada endoscópica · Pseudoquisto · Derrame pleural

Resumo

Um homem de 61 anos foi diagnosticado com um derrame pleural exsudativo com níveis elevados de amilase e bilirrubina. O doente não apresentava história prévia de pancreatite aguda, trauma ou sinais e sintomas de pancreatite crónica. Na tomografia computadorizada toracoabdominal, foi identificado um pseudoquisto pancreático com uma fístula pancreatopleural. A colangiopancreatografia retrógrada endoscópica identificou um ponto de disrupção ductal no corpo do pâncreas, pelo que se optou pela realização de esfínterectomia pancreática e colocação de uma prótese plástica no ducto de Wirsung. Esta abordagem, combinada com o tratamento médico, permitiu o encerramento da fístula e resolução do derrame pleural, bem como reabsorção do pseudoquisto pancreático. A relevância deste caso reside não só

na sua raridade, mas também porque destaca a importância de uma abordagem multidisciplinar para otimizar o tratamento. Dada a infrequência desta condição clínica, não existem estudos prospectivos que comparem as abordagens médica, endoscópica e cirúrgica.

© 2021 Sociedade Portuguesa de Gastrenterologia
Publicado por S. Karger AG, Basel

Introduction

Pancreatic pseudocysts are fluid, homogeneous, and encapsulated collections [1] that may occur a few weeks after an episode of acute pancreatitis, on chronic pancreatitis due to an acute exacerbation or ductal disruption, and, more rarely, due to ductal disruption secondary to trauma [2].

In 4.5% of the cases, generally in the setting of chronic pancreatitis, these collections give rise to fistulous tracts to the pleural cavity, causing an exudative pleural effusion [3].

Case Description

A 61-year-old man was admitted to the emergency department with an insidious history of shortness of breath, malaise, loss of weight (7 kg), and anorexia in the previous 6 weeks. He denied chest pain, cough, fever, abdominal pain, or diarrhea. Past medical conditions included arterial hypertension, diabetes mellitus type 2, and dyslipidemia. Chronic medications included acetylsalicylic acid, valsartan, atorvastatin, and metformin. He denied smoking and reported an alcohol intake of 20 g a week. He denied past history of acute pancreatitis or trauma and his family history was irrelevant.

On physical examination, his vital signs were stable and he had no signs of respiratory distress. On pulmonary evaluation, the patient exhibited dullness to percussion and absent breath sounds on the left hemithorax. Blood studies were unremarkable. Chest radiograph showed hypotransparency of the whole left hemithorax (Fig. 1).

These findings were compatible with a pleural effusion of unknown etiology, causing respiratory distress. After a diagnostic and therapeutic thoracocentesis, the patient was discharged and a medical re-evaluation was scheduled to the following week.

One week later, the patient was feeling well. Laboratory results regarding pleural fluid analysis revealed an exudate, with a raise on amylase (2,070 U/L) and bilirubin (6.2 mg/dL) levels and low levels of triglycerides and adenosine deaminase. Cytology of the fluid was negative for malignant cells.

In light of these findings, a thoracoabdominal computed tomography (CT) was performed, revealing a homogeneous and fluid peripancreatic collection with a well-defined enhancing rim, close to the upper border of the pancreatic body, with a maximum diameter of 48 mm, which exhibited two fistulous tracts: one towards the spleen and another to the diaphragm (Fig. 2). No abnormalities were found on the pancreatic parenchyma, gallbladder, and bile ducts and there were no abdominopelvic adenopathies.

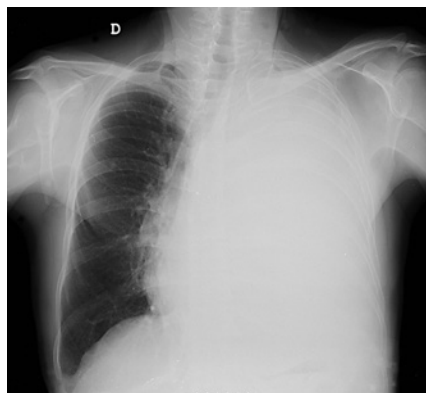


Fig. 1. Chest radiograph showing hypotransparency of the whole left hemithorax.

On abdominal magnetic resonance imaging (MRI), this collection showed no signs of suspicion, namely septations or mural nodules with enhancement, and no changes on the pancreatic parenchyma were identifiable, nor dilatation of the duct of Wirsung. The diagnosis of a pancreatic pseudocyst with a pancreaticopleural fistula (PPF) and a pancreaticosplenic fistula was made.

Four weeks later, the patient was readmitted to the emergency department with similar complaints, exhibiting a relapse of the pleural effusion on chest radiograph. After multidisciplinary discussion, conservative treatment with therapeutic thoracocentesis, octreotide, and an endoscopic retrograde cholangiopancreatography (ERCP) for Wirsung evaluation and pancreatic stenting was proposed.

On ERCP, the Wirsungogram identified a point of ductal leakage in the body of the pancreas, with contrast spreading to the middle of the column (most likely to the pseudocyst lumen) (Fig. 3). Pancreatic sphincterotomy and placement of a double-flanged straight 5-Fr plastic stent with 9 cm (the longest one available in the unit) in the duct of Wirsung, up to the ductal disruption site (Fig. 4), were performed.

Four months after discharge, the patient reported no relapse of the initial symptoms. An abdominal MRI was repeated, revealing an almost complete reabsorption of the collection, resolution of the fistulous tracts and no abnormalities on the pancreatic parenchyma or in the duct of Wirsung.

Elective ERCP was also undertaken to remove the pancreatic stent and to evaluate Wirsung patency, which had no signs of leakage after contrast injection (Fig. 5). A prophylactic short plastic stent was placed during 1 week, to diminish the risk of potential post-ERCP pancreatitis.

On a 5-month follow-up, the patient is feeling well, with no pleural effusion on chest radiograph.

Discussion

This report describes a case of an idiopathic pancreatic pseudocyst, complicated with a PPF and a pleural effusion. In fact, this patient had no history of trauma or

Fig. 2. Thoracoabdominal computed tomography showing a peripancreatic collection with a fistulous tract towards the spleen (right image, white arrow) and another to the diaphragm (left image, white arrow).

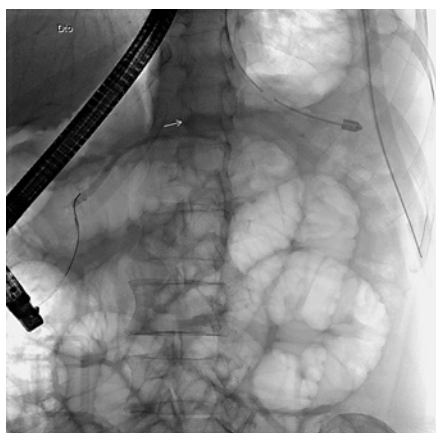
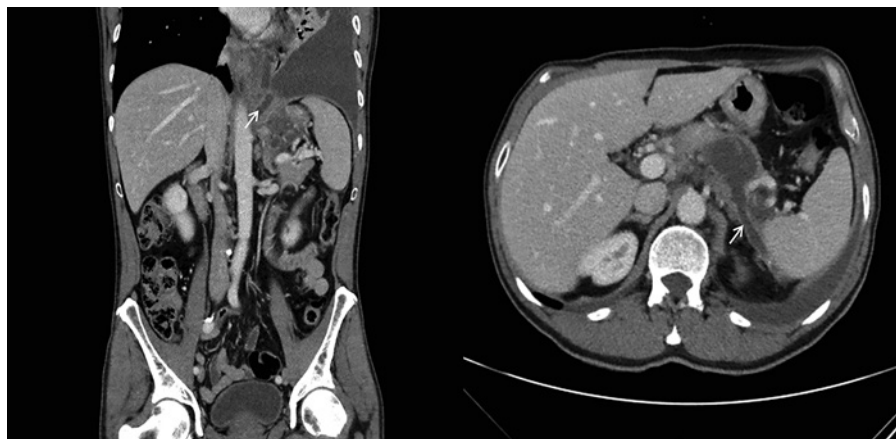


Fig. 3. Wirsungogram performed on the first endoscopic retrograde cholangiopancreatography, revealing a ductal leakage in the body of pancreas (white arrow).

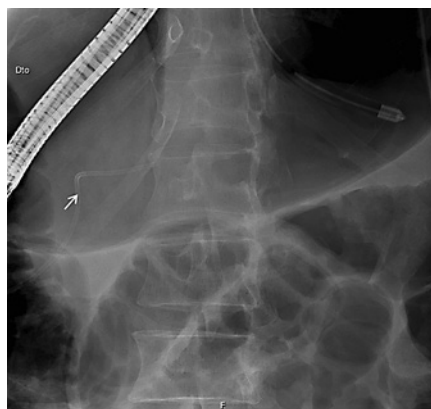

Fig. 4. Radiograph showing the pancreatic plastic stent after endoscopic retrograde cholangiopancreatography.

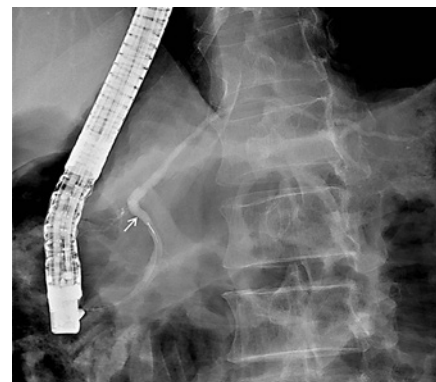

Fig. 5. Wirsungogram performed 4 months after pancreatic stenting, revealing no ductal disruption.

acute pancreatitis and did not have any known risk factors for chronic pancreatitis, nor pancreatic parenchyma alterations on MRI.

PPF is a very rare entity, thus optimal approach of this uncommon condition has not been evaluated in large studies [4].

Wronski et al. [5] have proposed an approach based on MRI findings. Medical management (thoracocentesis and somatostatin analogs to reduce the fistula output) is reserved for patients with no ductal alterations. Endoscopic management, with stent placement to bridge the ductal disruption site, and thus enabling closure of the fistula, is indicated for patients with ductal disruption in the head/body of the pancreatic or distal ductal stenosis. Cases of complete ductal disruption, proximal ductal ob-

struction, and failure of medical/endoscopic treatment should prompt for a surgical approach. Furthermore, relapse of the PPF is not infrequent, which also demands for surgical intervention [6].

In this case, ERCP identified a ductal disruption in the body of the pancreas. Pancreatic sphincterotomy and stent placement, combined with medical management, allowed fistula closure and no relapse of the pleural effusion, as well as reabsorption of the pancreatic pseudocyst. Few studies have reported optimal results with this more conservative approach, with resolution of the ductal disruption in almost every case, as the authors describe in this case report [7, 8]. However optimal duration of the stent placement is still controversial [9].

An important point to discuss on the diagnostic work-up of this patient was the absence of an endoscopic ultrasonography (EUS) to evaluate a fluid peripancreatic collection in a patient with no history of acute or chronic pancreatitis, trauma, and pancreatic surgery. Although the abovementioned imagiologic features were highly predictive of a pancreatic pseudocyst, EUS outperforms both CT and MRI in visualizing pancreatic cystic lesions and to distinguish between benign and malignant ones [10]. Cyst fluid sampled by EUS-guided fine needle aspiration could also aid on the differential diagnosis in this intriguing scenario [11].

The relevance of this case lies not only in its rarity but also as it highlights the importance of a multidisciplinary approach to optimize patient management.

References

- 1 Banks PA, Bollen TL, Dervenis C, Gooszen HG, Johnson CD, Sarr MG, et al.; Acute Pancreatitis Classification Working Group. Classification of acute pancreatitis—2012: revision of the Atlanta classification and definitions by international consensus. *Gut*. 2013 Jan;62(1):102–11.
- 2 Tan JH, Chin W, Shaikh AL, Zheng S. Pancreatic pseudocyst: dilemma of its recent management (Review) [Review]. *Exp Ther Med*. 2021 Feb;21(2):159–59.
- 3 Aswani Y, Hira P. Pancreaticopleural fistula: a review. *JOP*. 2015 Jan 31;16(1):90–4.
- 4 Tay CM, Chang SK. Diagnosis and management of pancreaticopleural fistula. *Singapore Med J*. 2013 Apr;54(4):190–4.
- 5 Wronski M, Slodkowski M, Cebulski W, Moronczyk D, Krasnodebski IW. Optimizing management of pancreaticopleural fistulas. *World J Gastroenterol*. 2011 Nov;17(42):4696–703.
- 6 King JC, Reber HA, Shiraga S, Hines OJ. Pancreatic-pleural fistula is best managed by early operative intervention. *Surgery*. 2010 Jan;147(1):154–9.
- 7 Khan AZ, Ching R, Morris-Stiff G, England R, Sherridan MB, Smith AM. Pleuropancreatic fistulae: specialist center management. *J Gastrointest Surg*. 2009 Feb;13(2):354–8.
- 8 Pai CG, Suvarna D, Bhat G. Endoscopic treatment as first-line therapy for pancreatic ascites and pleural effusion. *J Gastroenterol Hepatol*. 2009 Jul;24(7):1198–202.
- 9 Machado NO. Pancreaticopleural fistula: revisited. *Diagn Ther Endosc*. 2012;2012:815476–76.
- 10 Du C, Chai NL, Linghu EQ, Li HK, Sun LH, Jiang L, et al. Comparison of endoscopic ultrasound, computed tomography and magnetic resonance imaging in assessment of detailed structures of pancreatic cystic neoplasms. *World J Gastroenterol*. 2017 May;23(17):3184–92.
- 11 Muthusamy VR, Chandrasekhara V, Acosta RD, Bruining DH, Chathadi KV, Eloubeidi MA, et al.; ASGE Standards of Practice Committee. The role of endoscopy in the diagnosis and treatment of cystic pancreatic neoplasms. *Gastrointest Endosc*. 2016 Jul;84(1):1–9.

Statement of Ethics

Written informed consent was obtained from the patient for publication of this case report and accompanying images.

Conflict of Interest Statement

The authors have no conflicts of interest to declare.

Funding Sources

This work was not funded.