

Pulmonary Embolism Initially Misdiagnosed as Perimyocarditis in a Young Patient

Oguz Kilic, Alperen E. Akgun¹, Furkan Ufuk², Ipek Buber¹, Ismail D. Kilic¹

Department of Cardiology, Simav Doc. Dr. Ismail Karakuyu State Hospital, Kutahya, ¹Departments of Cardiology, and ²Radiology, Pamukkale University Hospitals, Denizli, Turkey

ABSTRACT

Pulmonary embolism is a common cardiovascular emergency. In case of delayed diagnosis and treatment morbidity and mortality is high. In this report, we presented a case of pulmonary embolism without apparent risk factors, which was initially misdiagnosed as peri/myocarditis.

Keywords: Electrocardiography, pericarditis, pulmonary embolism, ST elevation, troponin

Address for correspondence: Dr. Ismail D. Kilic, Department of Cardiology, Pamukkale University Hospitals, Denizli, Turkey.
E-mail: idogukilic@gmail.com

Submitted: 28-May-2020 **Revised:** 11-Oct-2020 **Accepted:** 16-Jan-2021 **Published:** 21-Jan-2022

INTRODUCTION

Acute chest pain is one of the most common presenting complaints to the emergency departments. The causes range from relatively benign to life-threatening conditions and include acute coronary syndromes (ACS), pulmonary embolism (PE), and pericarditis.^[1] Although the diagnosis can be made on the basis of thorough medical history, physical examination, electrocardiography (ECG), and simple laboratory variables in most patients, the diagnosis remains a challenge, particularly in patients without clear symptoms or specific ECG changes. On the other hand, misdiagnoses in patients with chest pain can lead to serious consequences for the patients and can be a substantial liability for the physician.^[2] In this report, we presented a case of PE without apparent risk factors, which was initially misdiagnosed as peri/myocarditis.

CASE REPORT

A 23--year-old male with no previous cardiac history presented with stabbing pain on the left side of his chest that was increasing with deep inspiration. He did not report any additional symptoms, including dyspnea or syncope. However, he had an upper respiratory tract infection (URTI) 2 weeks ago. Physical examination was unremarkable except for a scar of a previous workplace accident happened 3 years ago. Concave ST-segment elevation was present in the inferior and lateral leads, with ST-segment depression in aVR in the initial ECG [Figure 1]. Laboratory findings were within normal ranges apart from high troponin levels and increased white blood cells (14,000/mm³). Bedside echocardiography did not show any findings suggestive of PE, such as right heart dilatation or septal flattening. Considering the patients presentation, recent history of an URTI and ST-elevation pattern, patient was admitted with a diagnosis

Access this article online	
Quick Response Code:	Website: www.annals.in
	DOI: 10.4103/aca.ACA_121_20

This is an open access journal, and articles are distributed under the terms of the Creative Commons Attribution-NonCommercial-ShareAlike 4.0 License, which allows others to remix, tweak, and build upon the work non-commercially, as long as appropriate credit is given and the new creations are licensed under the identical terms.

For reprints contact: WKHLRPMedknow_reprints@wolterskluwer.com

How to cite this article: Kilic O, Akgun AE, Ufuk F, Buber I, Kilic ID. Pulmonary embolism initially misdiagnosed as perimyocarditis in a young patient. *Ann Card Anaesth* 2022;25:100-2.

of pericarditis. Increased troponin levels were suggestive of associated myocarditis. Cardiac magnetic resonance imaging was scheduled to confirm myocardial involvement. A non-steroidal anti-inflammatory drug (NSAID) was administered along with colchicine. However, troponin levels continued to increase (at admission: 0.346 ng/L, peak: 1.82 ng/L, cutoff: 0.014 ng/L), despite stable clinical status. At this point, a coronary angiogram was considered to exclude coronary artery disease (CAD), including coronary anomalies. However, taking patient's age into account and low probability of CAD, we proceeded with a coronary computed tomography angiography (CCTA) which showed massive thrombus in the right main pulmonary artery without any obstruction in the coronary arteries [Figures 2 and 3a]. NSAID and colchicine was stopped and low-molecular weight heparin was started. A screening for deep vein thrombosis, including subclavian veins was normal. Genetic analysis revealed a homogeneous MTHFR gene mutation. Other blood tests including lupus anticoagulants and homocysteine were normal. The patient was discharged on dabigatran 150 mg b.i.d. Patient was asymptomatic and the pulmonary computed tomography angiography was normal at the 3-month follow-up [Figure 3c].

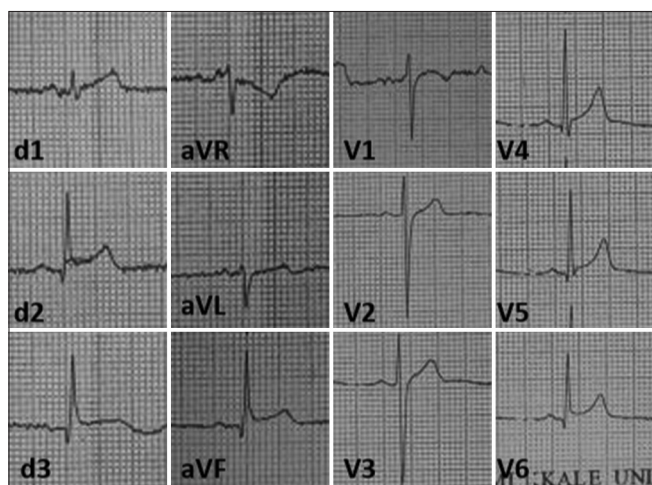


Figure 1: Concave ST-segment elevation was present in the inferior and lateral leads, with ST-segment depression in aVR in the initial ECG

DISCUSSION

PE is a common and potentially life-threatening condition. Despite the advances in diagnostic modalities, diagnosis of PE still remains a challenge. The presentation can vary widely. Although the “classical” presentation is abrupt onset of pleuritic chest pain, dyspnea, and hypoxia, clinical manifestation is not sensitive and specific in most patients and the combination of these findings are seen in less than 20% of the cases.^[3] In fact, previous studies showed delay and misdiagnosis in up to 50% of the PE cases.^[4]

ECG is one of the indispensable diagnostic tools in evaluating the patients with chest pain and dyspnea. Patients with PE may demonstrate a variety of electrocardiographic changes, including alterations in rate, rhythm, conduction, axis, and morphology^[5]; however, most of these alterations are non-specific, thus, their diagnostic value is limited. These alterations may be because of right ventricular overload, dilation, ischemia, and/or increased sympathetic activity.^[6] Most common finding on the ECG is sinus tachycardia. Other possible changes include, but not limited to, T-wave inversion in the right pre-cordial leads; an S1Q3T3 pattern; q waves in the inferior leads, complete, or incomplete right bundle-branch block.^[6,7] ST elevations are rarely present,^[5,8] however, if present, they are mostly seen in anteroseptal leads.^[9] The mechanism of ST-segment elevations are not clear, but suggested mechanisms include paradoxical coronary artery embolism via atrial septal defect or patent foramen ovale^[8] and right ventricular ischemia because of hypotension, hypoxemia, pulmonary artery hypertension, or catecholamine surge.^[10] Nevertheless, our patient demonstrated ST-elevations without clinical distress, hypoxia, or right heart dilatation. In addition, CCTA also excluded any thromboembolic obstruction.

In most cases, patients with acute pericarditis present with pleuritic chest pain. ECG usually shows widespread

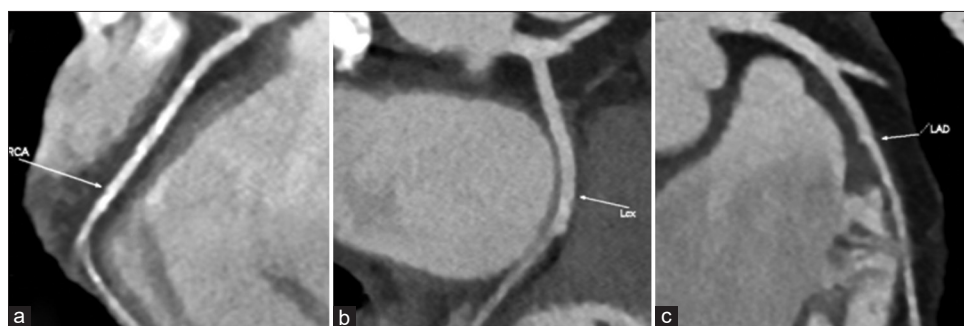


Figure 2: CT angiography shows unobstructed coronary arteries; (a) right coronary artery; (b) left circumflex coronary artery; (c) left anterior descending coronary artery

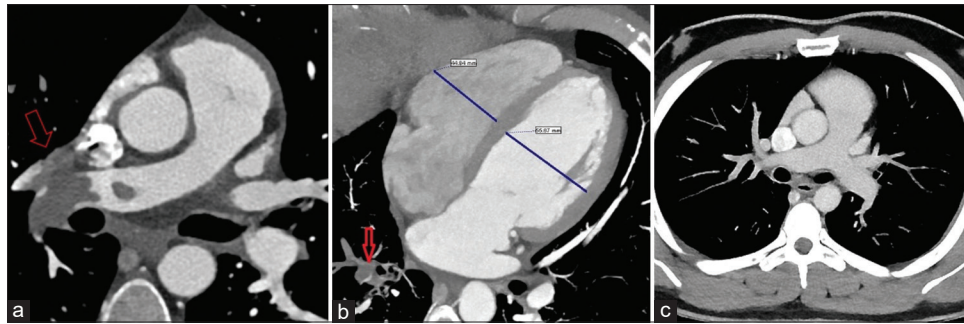


Figure 3: (a) CT shows pulmonary embolism in the right pulmonary artery (red arrows indicate the pulmonary embolus); (b) Right chamber sized were normal in the CCTA (Right ventricle: 45 mm, Left ventricle: 56 mm; RV/LV < 0,9); (c) The pulmonary computed tomography angiography was normal at the 3-month follow-up

concave ST elevations, however, it can also cause localized ST elevations. Increased troponins suggests associated myocarditis. Guidelines for the diagnosis and management of pericardial diseases recommends coronary angiography in order to rule out acute coronary syndromes, in cases of pericarditis with suspected associated myocarditis.^[11] Although increasing troponins in this patient mandated coronary evaluation, the low probability of the coronary artery disease precluded us from performing an invasive angiogram. We proceeded with CCTA relying on its high negative predictive value, and to our surprise, a diagnosis of PE was made.

Most common wrong diagnosis for PE include pneumonia, bronchitis, exacerbation of chronic obstructive pulmonary disease, and heart failure. However, this patient was initially diagnosed as peri/myocarditis. The diagnosis of PE starts with suspicion based on the symptoms and signs. The patient here presented with chest pain; nevertheless, the lack of risk factors for PE and a recent history of URTI together with concave ST-elevations misled the clinician to a diagnosis of pericarditis. Moreover, there was no sign of dilatation in the right heart in echocardiography or CCTA [Figure 3b]. The take-home messages from this case are twofolds. First, CCTA allows evaluations extracardiac structures, such as portions of lungs and aorta unlike conventional angiography, thus providing a broader diagnostic approach and offering the opportunity to detect clinically significant pathologies or underlying etiology,^[12] including PE and even myocarditis.^[13] Therefore, CCTA can be the modality of choice to exclude CAD in younger patients without a clear diagnosis. Second, ST-elevations can occur in PE, and it should be kept in mind for the differential diagnosis, when the presentation is not typical for ACS.

Financial support and sponsorship

Nil.

Conflicts of interest

There are no conflicts of interest.

REFERENCES

1. Woo KC, Schneider JI. High-risk chief complaints I: Chest pain--the big three. *Emerg Med Clin North Am* 2009;27:685-712, x.
2. Sechtem U, Achenbach S, Friedrich M, Wackers F, Zamorano JL. Non-invasive imaging in acute chest pain syndromes. *Eur J Echocardiogr* 2012;13:69-78.
3. Ouellette DW, Patocka C. Pulmonary embolism. *Emerg Med Clin North Am* 2012;30:329-75, viii.
4. Alonso-Martínez JL, Sánchez FJA, Echezarreta MAU. Delay and misdiagnosis in sub-massive and non-massive acute pulmonary embolism. *Eur J Intern Med* 2010;21:278-82.
5. Abdalla A, Kelly F. 'STEMI-like' acute pulmonary embolism, an unusual presentation. *BMJ Case Rep.* 2014;2014: bcr2014206517.
6. Wang K, Asinger RW, Marriott HJL. ST-segment elevation in conditions other than acute myocardial infarction. *N Engl J Med* 2003;349:2128-35.
7. Van Mieghem C, Sabbe M, Knockaert D. The clinical value of the ECG in noncardiac conditions. *Chest* 2004;125:1561-76.
8. Cheng TO. Mechanism of ST-elevation in acute pulmonary embolism. *Int J Cardiol* 2005;103:221-3.
9. Villablanca PA, Vlismas PP, Aleksandrovich T, Omondi A, Gupta T, Briceno DF, et al. Case report and systematic review of pulmonary embolism mimicking ST-elevation myocardial infarction. *Vascular* 2019;27:90-7.
10. Zhan Z-Q, Wang C-Q, Baranchuk A. Acute pulmonary embolism with ST-segment elevation in the inferior leads. *Int J Cardiol* 2014;177:718-9.
11. Adler Y, Charron P, Imazio M, Badano L, Barón-Esquivias G, Bogaert J, et al. 2015 ESC. Guidelines for the diagnosis and management of pericardial diseases: The Task Force for the Diagnosis and Management of Pericardial Diseases of the European Society of Cardiology (ESC) Endorsed by: The European Association for Cardio-Thoracic Surgery (EACTS). *Eur Heart.* 2015;36:2921-64.
12. Karius P, Lembecke A, Sokolowski FC, Gandara IDP, Rodríguez A, Hamm B, et al. Extracardiac findings on coronary computed tomography angiography in patients without significant coronary artery disease. *Eur Radiol* 2019;29:1714-23.
13. Bousset L, Gamondes D, Staat P, Elicker BM, Revel D, Douek P. Acute chest pain with normal coronary angiogram: Role of contrast-enhanced multidetector computed tomography in the differential diagnosis between myocarditis and myocardial infarction. *J Comput Assist Tomogr* 2008;32:228-32.