

Relapsing acute myeloid leukemia presenting as hypopyon uveitis

Sapna P Hegde¹, Atul T Ursekar², Ajay A Chitale³

Anterior segment infiltration in acute myeloid leukemia (AML) presenting as hypopyon uveitis is very rare. We report this case as an uncommon presentation in a patient on remission after bone marrow transplant for AML. In addition to the hypopyon, the patient presented with "red eye" caused by ocular surface disease due to concurrent graft-versus-host disease and glaucoma. The classical manifestations of masquerade syndrome due to AML were altered by concurrent pathologies. Media opacities further confounded the differential diagnosis. We highlight the investigations used to arrive at a definitive diagnosis. In uveitis, there is a need to maintain a high index of clinical suspicion, as early diagnosis in ocular malignancy can save sight and life.

Key words: Acute myeloid leukemia, hypopyon, masquerade syndrome

Departments of ¹Ophthalmology and ³Pathology, Jaslok Hospital and Research Centre, Dr. G. Deshmukh Marg, Mumbai 400 026, ²Ursekar Laser and Microsurgery Eye Clinic, Krishna Niwas, 2nd Floor, Junction of Karve Road and R. R. Roy Road, Mumbai 400 004, India.

Correspondence to: Dr. Atul Ursekar, Ursekar Laser and Microsurgery Eye Clinic, Krishna Niwas, 2nd Floor, Junction of Karve Road and R.R. Roy Road, Mumbai 400 004, India. E-mail: drursekar@gmail.com

Manuscript received: 08.02.09; **Revision accepted:** 28.12.10

Cite this article as: Hegde SP, Ursekar AT, Chitale AA. Relapsing acute myeloid leukemia presenting as hypopyon uveitis. Indian J Ophthalmol 2011;59:391-3.

Access this article online

Quick Response Code:	Website:
	www.ijo.in
	DOI: 10.4103/0301-4738.83621

Intraocular inflammation presenting as hypopyon may occur in acute lymphoblastic leukemia (ALL), acute myeloid leukemia (AML), and chronic myeloid leukemia (CML). Compared to a 2.5–18% incidence of anterior segment infiltration in ALL,^[1] isolated presentation of hypopyon uveitis is very rare in AML, with only one similar reported case.^[2]

Ocular involvement may occur by direct infiltration of neoplastic cells, hemorrhage, or by ischemic changes.^[2] It can manifest as intraocular inflammation not responding to conventional therapy, which is referred to as "masquerade syndrome".^[3] Primary retinal lymphoma presenting as uveitis in a quiet eye in the elderly is the most frequent cause for masquerade syndrome.^[4] Ocular involvement of systemic leukemia may be the first sign of extramedullary spread or relapse after treatment.

We report this rare case to highlight the pivotal role of the ophthalmologist to confirm a relapse after successful remission

in AML. We discuss the variation of clinical manifestations complicating the differential diagnosis.

Case Report

A 35-year-old female patient presented with recent-onset of pain, redness, and lid swelling in the right eye. Four years earlier she had undergone bone marrow transplantation (BMT) for AML, with successful remission. She was under treatment with oral steroids for graft-versus-host-reaction (GVH). Her left eye had undergone cataract extraction with intraocular lens implantation 2 years previously.

Her best-corrected vision in the right eye was counting fingers and in the left eye was 20/20. The right eye showed lid edema, conjunctival and ciliary congestion, chemosis, a paracentral corneal epithelial defect, 3+ cells in the anterior chamber (AC) with fibrin strands and hypopyon and a posterior subcapsular cataract. The left eye was unremarkable except for

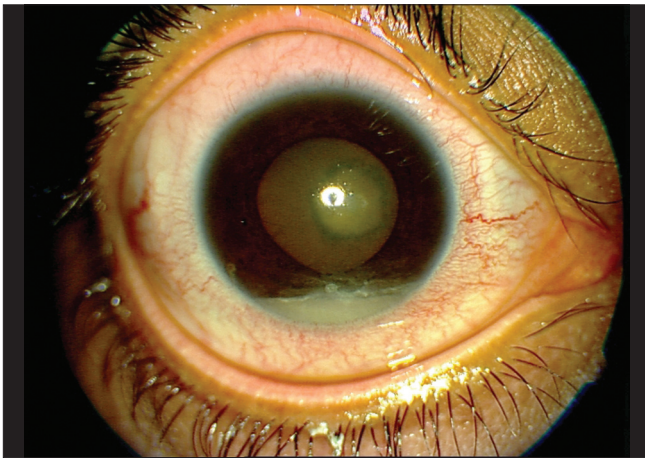


Figure 1: Hypopyon persists in anterior chamber (AC) after topical steroid treatment. Lid edema and congestion have reduced after treating glaucoma and ocular surface disease due to graft-versus-host disease (GVH)

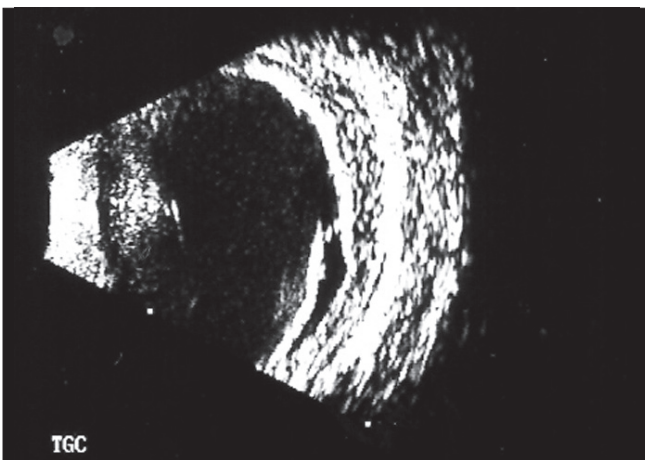


Figure 2: B-scan shows choroidal thickening and elevated retina inferiorly suggestive of choroidal infiltration and exudative retinal detachment

pseudophakia. Applanation intraocular pressure (IOP) was 34 mmHg in the right eye and 30 mmHg in the left eye.

Right fundus could not be seen clearly due to media opacities produced by a combination of corneal epithelial defect, AC reaction, and cataract. The left fundus was normal. Initial diagnosis of a corneal epithelial defect in the right eye, and bilateral glaucoma was made. She was started on topical antibiotics (gatifloxacin), ocular lubricants (carboxymethylcellulose), and mydriatic-cycloplegics (1% atropine) for the right eye and topical glaucoma medications (0.5% timolol) bilaterally.

On follow-up, the epithelial defect had healed and the lid edema, redness, and IOP had reduced. Interestingly, there was an unremarkable change in the hypopyon. She was prescribed topical steroids (1% prednisolone acetate) and was reviewed at close intervals. Nevertheless, the hypopyon was not responsive even after a week of treatment [Fig. 1].

Due to failure of conventional treatment, masquerade syndrome was suspected and investigated. B-scan ultrasonography showed a few intravitreal echoes, choroidal thickening, and exudative retinal detachment [Fig. 2].

Aspiration of the AC infiltrate was performed under aseptic conditions. Cytology showed malignant cells with typical morphologic characteristics of leukemic infiltrate [Fig. 3].

Based upon the cytology and ultrasonography, we arrived at a diagnosis of relapse of AML involving the AC and choroid. She was referred to an oncologist for further management. The patient decided to discontinue any further treatment. She succumbed to her relapsing illness a few months later.

Discussion

Relapse of ALL manifesting as hypopyon uveitis has been reported.^[5] It is extremely rare for relapse of AML to present with anterior segment manifestations. In a prospective 2-year study of 53 patients undergoing treatment of AML, no patient presented with hypopyon uveitis.^[6]

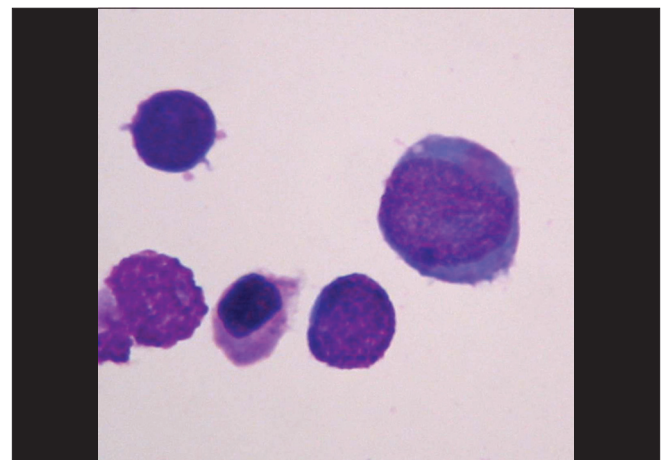


Figure 3: Cytology of anterior chamber (AC) aspirate shows malignant cells confirming the rare location of ocular relapse in acute myeloid leukemia (AML)

We could find only one reference similar to our report.^[2] Unlike our patient, this case presented with painless quiet bilateral hypopyon uveitis refractory to steroids.

Our patient presented with multiple possible causes for visual loss and pain including corneal epithelial defect, AC reaction, and posterior subcapsular cataract and glaucoma. The patient was taking oral steroids for GVH, which confounded her initial clinical picture. In leukemic patients who have undergone BMT, the occurrence of GVH can further mask a classic presentation of masquerade syndrome by causing a congested, painful eye.^[7] The occurrence of multiple concurrent pathologies may create "classical signs" of acute ocular inflammation which are usually absent in masquerade syndrome.

Increase in IOP can be due to the presence of tumor cells in the AC.^[2] However, in this patient, IOP was high in both eyes at initial presentation. The secondary glaucoma was possibly due to a combination of tumor infiltration affecting the right eye and systemic steroid therapy affecting both eyes.

Posterior segment infiltration could not be visualized due to a combination of corneal, lenticular, and AC pathology. A high index of suspicion is necessary in patients with leukemia who are in remission. In such patients, Mumps uveitis^[8] and chemical Reiter's syndrome^[9] may further complicate the diagnosis. In patients with a malignant cause of masquerade syndrome, cytologic analysis of intraocular fluids has been reported to be an essential diagnostic procedure with positive yield in 64% of cases.^[3]

Although CD56 expression of tumor cells is believed to be associated with CNS involvement,^[10] immunophenotyping could not be done in our case. Since there are few references of immunophenotyping of hypopyon cells in AML, this association with CD56 is yet to be confirmed. It is postulated that the blood-ocular barrier may be responsible for creating a "pharmacological sanctuary", resulting in suppression, but not eradication of malignant cells by chemotherapeutic agents. These cells may be responsible for relapse.

In one report,^[10] patients with AML treated with radiotherapy and chemotherapy developed leukemic hypopyon 3 months to 9 years after initial diagnosis. All reviewed patients in this report died within 1 year of developing leukemic hypopyon. Although the treatment of AML has changed since, their conclusion that leukemic hypopyon is associated with systemic leukemic relapse even if systemic examination reveals no leukemia, except for that in the AC, remains valid today.

Therefore, local and systemic chemotherapy is indicated for these patients.

Patients with hypopyon uveitis may present with or without the classical clinical signs of masquerade syndrome depending upon coexisting ocular pathology. Judicious use of cytology was useful in differentiating it from true inflammation and confirming this rare complication of AML. Timely diagnosis is essential, particularly if the suspicion of ocular or systemic malignancy needs to be validated.

Acknowledgments

The authors would like to thank Mr. Ashok Pohekar, Photography Technician, Jaslok Hospital and Research Centre, Dr. G. Deshmukh Marg, Mumbai.

References

1. Ramsay A, Lightman S. Hypopyon uveitis. *Surv Ophthalmol* 2001;46:1-18.
2. Ayliffe W, Foster CS, Marcoux P, Upton M, Finkelstein M, Kuperwaser M, *et al.* Relapsing acute myeloid leukemia manifesting as hypopyon uveitis. *Am J Ophthalmol* 1995;119:361-4
3. Rothova A, Ooijman F, Kerkhoff F, Van Der Lelij A, Lokhorst HM. Uveitis masquerade syndromes. *Ophthalmology* 2001;108:386-99.
4. Gill MK, Jampol LM. Variations in the presentation of primary intraocular lymphoma: Case reports and a review. *Surv Ophthalmol* 2001;45:463-71.
5. Wadhwa N, Vohra R, Shrey D, Iyer VK, Garg S. Unilateral hypopyon in a child as a first and sole presentation in relapsing acute lymphoblastic leukemia. *Indian J Ophthalmol* 2007;55:223-4.
6. Karesh JW, Goldman EJ, Reck K, Kelman SE, Lee EJ, Schiffer CA. A prospective ophthalmic evaluation of patients with acute myeloid leukemia: Correlation of ocular and hematologic findings. *J Clin Oncol* 1989;7:1528-32.
7. Yi DH, Rashid S, Cibas ES, Arrigg PG, Dana MR. Acute unilateral leukemic hypopyon in an adult with relapsing acute lymphoblastic leukemia. *Am J Ophthalmol* 2005;139:719-21.
8. Al-Rashid RA, Cress C. Mumps uveitis complicating the course of acute leukemia. *J Pediatr Ophthalmol* 1977;14:100-2.
9. Dharmasena F, Englert H, Catovsky D, Galton DA, Drysdale HC. Incomplete Reiter's syndrome following chemotherapy of acute myeloid leukemia. *Postgrad Med J* 1986;62:1045-6.
10. Matano S, Ohta T, Nakamura S, Kanno M, Sugimoto T. Leukemic hypopyon in acute myelogenous leukemia. *Ann Haematol* 2000;79:455-8.