

Case Report

---

# Metastatic Ovarian Cancer Presenting as Inflammatory Breast Cancer: A Case Report

Mohammad Abu-Tineh<sup>a</sup> Hind Elmalik<sup>b</sup> Mohamed A. Yassin<sup>b</sup>

<sup>a</sup>Department of Medical Education, Hamad Medical Corporation, Doha, Qatar;

<sup>b</sup>National Center for Cancer Care and Research, Department of Oncology, Hamad Medical Corporation, Doha, Qatar

## Keywords

Metastatic ovarian cancer · Clear cell cancer · Breast · Malignancy · Radiotherapy

## Abstract

Metastatic ovarian cancer to the breast is a rare presentation, with limited cases reported worldwide. Common sites for distant metastasis in ovarian cancer are to the liver, lung, and pleura [Dauplat et al. *Cancer*. 1987 Oct 1;60(7):1561–6]. Usually, such cases predict poor prognosis with troublesome management. We present one challenging case of a 54-year-old female patient with recurrent clear cell ovarian cancer, presenting with right breast mass of primary versus secondary origin, progressing into inflammatory breast cancer picture. Our report aims to shed light on the value of early suspicion and low threshold of detecting secondary breast masses of ovarian cancer origin.

© 2020 The Author(s).  
Published by S. Karger AG, Basel

## Introduction

Ovarian cancer is the third most common gynecologic malignancy in developed countries after uterine and cervical cancer and the second most common gynecologic malignancy in developing countries [1]. Most epithelial ovarian cancers usually metastasize through the peritoneal cavity, and on rare occasions disseminate hematogenously [2]. Metastatic ovarian lesions to the breast are one of the rare presentations of a breast mass, and even less frequently

---

Mohammad Abu-Tineh  
Department of Medical Education, Hamad Medical Corporation  
Hamad General Hospital, HMC, Alrayan Street  
Doha (Qatar)  
Abutineh90@gmail.com

presenting as inflammatory breast cancer [3]. Differentiating extramammary malignancy from primary breast cancers is an important step to guide for better management and prognosis.

Before the advent of platinum-based chemotherapy, multiple old techniques and methods of radiotherapy (RT) were used in the treatment of ovarian cancer, such as whole abdominal RT, which was associated with poor outcomes due to high toxicity levels in around 75% of patients [4].

One of the reasons for implementing radiation in clear cell carcinoma of the ovary is the relative chemotherapeutic resistance of this histological type of ovarian cancer when compared to the more common serous histopathology [4].

Recently, new radiation therapy methods that more precisely target the diseased parts and spare the surrounding tissue are being explored in patients with ovarian cancer.

We report a rare case of metastatic clear cell ovarian cancer to the breast.

## Case Presentation

Our case is a 54-year-old female, who at presentation was post-menopausal for 4 years, married, with 2 children, aged 35 and 20, with a performance status of 0. She presented to the hospital in August 2018, with multiple visits complaining of abdominal pain, recurrent vomiting, and urinary retention. US abdomen and the transvaginal US was done showing a large heterogeneous complex solid/cystic lesion. MRI pelvis showed a large heterogeneous complex solid/cystic pelvic lesion with left adnexal region extension likely originated from the left ovary, suggestive of an ovarian neoplasm.

The patient underwent laparotomy with total abdominal hysterectomy + bilateral salpingo-oophorectomy + omentectomy. Histopathology results came consistent with high-grade ovarian clear cell carcinoma, with lymphovascular invasion with omental involvement. Right ovary, bilateral tubes, cervix, and uterus were uninvolved.

The final pathologic diagnosis of the tumor was high-grade FIGO stage IIIA, of left ovarian origin, largest extra-pelvic peritoneal focus: microscopic. The peritoneal ascitic fluid analysis showed malignant cells. Ancillary studies: diffuse positivity for napsin A, with focal positivity to ER. WT-1, AFP, and CD10 were negative, and p53 was negative, suggestive of wild-type pattern. Initial CA 125 was 108 U/mL before surgery.

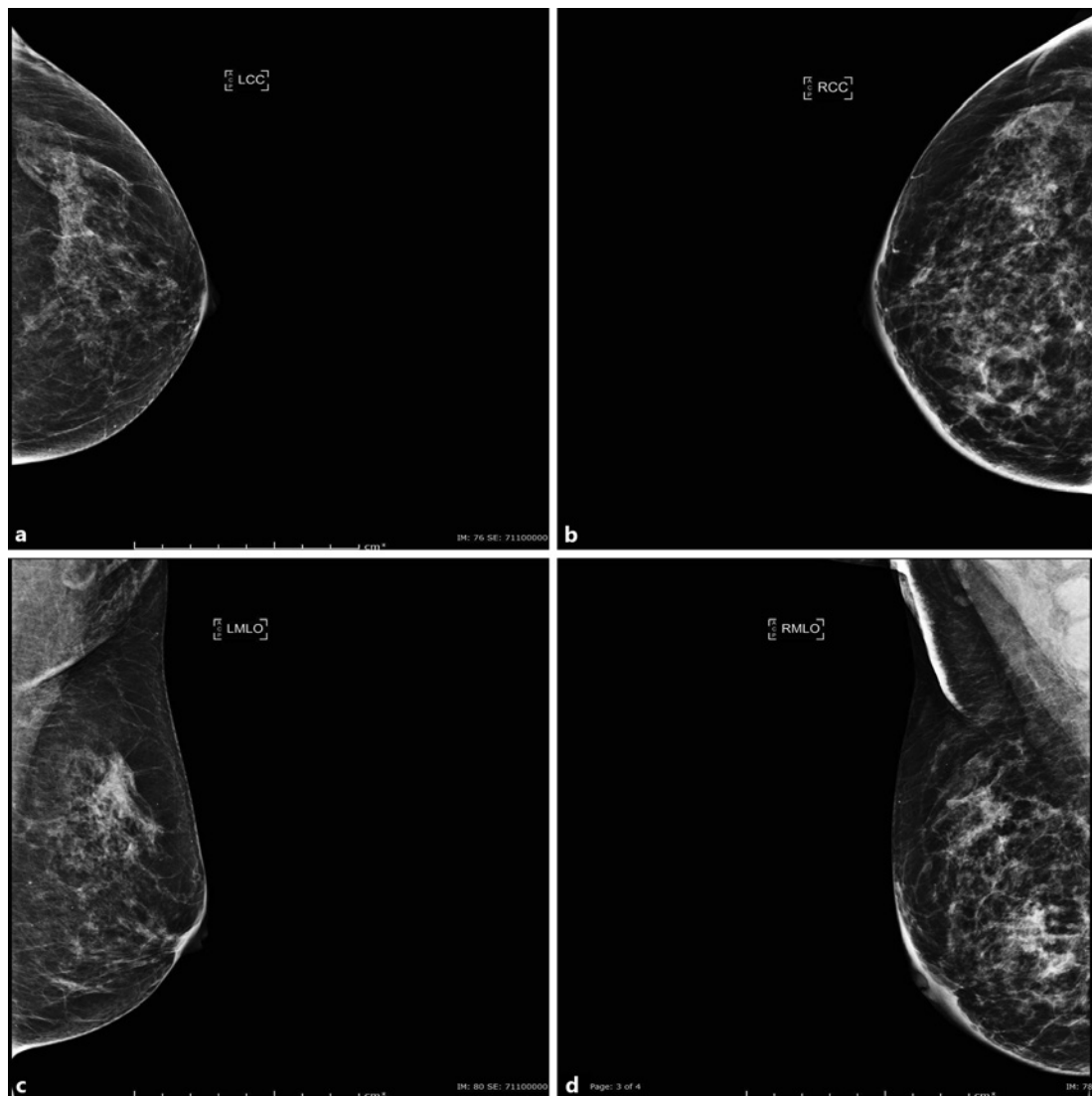
The rest of the patient history was non-significant, with a non-contributory family history of breast or ovarian cancer, and normal physical examination aside from left-sided old facial palsy.

The case was discussed in a multidisciplinary team meeting, and the decision made to start on adjuvant chemotherapy, paclitaxel-carboplatin. The patient received 6 cycles (dated: October 15, 2018– February 28, 2019), the last 3 cycles were reduced because of neuropathy and neutropenia grade 2–3. Post chemotherapy, CA 125 was repeated: 12.5 U/mL.

The patient was then kept on surveillance with clinic follow-up every 3 months for history and examination, CA 125 level, and re-imaging as indicated (e.g., a rise in CA 125).

In October 2019, the patient presented back to the hospital with complaints of vague anterior chest pain and breast pain. On exam, the patient was found to have a lump in the right breast, at 3 o'clock, about 4 cm, fluctuating, non-tender, with palpable axillary nodes, no skin changes, no nipple retraction, and no discharge. The left breast examination was normal. CA 125 was repeated: 200 U/mL.

A mammogram was done showing abnormality at the right breast with diffuse skin thickening, associated with multiple enlarged right axillary lymph nodes, with multiple enlarged right supraclavicular and right cervical lymph nodes, with suspicious right internal mammary

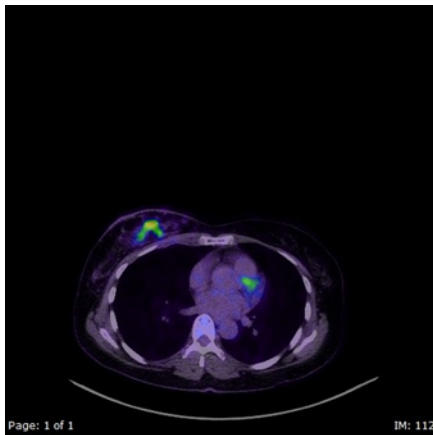


**Fig. 1.** Mammogram done on October 2019 showing diffuse skin thickening, associated with multiple enlarged right axillary lymph nodes impression of BI-RADS 4, a suspicious abnormality.

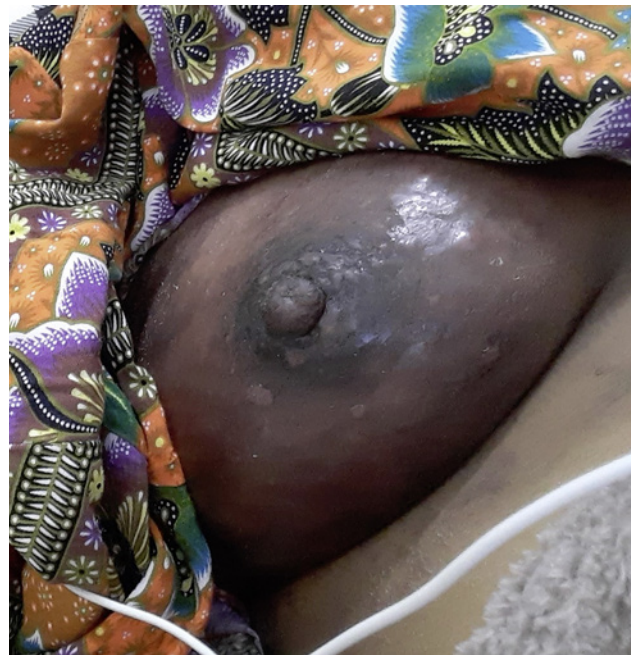lymph node and suspicious sternum mass, with the impression of BI-RADS 4, a suspicious abnormality (Fig. 1).

PET CT was done, which showed hypermetabolic right lower neck and supraclavicular lymphadenopathy, right axillary, right cardiophrenic and mediastinal lymph nodes, hypermetabolic right breast nodules highly suspicious for multicentric malignancy, with slight thickening and mildly prominent tracer uptake in the skin over the right breast suspicious for involvement in the disease process/inflammatory type of malignancy, hypermetabolic sternal destructive lesions highly suspicious for malignancy, with no hypermetabolic abnormality seen in the abdomen and pelvis (Fig. 2).

After PET scan, the patient was planned for breast biopsy and to start on treatment accordingly, but the patient eagerly expressed her wishes to visit her home country for a family visit before the next step, even though risks were explained to the patient. Around 6 weeks later when she returned (Fig. 3), she was found to have large palpable right axillary



**Fig. 2.** PET/CT scan showing hypermetabolic right breast nodules highly suspicious for multicentric malignancy, with slight thickening and mildly prominent tracer uptake in the skin over the right breast suspicious for involvement in the disease process/inflammatory type of malignancy.



**Fig. 3.** Picture demonstrating the inflammatory breast changes on patient presentation. Inflammatory breast cancer from metastatic ovarian cancer.

lymph nodes and hypercalcemia. Her right breast and right axillary lymph node biopsy was done urgently. She had ongoing progressive breast changes of redness, swelling, and skin induration and thickening of the whole breast. Biopsy came consistent with metastatic carcinoma of ovarian origin.

Genetic testing came negative for any pathogenic mutations in the BRCA1 and BRCA2 genes on sequencing analysis.

The patient then started on palliative chemotherapy, received first cycle of PLD + bevacizumab on January 5, 2020, followed by RT to the breast. The patient received 30 Gy in 10 fractions (January 8–21, 2020)

Post radiation, the patient's course was complicated with shortness of breath as she developed pneumonia with para-pneumonic effusion and cytology consistent with metastatic adenocarcinoma. MRI pelvis was ordered for progressive back pain, which showed multiple variable-sized focal osseous lumbar vertebral and bony pelvis likely metastatic. The patient then received 1 session of palliative RT to L1--3 for pain control.

As her general condition worsened, with poor performance status, which was not allowing to continue on palliative chemotherapy, the plan was to keep on supportive measures, once more stable to resume, but the patient asked to go back to her home country to continue her treatment there.

## Discussion

Epithelial cancers which are originated from peritoneal, ovarian, and fallopian tube, usually manifest with matching clinical features and behavior. They are grouped as epithelial ovarian cancer. Epithelial ovarian cancers account for 90 percent of all cancers at these sites

[5, 6]. It is the most common cause of death among women with gynecologic malignancies, being in fifth place as a leading cause of cancer death in women in the United States. The characteristics of ovarian carcinoma are different from other hematogenously metastasizing tumors, as patients mostly have a locally advanced disease in the pelvis, given that the ovarian cancer cells spread within the omentum, bowel surface, and peritoneal cavity, and are only superficially invasive [2, 7]. Distant metastases are about 38% of their course of the disease. Ovarian carcinoma is a known deadly disease, with a cure rate of only 30% [2]. The high mortality of this tumor is due to the high percentage (around 75%) of patients presenting at an advanced stage, with a widely metastatic disease within the peritoneal cavity [2].

Breast cancer is one of the most common primary malignancies in women, yet metastatic tumors to the breast are infrequent, attributing only 0.5–1.3% of breast cancer cases [3]. The most common source of metastasis to the breast is the contralateral primary breast tumor, usually from the transthoracic or lymphatic spread. However, hematogenous metastasis from extra-mammary malignancies has been reported, with extra-mammary metastases accounting for less than 1% of breast tumors. The most common primary sites for metastatic carcinomas to the breast include lung and ovary [8]. Secondary breast involvement from an ovarian origin reflects widespread dissemination and is associated with a poor prognosis [3].

Serous carcinomas of ovarian and primary peritoneal origin usually metastasize to pelvic lymph nodes and are less likely to involve axillary lymph nodes [9].

Axillary lymph node metastases can be associated with breast involvement, which usually present as a parenchymal mass lesion, reported in only 0.03–0.6% of all breast cancers. On fewer incidents, breast metastases can present as inflammatory breast carcinoma, which is even more infrequent with metastases to the breast from extramammary cancers (0.2–1.3%) [7]. There are twelve previously published case reports of metastatic ovarian tumors presenting as inflammatory carcinoma over the breast [10–19]. The most common histological variant of ovarian cancer associated with breast metastases is papillary serous adenocarcinoma. Clear cell carcinoma of the breast had an incidence of 0.9–2.7% [7].

Immunohistochemical stains can help to differentiate between carcinomas of breast and ovarian. CA 125 is usually expressed in ovarian and pancreatobiliary tumors. Strong and diffuse CA 125 staining is usually seen in the majority of ovarian tumors as opposed to focal, weak expression in a small subset of breast carcinomas. The expression of progesterone and estrogen receptors can be seen in both ovarian and breast carcinomas. WT1, PAX8, and GCDFP-15 have a significant role in distinguishing between primary and metastatic breast cancers from ovarian cancer [20], and over 90% of ovarian serous carcinomas are WT1 positive. Less than 10% of primary breast cancer cases are positive for WT1, with weak and patchy WT1 expression [21]. However, nuclear reactivity is observed in approximately 20% of clear cell carcinoma [22].

Concurrent ovarian and breast carcinomas are seen more often in the setting of positive BRCA mutation carriers. Diagnosis of a breast tumor in a patient with ovarian carcinoma or the other way might be an indication for the evaluation of BRCA status, which was tested negative in our case.

Treatment of recurrent ovarian cancer continues to be a challenge, with low long-term survival despite multiple chemotherapy regimens and target therapy. Currently, treatment for recurrent/relapsed ovarian clear cell cancer includes suppression of neo-angiogenesis and systemic therapy of platinum- or non-platinum-based chemotherapy, according to the time of recurrence [23].

The role of RT in the treatment of ovarian cancer has changed over the years. Years back, multiple methods of RT were used, such as whole-abdominopelvic irradiation (WAI) and intraperitoneal installation of radiocolloids in the management of ovarian cancer, and it has shown a significant rate of toxicity, including acute events such as diarrhea, fatigue, nausea,

and hematologic effects. In principle, treatment volumes during WAI delivered with external beam radiation comprised all peritoneal surfaces. Long-term toxicities included pneumonitis in up to 20% of patients, liver damage, and bowel toxicity (10–15% of patients) [24–27].

However, lately due to recent improvement in the radiation techniques with lower toxicity and complications, it has restored the interest of using RT for metastatic cancers such as ovarian cancer. These techniques, which have shown potency in other cancers, include intensity-modulated radiotherapy (IMRT) and volumetric modulated arc therapy.

In a recently conducted study of PET/CT-guided IMRT in 42 patients with stages III/IV recurrent ovarian cancer, PET/CT-guided IMRT was administered to patients who received three different treatment types: surgery plus chemotherapy plus radiotherapy, chemotherapy plus radiation therapy, and radiation therapy only. The difference in overall survival time was not statistically significant between the three groups, especially the third group of patients, who could not undergo surgery or chemotherapy, which concludes that PET/CT-guided IMRT is an effective and safe treatment method, and it may be considered as an equally effective treatment option [28].

Few studies are being conducted to reevaluate the role of radiotherapy for the treatment of ovarian clear cell cancer, possibly as adjuvant therapy, given its chemoresistant nature and its high radio-sensitivity, seeking better outcomes [2].

## Conclusion

Metastatic ovarian cancer to the breast is a rare presentation and can present as inflammatory breast cancer, it is always necessary to have the right diagnosis as the first step, as management and treatment are different accordingly. Histological and immunohistochemistry is helpful for the right diagnosis. Currently, the treatment of such disease is mainly with systemic chemotherapy and target therapy. Adding radiotherapy to the localized breast recurrent metastatic lesions of clear cell ovarian cancer could be a possible treatment modality to be considered. Recent studies are being conducted on the effect of radiotherapy in adjuvant setting of such disease. We report this case to increase the awareness of how aggressive ovarian cell cancer can present and the possible treatment modalities to consider.

## Acknowledgment

We thank Qatar National Library for funding this article, and the internal medicine residency program at HMC for their support.

## Statement of Ethics

Written informed consent was obtained from our patient to allow the publication of information including images.

## Conflict of Interest Statement

The authors have nothing to disclose.

## Funding Sources

This article was funded by Qatar National Library.

## Author Contributions

Mohammad Abu-Tineh: writing the manuscript, clinical care. Hind Elmalik: clinical follow-up, writing and editing the manuscript. Mohamed A. Yassin: writing and editing the manuscript.

## References

- 1 Surveillance, epidemiology, and end results cancer stat facts: ovarian cancer. <http://seer.cancer.gov/stat-facts/html/ovary.html>
- 2 Lengyel E Ovarian cancer development and metastasis. *Am J Pathol*. 2010 Sep 1;177(3):1053–64.
- 3 Klein RL, Brown AR, Gomez-Castro CM, Chambers SK, Cragun JM, Grasso-LeBeau L, et al. Ovarian cancer metastatic to the breast presenting as inflammatory breast cancer: a case report and literature review. *J Cancer*. 2010;1:27–31.
- 4 Fields EC, McGuire WP, Lin L, Temkin SM. Radiation treatment in women with ovarian cancer: past, present, and future. *Front Oncol*. 2017 Aug 21;7:177.
- 5 Heinz A. Carcinoma of the ovary. Annual report on the results of treatment in gynecologic cancer. *J Epidemiol Biostat*. 2001;6:107–38.
- 6 Banks E. The epidemiology of ovarian cancer. *Methods Mol Med* 2001;39:3–11.
- 7 Achariyapota V, Chuangsuwanich T, Benjapibal M. Inflammatory breast cancer from metastatic ovarian cancer. *Case Rep Obstet Gynecol*. 2016;2016:3476143.
- 8 DeLair DF, Corben AD, Catalano JP, Vallejo CE, Brogi E, Tan LK. Non-mammary metastases to the breast and axilla: a study of 85 cases. *Mod Pathol*. 2013 Mar;26(3):343–9.
- 9 Panse G, Bossuyt V, Ko CJ. Metastatic serous carcinoma presenting as inflammatory carcinoma over the breast—Report of two cases and literature review. *J Cutan Pathol*. 2018 Mar;45(3):234–9.
- 10 Özgüroglu M, Ersavasti G, Ilvan S, Hatemi G, Demir G, Demirelli FH. Bilateral inflammatory breast metastases of epithelial ovarian cancer. *Am J Clin Oncol*. 1999 Aug 1;22(4):408–10.
- 11 Kayikcioglu F, Boran N, Ayhan A, Güler N. Inflammatory breast metastases of ovarian cancer: a case report. *Gynecol Oncol*. 2001;83(3):613–6.
- 12 Krishnan EU, Phillips AK, Randell A, Taylor B, Garg SK. Bilateral metastatic inflammatory carcinoma in the breast from primary ovarian cancer. *Obstet Gynecol*. 1980 Mar;55(3 Suppl 1):94S–6S.
- 13 Fondrinier E, Gamelin E, Verrielle V. Inflammatory breast metastasis from primary ovarian cancer: case report. *Eur J Gynaecol Oncol*. 1999;20(1):16–7.
- 14 Sato T, Muto I, Fushiki M, Hasegawa M, Hasegawa M, Sakai T, et al. Metastatic breast cancer from gastric and ovarian cancer, mimicking inflammatory breast cancer: report of two cases. *Breast Cancer*. 2008 Oct 1;15(4):315–20.
- 15 Khalifeh I, Deavers MT, Cristofanilli M, Coleman RL, Malpica A, Gilcrease MZ. Primary peritoneal serous carcinoma presenting as inflammatory breast cancer. *Breast J*. 2009 Mar;15(2):176–81.
- 16 Papakonstantinou K, Antoniou A, Palialexis K, Politi E, Karvouni E, Fotiou S. Fallopian tube cancer presenting as inflammatory breast carcinoma: report of a case and review of the literature. *Eur J Gynaecol Oncol*. 2009;30(5):568–71.
- 17 Klein RL, Brown AR, Gomez-Castro CM, Chambers SK, Cragun JM, Grasso-LeBeau L, et al. Ovarian cancer metastatic to the breast presenting as inflammatory breast cancer: a case report and literature review. *J Cancer*. 2010;1:27–31.
- 18 Achariyapota V, Chuangsuwanich T, Benjapibal M. Inflammatory breast cancer from metastatic ovarian cancer. *Case Rep Obstet Gynecol*. 2016;2016:3476143.
- 19 Panse G, Bossuyt V, Ko CJ. Metastatic serous carcinoma presenting as inflammatory carcinoma over the breast—Report of two cases and literature review. *J Cutan Pathol*. 2018 Mar;45(3):234–9.
- 20 Tornos C, Soslow R, Chen S, Akram M, Hummer AJ, Abu-Rustum N, et al. Expression of WT1, CA 125, and GCDFP-15 as useful markers in the differential diagnosis of primary ovarian carcinomas versus metastatic breast cancer to the ovary. *Am J Surg Pathol*. 2005 Nov 1;29(11):1482–9.
- 21 Chen YY. Immunostain update: diagnosis of metastatic breast carcinoma, emphasizing the distinction from gynecologic cancers. June 2010.
- 22 Wang Y, Wang Y, Li J, Yuan Z, Yuan B, Zhang T, et al. PAX8: a sensitive and specific marker to identify cancer cells of ovarian origin for patients prior to neoadjuvant chemotherapy. *J Hematol Oncol*. 2013 Dec;6(1):60.

- 23 Kudoh K, Takano M, Kouta H, Kikuchi R, Kita T, Miyamoto M, et al. Effects of bevacizumab and pegylated liposomal doxorubicin for the patients with recurrent or refractory ovarian cancers. *Gynecol Oncol*. 2011 Aug 1; 122(2):233–7.
- 24 Albuquerque KV, Singla R, Potkul RK, Smith DM, Creech S, Lo S, et al. Impact of tumor volume-directed involved field radiation therapy integrated in the management of recurrent ovarian cancer. *Gynecol Oncol*. 2005 Mar 1;96(3):701–4.
- 25 Brown AP, Jhingran A, Klopp AH, Schmeler KM, Ramirez PT, Eifel PJ. Involved-field radiation therapy for locoregionally recurrent ovarian cancer. *Gynecol Oncol*. 2013 Aug 1;130(2):300–5.
- 26 Du XL, Jiang T, Sheng XG, Li QS, Wang C, Yu H. PET/CT scanning guided intensity-modulated radiotherapy in treatment of recurrent ovarian cancer. *Eur J Radiol*. 2012 Nov 1;81(11):3551–6.
- 27 Thomas GM, Dembo AJ. Integrating radiation therapy into the management of ovarian cancer. *Cancer*. 1993 Feb 15;71(4 Suppl 1):1710–8.
- 28 Dang YZ, Li X, Ma YX, Li XL, Yang T, Lu WL, et al. 18F-FDG-PET/CT-guided intensity-modulated radiotherapy for 42 FIGO III/IV ovarian cancer: a retrospective study. *Oncol Lett*. 2019 Jan 1;17(1):149–58.