

Scientific Article

Transarterial Yttrium-90 Glass Microsphere Radioembolization of Chemotherapy-Refractory Breast Cancer Liver Metastases: Results of a Single Institution Retrospective Study



Elie Barakat, MD,^a Andras Bibok, MD,^{a,b} Anupam Rishi, MD,^c
Altan Ahmed, MD,^a Jessica M. Frakes, MD,^c Sarah E. Hoffe, MD,^c
Avan J. Armaghani, MD,^d Aixa E. Soyano, MD,^d Ricardo L.B. Costa, MD,^d
Ghassan El-Haddad, MD,^a Junsung Choi, MD,^a and Bela Kis, MD, PhD^{a,*}

^aDiagnostic Imaging and Interventional Radiology, Moffitt Cancer Center, Tampa, Florida; ^bDepartment of Transplantation and Surgery, Semmelweis University, Budapest, Hungary; ^cRadiation Oncology, Moffitt Cancer Center, Tampa, Florida; ^dBreast Oncology, Moffitt Cancer Center, Tampa, Florida

Received June 1, 2021; accepted October 8, 2021

Abstract

Purpose: Our purpose was to retrospectively evaluate the safety and efficacy of transarterial hepatic radioembolization (TARE) treatment with yttrium-90 labeled glass microspheres in patients with chemotherapy-refractory breast cancer with liver-dominant metastatic disease.

Methods and Materials: This retrospective single-institution study evaluated 31 female patients (mean age of 59.6 ± 13.2 years) who were treated with TARE. All patients received and progressed on systemic chemotherapy before TARE. Twenty-one patients also had extrahepatic metastases, including 13 patients who had metastases in bones only besides the liver. Survival data were analyzed by Kaplan-Meier method and compared using log-rank test. Imaging response to treatment was determined by Response Evaluation Criteria in Solid Tumors.

Results: Median overall survival (OS) from the TARE was 13 months (95% confidence interval, 9.1-16.9 months). The survival probability at 1, 2, and 3 years was 60.1%, 36.7%, and 24.5%, respectively. The median hepatic progression-free survival was 7 months (95% confidence interval, 6.1-7.9 months). There was no 30-day mortality and 3 patients (9.4%) had grade 3 toxicity. Estrogen receptor (ER) positive status predicted prolonged survival (14 months for ER+ vs 9 months for ER-; $P = .028$). Patients who had bone-only extrahepatic disease had higher OS than patients with extraosseous metastases (23 vs 8 months, $P = .02$). At the 3-month follow-up the radiographic objective response rate was 46.6% and disease control rate was 70%.

Conclusions: The treatment of patients with liver-dominant chemotherapy-refractory breast cancer metastases with TARE using yttrium-90 labeled glass microspheres is safe and led to promising hepatic disease control and OS especially in patients with ER+ tumors and in patients without extrahepatic extraosseous metastases.

© 2021 The Authors. Published by Elsevier Inc. on behalf of American Society for Radiation Oncology. This is an open access article under the CC BY-NC-ND license (<http://creativecommons.org/licenses/by-nc-nd/4.0/>).

Sources of support: This work had no specific funding.

Disclosures: none.

Research data are stored in an institutional repository and will be shared upon request to the corresponding author.

*Corresponding author: Bela Kis, MD, PhD; E-mail: bela.kis@moffitt.org

<https://doi.org/10.1016/j.adro.2021.100838>

2452-1094/© 2021 The Authors. Published by Elsevier Inc. on behalf of American Society for Radiation Oncology. This is an open access article under the CC BY-NC-ND license (<http://creativecommons.org/licenses/by-nc-nd/4.0/>).

Introduction

Breast cancer is the most common cancer in women, affecting 1 of every 8 women in a lifetime.¹ Patients with localized disease have an excellent prognosis, with a

5-year survival exceeding 99%.² Unfortunately, despite advances in adjuvant therapies, breast cancer metastases will develop in 20% to 50% of patients, with bone, liver, and lungs being the most common sites.³⁻⁵ Autopsy reports show liver metastasis in 60% of patients with breast cancer.⁶ Patients with metastatic breast cancer have a poor prognosis, with a 5-year survival of only 20% to 25%.²

Available treatment options for patients with breast cancer with liver metastases are limited. Surgical resection of liver metastases has not been widely adopted because only 10% to 20% of patients are surgical candidates due to the presence of multisegmental liver disease at the time of diagnosis and due to the high recurrence rate of up to 67% after resection.⁷⁻⁹ Palliative systemic chemotherapy is the standard approach to treat metastatic breast cancer. However, in most cases the metastases develop resistance to systemic therapies and the treatment of chemo-refractory breast cancer liver metastases remains a clinical dilemma. In these patients, liver-directed therapies can be used to reduce tumor burden, ameliorate right upper quadrant pain, preserve or improve liver function, and slow disease progression.¹⁰

Available liver-directed treatments of breast cancer metastases include image-guided thermal ablations (cryoablation, radiofrequency ablation, and microwave ablation), transarterial chemoembolization (TACE), and transarterial radioembolization (TARE). Image-guided thermal ablations of liver metastasis are limited to patients with oligometastatic disease (≤ 5 metastasis) with lesions smaller than 3 cm in size. There are no data as to which subpopulations of patients with breast cancer can benefit from liver tumor ablations, and recent meta-analysis showed better survival after resection compared with

radiofrequency ablation.^{11,12} Therefore, ablation is reserved for patients who are not surgical candidates. TACE and TARE are more suitable for treating patients with multifocal liver metastasis due to lobar administration of the embolic materials. During conventional TACE chemotherapy drugs are administered with ethiodized oil, while in TACE, with drug-eluting beads, the chemotherapy drug is loaded into embolization microparticles.¹³ TARE involves lobar or segmental intra-arterial administration of microspheres loaded with the high energy beta ray emitting yttrium-90 (Y90) isotope.¹⁴

In the last 13 years, multiple retrospective studies have addressed the effectiveness and safety of TARE with Y90 microspheres in patients with breast cancer liver metastases (Table 1).¹⁵⁻²⁹ Although there is a lack of randomized prospective trials and the overall number of patients in the published retrospective studies was relatively low, TARE is now considered a safe and effective palliative liver-directed therapy to control hepatic tumor progression and improve survival. A meta-analysis of 12 studies published between 2007 and 2018 reported an estimated mean survival of 11.3 months in patients with metastatic breast cancer treated with TARE.³⁰

There are 2 Y90-labeled microspheres available for radioembolization with different physical characteristics and activity calculation models.¹⁴ Most of the prior studies included patients treated with Y90-labeled resin microspheres or included patients treated with either Y90-labeled resin or glass microspheres. Most of these studies demonstrated median overall survival (OS) between 8 and 15 months (Table 1). The only study that included patients exclusively treated with Y90-labeled glass microspheres reported a limited median OS of 6.6 months.²²

Table 1 Prior studies on radioembolization of breast cancer liver metastases

Reference	Year	Number of patients	Mean age (years)	Microsphere	Median OS (months)
Coldwell et al ¹⁵	2007	44	58	Resin	Not reported
Bangash et al ¹⁶	2007	27	52	Glass	6.8 (ECOG 0) 2.6 (ECOG 1-3)
Stuart et al ¹⁷	2008	7	N/A	Resin	11.9*
Jakobs et al ¹⁸	2008	30	58	Resin	9.6
Haug et al ¹⁹	2012	58	58	Resin	10.8
Cianni et al ²⁰	2013	52	57.5	Resin	11.5
Saxena et al ²¹	2014	40	54.4	Resin	13.6
Gordon et al ²²	2014	75	53.7	Glass	6.6
Bagni et al ²³	2015	17	59.2	Resin	13.5
Fendler et al ²⁴	2016	81	61	Resin	8
Pieper et al ²⁵	2016	44	56.1	Resin and glass	6
Deipolyi et al ²⁶	2018	31	52	Resin and glass	11
Chang et al ²⁷	2018	30	55	Resin and glass	12.9
Deipolyi et al ²⁸	2020	30	51.5	Resin and glass	15
Davison et al ¹³	2020	24	57	Resin and glass	35.4
Cheng et al ²⁹	2020	20	62	Resin	14.3

Abbreviations: ECOG = Eastern Cooperative Oncology Group; OS = overall survival.
* Mean OS; median OS not reached.

The purpose of this study was to evaluate the safety and efficacy of TARE using Y90-labeled glass microspheres in patients with liver-dominant chemotherapy-refractory breast cancer liver metastases.

Methods and Materials

Patients

This was an institutional review board–approved, single institution, retrospective study. Review of our institution's electronic medical records and imaging system identified 31 eligible female patients with breast cancer with chemotherapy-refractory hepatic metastases who underwent TARE using glass microspheres (TheraSphere; Boston Scientific, Marlborough, MA) between May 2010 and August 2019. All patients had hepatic tumor progression after systemic chemotherapy. Seventeen patients received 1 prior line chemotherapy, 12 patients got 2 lines of chemotherapy, 1 patient received 3 lines, and 1 patient received 9 lines of chemotherapy. Patients were selected for TARE by a multidisciplinary tumor board. Criteria for receiving TARE treatment included liver-dominant metastases that progressed on at least 1 line of chemotherapy, Eastern Cooperative Oncology Group (ECOG) performance status of ≤ 2 , total serum bilirubin ≤ 2 mg/dL, serum creatinine ≤ 2 mg/dL, and international normalized ratio and platelet count correctable to ≤ 1.5 and $\geq 50,000/\mu\text{L}$, respectively. Liver-dominant disease was defined when the liver involvement was likely the survival limiting factor for the patient.

Patient demographics are summarized in Table 2. The study included 31 females with a mean age of 59.6 ± 13.2 years. Bilobar disease was present in 22 patients and the receptor status for estrogen receptor (ER), progesterone receptor (PR), and human epidermal growth factor receptor-2 (Her-2) was positive in 25, 21, and 5 cases, respectively. Three triple-negative and 4 triple-positive patients were included in the current study. Extrahepatic metastases were present in 21 patients, and 13 of them had metastases in bones only besides the liver. Five patients received other liver-directed treatments before TARE, which included surgical resection in 2 patients and external radiation therapy in 3 patients. Eight patients underwent other liver directed treatments after the TARE, which included bland embolization in 2 patients, repeated TARE in 2 patients, TACE in 2 patients, and percutaneous ablation in 2 patients. The median follow-up period between the first TARE and the date of last visit/death was 12 months (range, 2-44 months).

Radioembolization procedure

Planning angiogram and TARE were performed, and outcomes are reported according to the Society of

Table 2 Demographic characteristics of patients

	n	%
Age in years (mean \pm standard deviation)		
	65.5 \pm 11.2	
Sex		
Male	0	0
Female	31	100
ECOG		
0	10	32.3
1	18	58.1
2	2	6.5
3	1	3.2
Distribution of hepatic metastases		
Unilobar	9	29
Bilobar	22	71
Genetic markers		
ER+	25	80.6
PR+	21	67.7
Her-2+	5	16.1
Extrahepatic metastasis		
No	10	32.3
Yes	21	67.7
Bone only	12	38.7
Extraosseous \pm bone	9	29.0
Previous chemotherapy		
Yes	31	100
No	0	0
Previous liver-directed therapy		
Yes	5	16.1
No	26	83.9
Liver-directed therapy after TARE		
Yes	8	25.8
No	23	74.2

Abbreviations: ECOG = Eastern Cooperative Oncology Group; ER = estrogen receptor; Her-2 = human epidermal growth factor receptor 2; PR = progesterone receptor; TARE = transarterial radioembolization.

Interventional Radiology guidelines.³¹ All patients underwent planning angiogram 1 to 3 weeks before TARE to evaluate tumor-feeding vessels and anatomic variants, and technetium-99m macroaggregated albumin was injected into the hepatic arteries to determine lung shunt fraction measured by scintigraphy immediately after the angiogram. Calculation of the prescribed activity was performed in compliance with international consensus guidelines using the medical internal radiation dose equation as provided by the manufacturer of Y90-glass microspheres.³² In patients who had bilobar disease the left and right lobes were treated separately, approximately 4 to 7 weeks apart.

Clinical outcome measures

OS was calculated from the date of the first TARE treatment to last encounter or death. Survival probabilities

were calculated for 1-, 2-, and 3-year time points. Clinical and laboratory toxicities were assessed at 3-month follow-up after the TARE. Clinical toxicity was defined as subjective reporting by the patient of pain, fatigue, gastrointestinal symptoms (anorexia, nausea, vomiting), or other. Toxicities were defined according to the Common Terminology Criteria for Adverse Events scoring system (version 5.0). Model for end-stage liver disease (MELD) scores were calculated to assess postembolization liver toxicity. Tumor response was evaluated at 3 months after the TARE using Response Evaluation Criteria in Solid Tumors (RECIST 1.1).³³

Statistical analysis

Statistical analysis was performed with IBM SPSS Statistics version 25 (IBM Corporation, Armonk, NY). Data are presented as mean \pm standard deviation. The probabilities of actuarial OS and HPFS were calculated by the Kaplan-Meier method with the last date of contact or death used for censoring. The log-rank test was used to evaluate the effect of clinical factors and patient characteristics on disease outcome. A *P* value of .05 was taken as significant.

Results

Radioembolization treatment

The mean time from the diagnosis of liver metastasis to the TARE treatment was 27.3 ± 20.3 months (median, 20.1 months). Nineteen patients had bilobar treatment, 10 patients had unilobar treatment, and 2 patients had segmental TARE. The average delivered dose to the treated liver volume was 172.2 ± 115.4 Gy, and the median delivered dose was 129.3 Gy (range, 92.3-717.6 Gy). The average lung shunt was $4.46 \pm 0.02\%$ (median, 3.9%).

Survival outcomes

At the time of data analysis 8 patients were still alive and 23 were deceased. The median OS from the date of TARE was 13 months (95% confidence interval [CI], 9.1-16.9 months) (Fig 1A). The 1-, 2-, and 3-year survival probability was 60.1%, 36.7%, and 24.5%, respectively. The median hepatic progression-free survival (HPFS) was 7 months (95% CI, 6.1-7.9 months) (Fig 1B).

Median OS for patients with ER+ tumors was significantly higher compared with ER- patients (14 vs 9 months, *P* = .028) (Fig 2A). Patients with PR+ tumors had longer median OS compared with patients with PR-

tumors, but the difference was not statistically significant (14 vs 9 months, *P* = .24) (Fig 2B). The Her-2 status of the tumor had no effect on survival; however, only 5 patients had Her-2 positive tumors (Table 3). Patients with unilobar disease had a longer OS of 30 months compared with 12 months in patients with bilobar disease; however, the difference was not statistically significant (*P* = .28) (Table 3). There was no significant difference in median OS of patients without or with extrahepatic metastases (14 vs 12 months, *P* = .22) (Fig 3A). However, patients with bone-only extrahepatic disease had longer median OS than patients having other extrahepatic metastases (23 vs 8 months, *P* = .02) (Fig 3B).

There was no significant correlation between median OS and baseline ECOG performance status (*P* = .09), albumin-bilirubin score (*P* = .9), and MELD score (*P* = .12) (Table 2). There was no difference in median OS when comparing patients who had decreased cancer antigen 15-3 (CA15-3) after TARE to patients who had increased CA15-3 after TARE (Table 3). Patients who received liver-directed therapy after TARE had significantly longer median OS than patients who did not receive any liver-directed therapy after TARE (30 vs 12 months, *P* = .049) (Table 3).

Radiographic tumor response

Baseline and follow-up contrast-enhanced cross-sectional imaging were available for 30 patients (96.7%). The radiographic responses at 3 months were evaluated by RECIST criteria, which showed complete response in 1 patient (3.3%), partial response in 13 patients (43.3%), stable disease in 7 patients (23.3%), and progressive disease in 9 patients (30%) with objective response rate (complete and partial response) of 46.6% and disease control rate (complete and partial response plus stable disease) of 70%. There was no difference in median OS between patients who had objective response after TARE and patients who did not (Table 3).

Clinical and biochemical toxicities

After TARE the 30-day mortality was 0%. Grade 3 clinical toxicity was noted in 3 patients (9.4%), necessitating hospitalization for pain (2 patients), and newly developed ascites required paracentesis in 1 patient. Laboratory values at the 3-month follow-up were available in 29 of the 31 patients: 1 patient died 2 months after the first treatment and another patient's follow-up was done at an outside institution and laboratory data were not available. Mild (grade 1-2) biochemical toxicities were noted in 24 patients. Alkaline phosphatase was elevated in 18 patients, albumin level was below normal in 7 patients, and bilirubin level was elevated in 1 patient at 3-month follow-up. No grade 3 or

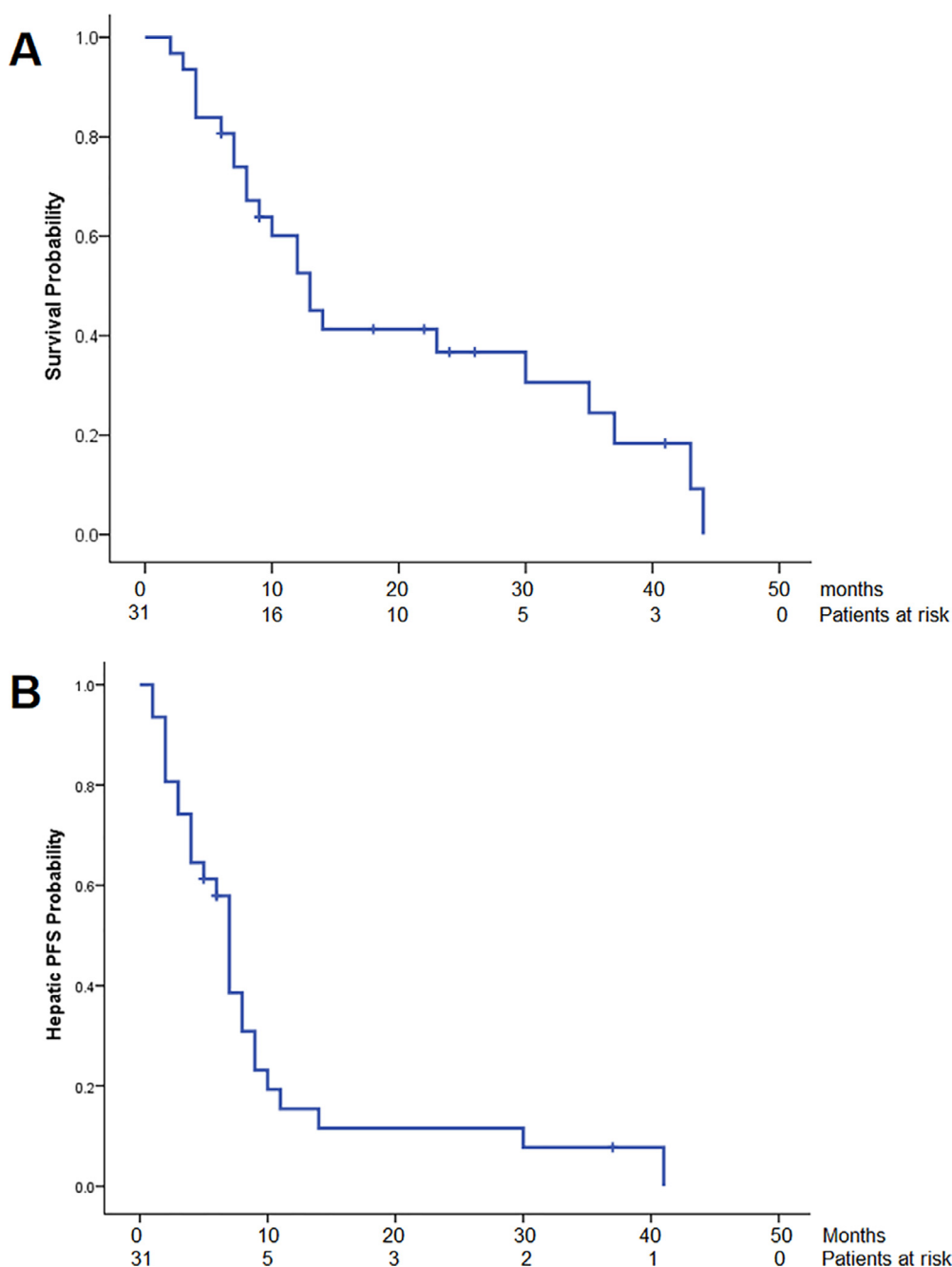


Fig. 1 Overall survival (OS) and hepatic progression-free survival from radioembolization treatment. (A) Median OS from the radioembolization treatment was 13 months (95% confidence interval [CI], 9.1-16.9 months). (B) Hepatic progression-free survival from the radioembolization treatment was 7 months (95% CI, 6.1-7.9 months).

higher biochemical toxicities were detected. The MELD score at 3 months was not significantly different compared with baseline (6.84 ± 1.68 vs 6.96 ± 1.61 , $P = .45$).

Discussion

The treatment of chemotherapy-resistant breast cancer liver metastasis is challenging, and different liver-directed therapies were tried in this setting. One of the largest

studies included 176 patients with chemotherapy-resistant breast cancer liver metastasis who underwent intra-arterial hepatic infusion of mitomycin C.³⁴ The study reported 7.6 months median OS and 17.5% severe, grade 3 or 4, adverse events.³⁴

Liver-directed embolization therapies like TACE and TARE are increasingly popular treatment choices in patients with chemotherapy-refractory breast cancer with unresectable liver-dominant metastases. The study of Li et al³⁵ reported significantly improved survival of patients

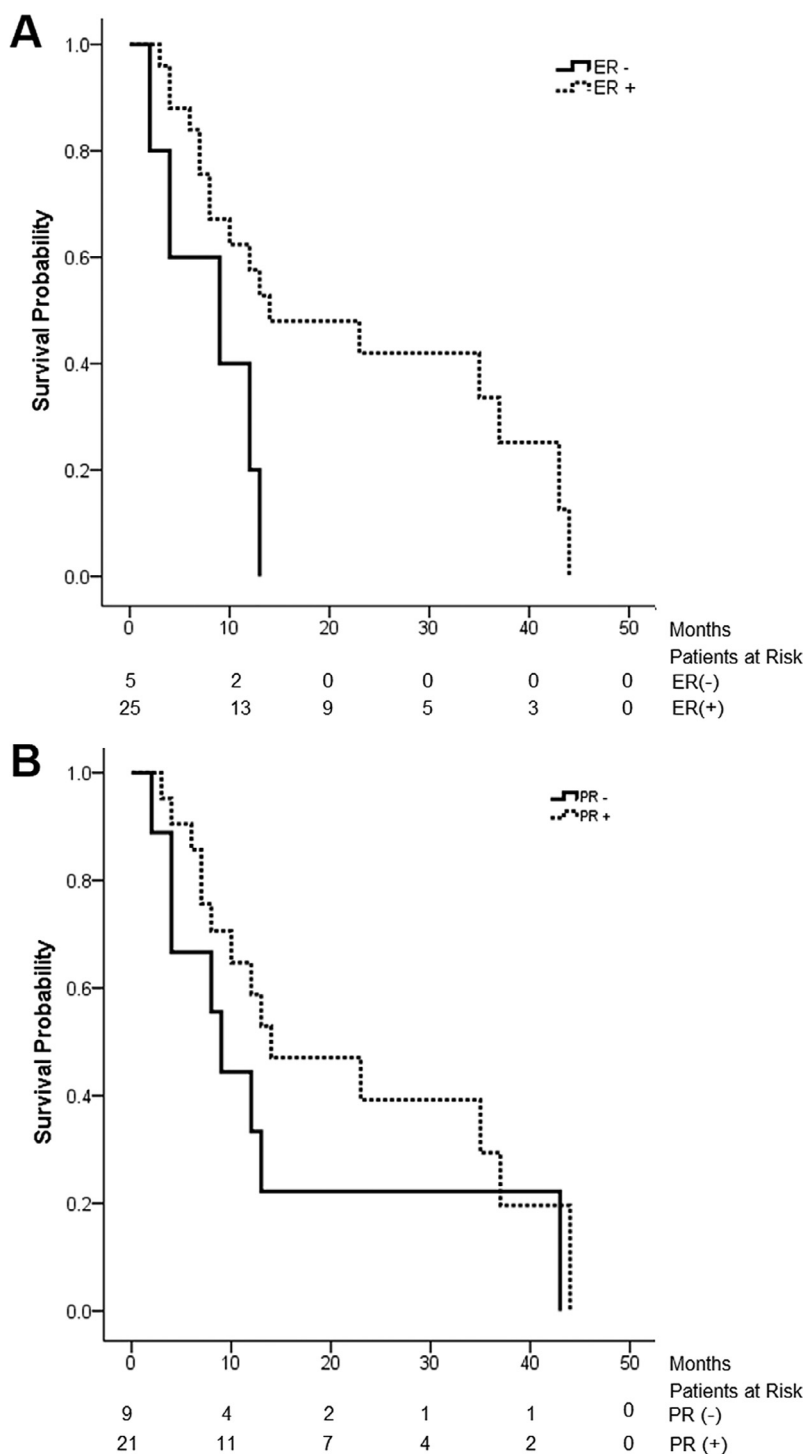


Fig. 2 The effect of hormone receptor status on overall survival (OS) after radioembolization treatment. (A) Median OS of patients with estrogen receptor positive (ER+) versus negative (ER-) status (14 vs 9 months; $P = .028$). (B) Median OS of patients with progesterone receptor positive (PR+) versus negative (PR-) status (14 vs 9 months; $P = .23$).

treated with TACE compared with systemic chemotherapy; the 1-, 2- and 3-year survival rates were 63.04%, 30.35%, and 13.01% for TACE and 33.88%, 11.29%, and 0% for systemic chemotherapy. TARE is generally better tolerated by patients than TACE. TARE was associated with better quality-of-life scores compared with TACE in

patients with hepatocellular carcinoma.³⁶ In a retrospective comparative study, Chang et al²⁷ reported fewer side effects in patients with breast cancer treated with TARE compared with TACE and also demonstrated a numerical trend for longer survival after TARE compared with TACE (12.9 vs 4.6 months), but the difference in survival

Table 3 Univariate analysis between variables and overall survival

Variables (n)	Log rank analysis		
	Median survival (months)	95% CI	P value
Age			
<60 years (15)	10	6, 14	.3
>60 years (16)	23	7, 37	
ECOG			
0 and 1 (28)	13	9, 37	.22
2 and 3 (3)	4	4, 35	
Distribution of hepatic metastases			
Unilobar (9)	30	4, 43	.28
Bilobar (22)	12	7, 23	
ER status			
ER+ (25)	14	8, 37	.028
ER- (5)	9	2, 13	
PR status			
PR+ (21)	14	8, 37	.23
PR- (9)	9	2, 43	
Her-2 status			
Her-+ (5)	14	9, 43	.7
Her-2- (24)	12	7, 37	
Extrahepatic metastases			
No (10)	14	4, 44	.22
Yes (21)	12	7, 30	
Extrahepatic extraosseous metastases			
No (12)	23	7, 37	.02
Yes (9)	8	3, 12	
Previous liver-directed therapy			
Yes (5)	12	7, 37	.8
No (26)	23	7, 30	
Liver-directed therapy after TARE			
Yes (8)	12	7, 14	.05
No (23)	30	4, 44	
Radiographic (RECIST) objective response			
Yes (14)	12	7, 43	.8
No (16)	13	6, 30	

Abbreviations: CI = confidence interval; ECOG = Eastern Cooperative Oncology Group; ER = estrogen receptor; Her-2 = human epidermal growth factor receptor 2; PR = progesterone receptor; RECIST = Response Evaluation Criteria in Solid Tumors; TARE = transarterial radioembolization.

was not statistically significant. Several studies reported TARE treatment of patients with metastatic breast cancer with median OS ranged from 6 to 35.4 months.¹⁵⁻²⁹ Although data from these studies should be interpreted with caution due to the retrospective nature and heterogeneity of the methodology in the reports, most studies reported median OS of 10 months or longer from time of TARE, and the treatment had minimal toxicity (Table 1).¹⁵⁻²⁹ These median OS values are respectable in

these heavily pretreated patients who had liver progression despite receiving systemic chemotherapy. On the other hand, the only study where Y90-labeled glass microspheres were used reported median OS of only 6.6 months.²²

The current study on 31 patients with breast cancer with unresectable, chemotherapy-refractory liver metastases who underwent TARE with Y90-labeled glass microspheres demonstrated a median OS of 13 months and a HPFS of 7 months. These survival data are comparable to those reported in previous studies using Y90-labeled resin or a combination of resin and glass microspheres (Table 1).^{13,15-21,23-29} However, our results are different than the largest study on Y90-labeled glass microspheres where 75 patients with breast cancer were treated and reported 6.6 months median OS.²² Their 30-day mortality was also higher at 4% and grade 3 to 4 clinical toxicity was 7.5%. The significant discrepancy in median OS in comparison to the current study may be related to the differences in patient selection. Gordon et al²² included patients with life expectancy of more than 2 months, while in our institution, patients with life expectancy of less than 6 months are not eligible for TARE. There were also 3 patients who died within 30 days after TARE in the study of Gordon et al, which is an unusually high 30-day mortality in a TARE study. In the current study, there was no 30-day mortality and the incidence of severe, grade 3 or 4, adverse events was 9.4%, comparable to other TARE studies in patients with breast cancer.^{13,17,26} The 3 patients who developed grade 3 toxicity received bilobar treatment, which is a prognostic factor for adverse events.³⁷ It should also be noted that treatment with TARE showed evidence of antitumor efficacy as illustrated by a 3-month objective response rate of 46.6%, and 1 patient had complete clinical response. The median OS and toxicity numbers compare favorably to intra-arterial hepatic infusion therapy with reported 7.6 months median OS and 17.5% severe adverse events.³⁴ Notwithstanding the lack of correlation between tumor response and improvement in OS, patients in imminent visceral crisis from progression of liver disease should be considered for TARE.

There were several factors that were associated with longer survival after TARE. Our study confirmed the results of Davisson et al,¹³ who demonstrated that ER+ status is a positive predictor for prolonged survival, while PR and Her-2 status had no significant effect. Patients with unilobar disease had longer median OS than patients with bilobar disease, but this difference didn't reach statistical significance, likely due to low number of patients. Similar to the study by Davisson et al,¹³ radiographic response measured by RECIST had no predictive value for survival; there was no difference in the median OS of patients who had objective response and those who did not. This can be explained by the fact that the disease control rate was high (70%). In addition, RECIST could have underestimated true response because it is an anatomic measurement. Deipolyi et al²⁶ reported a correlation

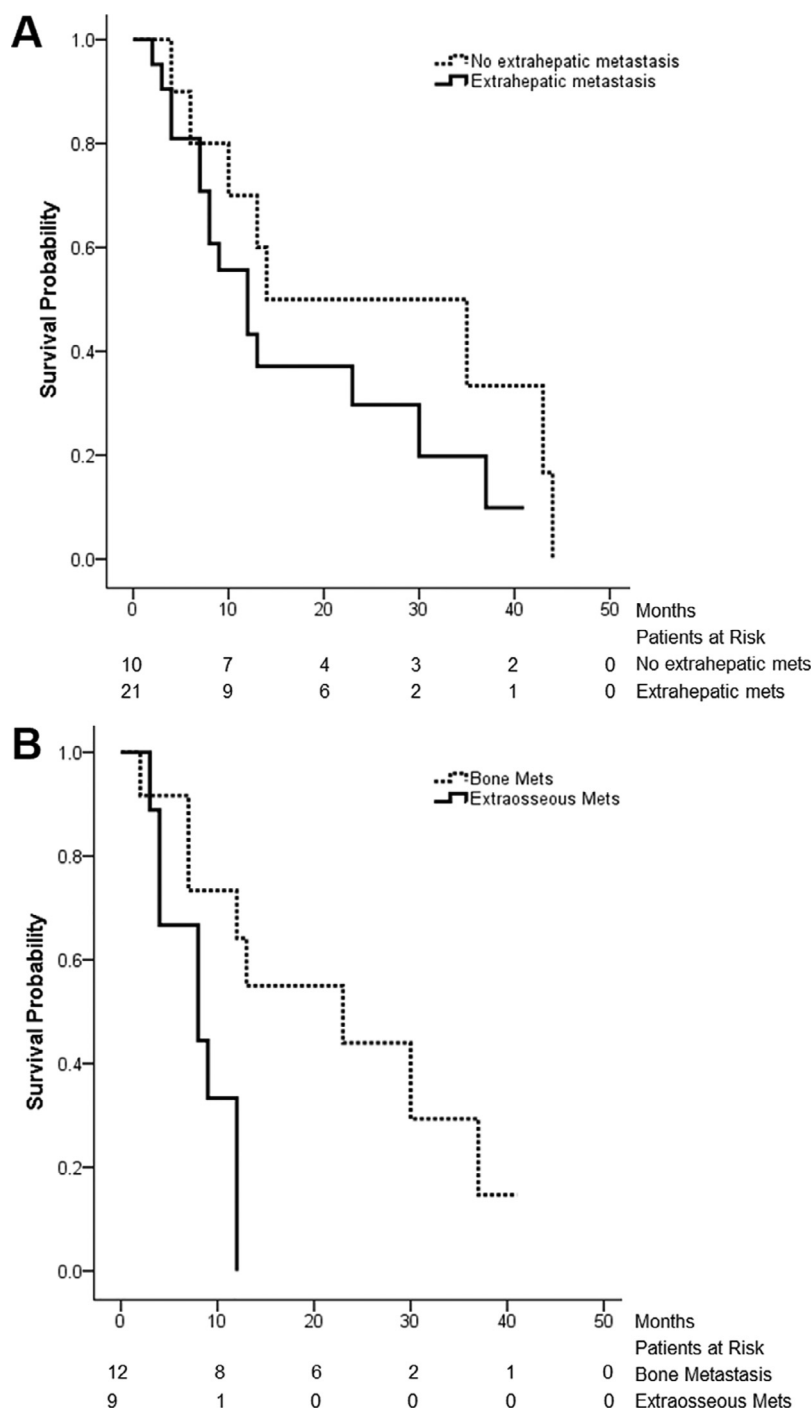


Fig. 3 The effect of extrahepatic metastatic disease on overall survival (OS). (A) Median OS of patients without and with extrahepatic metastasis (14 vs 12 months; $P = .22$). (B) Median OS of patients with bone-only extrahepatic metastasis and patients with extrahepatic extraosseous metastasis (23 vs 9 months; $P = .02$).

between imaging response and survival in patients with breast cancer treated with Y90-labeled resin microspheres, but in that study positron emission tomography-computed tomography was used to evaluate tumor response.

Several studies that evaluated the role of TARE in the treatment of liver metastases showed correlation between patients’ performance status and survival. In the current

patient cohort, 28 patients (90%) had ECOG 0 or 1 performance status; therefore, statistical correlation could not be found. Davisson et al¹³ also reported that radioembolization within 6 months of hepatic metastasis diagnosis is a positive predictor of prolonged survival. In the current study, the median time from diagnosis of liver metastasis to TARE was 20.1 months and only 2 patients (6%)

received TARE within 6 months of liver metastasis diagnosis, while in the study of Davisson et al 10 patients (42%) underwent TARE within 6 months after the liver metastasis diagnosis. These data highlight the differences in patient selection among institutions and may explain the excellent post-TARE median OS of 35.4 months in the study of Davisson et al.¹³

Interestingly, the current study showed that patients who received other liver-directed therapy after TARE had longer median OS than patients who did not. This could be explained by survivorship bias; patients who were able to receive additional liver-directed therapy later in the course of the disease could have a slower progressing disease. There was no significant difference in OS between patients with and without extrahepatic disease. However, patients who had bone-only extrahepatic disease had higher OS (23 months) than patients having other extrahepatic disease (8 months), including patients having simultaneous bone and extraskeletal metastases. This is in line with the fact that bone metastases are rarely the cause of mortality in patients with breast cancer.

The present study has several limitations. This is a retrospective, single institution study without a control group. Criteria for TARE treatment could vary between our institution and others, as decisions are made by a multidisciplinary tumor board regarding the best available treatment. Therefore, selection bias may have skewed the results. The study did not account for differences in pre- or posttreatment chemotherapy and other treatments, which may represent a confounding bias, in addition to other factors such as menopausal status and comorbid conditions that may have contributed to the disease outcome. Lastly, the small number of patients does not allow identification of all the prognostic factors that may influence survival.

In conclusion, TARE using Y90-labeled glass microspheres has a favorable toxicity profile and provided 70% hepatic disease control rate in patients with breast cancer with liver-dominant chemotherapy-refractory metastases. ER+ status and lack of extrahepatic extraosseous metastasis were associated with longer median OS. The results of the current study with Y90-labeled glass microspheres are similar to previously published results with Y90-labeled resin microspheres. A future prospective randomized trial is warranted to confirm efficacy of radioembolization treatment and to identify prognostic factors that influence survival in patients with breast cancer with liver-dominant chemotherapy-refractory metastases.

References

1. Siegel RL, Miller KD, Jemal A. Cancer statistics, 2019. *CA Cancer J Clin.* 2019;69:7–34.
2. Siegel R, Naishadham D, Jemal A. Cancer statistics, 2013. *CA Cancer J Clin.* 2013;63:11–30.
3. Brewster AM, Hortobagyi GN, Broglio KR, et al. Residual risk of breast cancer recurrence 5 years after adjuvant therapy. *J Natl Cancer Inst.* 2008;100:1179–1183.
4. Hoe AL, Royle GT, Taylor I. Breast liver metastases—incidence, diagnosis and outcome. *J R Soc Med.* 1991;84:714–716.
5. Zinser JW, Hortobagyi GN, Buzdar AU, Smith TL, Fraschini G. Clinical course of breast cancer patients with liver metastases. *J Clin Oncol.* 1987;5:773–782.
6. Weigelt B, Peterse JL, van 't Veer LJ. Breast cancer metastasis: Markers and models. *Nat Rev Cancer.* 2005;5:591–602.
7. Chua TC, Saxena A, Liauw W, Chu F, Morris DL. Hepatic resection for metastatic breast cancer: A systematic review. *Eur J Cancer.* 2011;47:2282–2290.
8. Adam R, Chiche L, Aloia T, et al. Hepatic resection for noncolorectal nonendocrine liver metastases. *Ann Surg.* 2006;244:524–535.
9. Hoffmann K, Franz C, Hinz U, et al. Liver resection for multimodal treatment of breast cancer metastases: Identification of prognostic factors. *Ann Surg Oncol.* 2010;17:1546–1554.
10. Liberchuk AN, Deipolyi AR. Hepatic metastasis from breast cancer. *Semin Intervent Radiol.* 2020;37:518–526.
11. Kucharczyk MJ, Parpia S, Walker-Dilks C, Banfield L, Swaminath A. Ablative therapies in metastatic breast cancer: A systematic review. *Breast Cancer Res Treat.* 2017;164:13–25.
12. Xiao YB, Zhang B, Wu YL. Radiofrequency ablation versus hepatic resection for breast cancer liver metastasis: A systematic review and meta-analysis. *J Zhejiang Univ Sci B.* 2018;19:829–843.
13. Davisson NA, Bercu ZL, Friend SC, et al. Predictors of survival after yttrium-90 radioembolization of chemotherapy-refractory hepatic metastases from breast cancer. *J Vasc Interv Radiol.* 2020;31:925–933.
14. Kis B, El-Haddad G, Sheth RA, et al. Liver-directed therapies for hepatocellular carcinoma and intrahepatic cholangiocarcinoma. *Cancer Control.* 2017;24:1073274817729244.
15. Coldwell DM, Kennedy AS, Nutting CW. Use of yttrium-90 microspheres in the treatment of unresectable hepatic metastases from breast cancer. *Int J Radiat Oncol Biol Phys.* 2007;69:800–804.
16. Bangash AK, Atassi B, Kaklamani V, et al. 90Y radioembolization of metastatic breast cancer to the liver: Toxicity, imaging response, survival. *J Vasc Interv Radiol.* 2007;18:621–628.
17. Stuart JE, Tan B, Myerson RJ, et al. Salvage radioembolization of liver-dominant metastases with a resin-based microsphere: Initial outcomes. *J Vasc Interv Radiol.* 2008;19:1427–1433.
18. Jakobs TF, Hoffmann R-T, Fischer T, et al. Radioembolization in patients with hepatic metastases from breast cancer. *J Vasc Interv Radiol.* 2008;19:683–960.
19. Haug AR, Tiega Donfack BP, Trumm C, et al. 18F-FDG PET/CT predicts survival after radioembolization of hepatic metastases from breast cancer. *J Nucl Med.* 2012;53:371–377.
20. Cianni R, Pelle G, Notarianni E, et al. Radioembolisation with (90)Y-labelled resin microspheres in the treatment of liver metastasis from breast cancer. *Eur Radiol.* 2013;23:182–189.
21. Saxena A, Kapoor J, Meteling B, Morris DL, Bester L. Yttrium-90 radioembolization for unresectable, chemoresistant breast cancer liver metastases: A large single-center experience of 40 patients. *Ann Surg Oncol.* 2014;21:1296–1303.
22. Gordon AC, Gradishar WJ, Kaklamani VG, et al. Yttrium-90 radioembolization stops progression of targeted breast cancer liver metastases after failed chemotherapy. *J Vasc Interv Radiol.* 2014;25:1523–1532.
23. Bagni O, Filippi L, Pelle G, Cianni R, Schillaci O. Total lesion glycolysis and sequential (90)Y-selective internal radiation therapy in breast cancer liver metastases: Preliminary results. *Cancer Biother Radiopharm.* 2015;30:421–426.
24. Fendler WP, Lechner H, Todica A, et al. Safety, efficacy, and prognostic factors after radioembolization of hepatic metastases from breast cancer: A large single-center experience in 81 patients. *J Nucl Med.* 2016;57:517–523.

25. Pieper CC, Meyer C, Wilhelm KE, et al. Yttrium-90 radioembolization of advanced, unresectable breast cancer liver metastases—a single-center experience. *J Vasc Interv Radiol*. 2016;27:1305–1315.
26. Deipolyi AR, Riedl C, Bromberg J, et al. Association of PI3K pathway mutations with early PET/CT imaging response after radioembolization for breast cancer liver metastases: Results of a single center retrospective pilot study. *J Vasc Interv Radiol*. 2018;29:1226–1235.
27. Chang J, Charalel R, Noda C, et al. Liver-dominant breast cancer metastasis: A comparative outcomes study of chemoembolization versus radioembolization. *Anticancer Res*. 2018;38:3063–3068.
28. Deipolyi AR, England RW, Ridouani F, et al. PET/CT imaging characteristics after radioembolization of hepatic metastasis from breast cancer. *Cardiovasc Intervent Radiol*. 2020;43:488–494.
29. Cheng B, Sethi I, Davisson N, et al. Yttrium-90 dosimetry and implications on tumour response and survival after radioembolisation of chemo-refractory hepatic metastases from breast cancer. *Nucl Med Commun*. 2021;42:402–409.
30. Feretis M, Solodkyy A. Yttrium-90 radioembolization for unresectable hepatic metastases of breast cancer: A systematic review. *World J Gastrointest Oncol*. 2020;12:228–236.
31. Salem R, Lewandowski RJ, Gates VL, et al. Research reporting standards for radioembolization of hepatic malignancies. *J Vasc Interv Radiol*. 2011;22:265–278.
32. Kennedy A, Nag S, Salem R, et al. Recommendations for radioembolization of hepatic malignancies using yttrium-90 microsphere brachytherapy: A consensus panel report from the radioembolization brachytherapy oncology consortium. *Int J Radiat Oncol Biol Phys*. 2007;68:13–23.
33. Eisenhauer EA, Therasse P, Bogaerts J, et al. New response evaluation criteria in solid tumours: Revised RECIST guideline (version 1.1). *Eur J Cancer*. 2009;45:28–247.
34. Aarts BM, Klompenhouwer EG, Dresen RC, et al. Intra-arterial mitomycin C infusion in a large cohort of advanced liver metastatic breast cancer patients: Safety, efficacy and factors influencing survival. *Breast Cancer Res Treat*. 2019;176:597–605.
35. Li X-P, Meng Z-Q, Guo W-J, Li J. Treatment for liver metastases from breast cancer: Results and prognostic factors. *World J Gastroenterol*. 2005;11:3782–3787.
36. Salem R, Gilbertsen M, Butt Z, et al. Increased quality of life among hepatocellular carcinoma patients treated with radioembolization, compared with chemoembolization. *Clin Gastroenterol Hepatol*. 2013;11:1358–1365.
37. Spina JC, Hume I, Pelaez A, Peralta O, Quadrelli M, Garcia Monaco R. Expected and unexpected imaging findings after 90Y transarterial radioembolization for liver tumors. *Radiographics*. 2019;39:578–595.