

Emergency craniotomy in Glanzmann thrombasthenia: Anesthetic management and brief review of literature

Sir,

Glanzmann thrombasthenia (GT) is a rare autosomal recessive disorder of platelet function with complete or partial lack of platelet aggregation due to defect in glycoprotein IIb/IIIa receptor on platelet surface. These patients are at risk of excessive bleeding during surgery, invasive procedures, or from trauma, which may be life-threatening if it occurs in closed spaces. Trauma may itself lead to coagulopathy, resulting in altered laboratory results, thus making intraoperative coagulation assessment difficult. An anesthesiologist must be aware of risk of excessive bleeding and should take extra precautions intraoperatively. We report a case of 16-year-old female with GT, who sustained traumatic brain injury and underwent emergency decompressive craniotomy. The anesthetic concerns and brief review of literature have been discussed.

A 16-year-old female patient presented to emergency department (ED) with history of fall. On the primary

survey, her Glasgow Coma Scale (GCS) score was 15 (eye opening = 4, verbal response = 5, and motor response = 6); however, subsequently, the patient's GCS deteriorated to 10. The trachea was intubated in ED with 7.0 mm cuffed endotracheal tube in view of rapidly deteriorating GCS. On eliciting history from parents and reviewing the previous medical records, it was revealed that the patient was a diagnosed case of GT since the age of 3 years. She was treated with tranexamic acid during acute bleeding episodes. Noncontrast computed tomography of the head showed frontal subdural hemorrhage and diffuse subarachnoid hemorrhage with midline shift of 6 mm. The patient was shifted to the Intensive Care Unit (ICU) for intracranial pressure (ICP) monitoring and further care. However, in view of increasing ICP and poor GCS, the patient was shifted to operation theater (OT) for decompressive craniotomy within 3 h of admission.

Patient's laboratory blood investigations showed prothrombin time (PT) 13.6 s with international normalized ratio 0.99, activated partial thromboplastin time (APTT) 24.2 s, and platelet count $102 \times 10^3/\text{cmm}$. Six units of platelet concentrate was transfused to the patient prior surgery. After applying standard monitors and confirming the position of endotracheal tube, general anesthesia was induced with injection fentanyl and propofol, and neuromuscular blockade

was achieved with injection vecuronium. Right internal jugular vein was cannulated with triple lumen central venous catheter with ultrasound guidance, and arterial line was inserted in the left radial artery. Cell saver was used intraoperatively. Intraoperative blood loss was 1.2 L, without any episode of incessant bleeding. Intraoperatively, two packed red blood cells and 600 ml of cell saver blood were transfused. Tranexamic acid 1 g intravenous (IV) was administered before the commencement of surgery followed by 1 g infusion over 8 h. Intraoperative thromboelastography (TEG) of the patient showed decreased α angle 33.5 (normal 44.5-66.5°) but increased maximum amplitude (MA) of 105 mm (normal 30-70 mm) Based on the TEG report, six units of cryoprecipitate and four units of fresh frozen plasma were arranged and transfused postoperatively. The trachea was not extubated in view of poor GCS, and the patient was transferred to ICU for postoperative mechanical ventilation. In ICU, all measures were taken to decrease the ICP by giving head up position, administering diuretics and achieving neuromuscular paralysis. Postoperative TEG revealed normal values of α angle and MA. Repeat CT scan done on day 2 did not show any evidence of rebleed. The patient developed severe cerebral edema on 3rd postoperative day. All medical measures to treat edema failed and the patient expired on the 4th day.

GT is a rare platelet disorder with incidence of 1 in 10×10^5 , with sparse literature available on the perioperative management, especially in emergency trauma situations. To the best of our knowledge, only one case of GT posted for emergency surgery has been reported till date.^[1] Since the disease is usually diagnosed in childhood, patient receives multiple blood transfusions till the second decade of life. This causes development of human platelet antigen (HPA)-1a antibodies, making platelet transfusion a less efficacious approach. The anesthesiologist thus faces a major challenge in controlling the intraoperative bleeding.

Perioperative hematological evaluation is important in guiding the transfusion therapy in these patients. Coagulation parameters such as total platelet count, PT, and APTT are normal in these patients as in our case. As GT is a functional defect of platelet, platelet function monitoring is a better diagnostic test. Bleeding time (BT), platelet aggregometry, and TEG are a few investigations used to monitor platelet function. Uzunlar *et al.* used BT alone to monitor treatment response after platelet transfusion and rFVIIa therapy.^[1] As BT is affected by various confounding variables, it is not recommended to assess bleeding risk.^[2] TEG measures viscoelastic property of an evolving clot as a function of time. MA primarily gives information about platelet number

and function. Only two cases have been reported, wherein TEG was used to assess coagulation status intraoperatively in patients suffering from GT.^[3,4] In both the cases, there was low alpha angle with decreased MA. Our case showed normal reaction time, decreased alpha angle, and slightly higher than normal MA [Figure 1]. Platelet transfusion before being shifted to OT can explain the increased MA in our patient.

Patient with anti-HPA antibody shows variable response to platelet transfusion.^[3] In elective surgical settings, these patients should be evaluated for anti-HPA antibody. Single donor platelets or HLA-matched blood products are useful; however, they could not be arranged in our patient as she required urgent surgery. Among other treatment modalities, plasmapheresis and IV immunoglobulin are useful for patients with anti-HPA antibody.^[5]

Recombinant factor VIIa (rFVIIa) has been used in perioperative period to control bleeding in a GT patient undergoing emergency laparotomy.^[1] According to the European Society of Anaesthesiology guidelines, rFVIIa treatment should be considered in patients with GT undergoing surgery.^[6] We did not use rFVIIa since our patient responded well to platelet transfusion. Tranexamic acid helps to achieve hemostasis and is used in our patient with good results.

Ultrasound guidance for central venous cannulation, arterial cannulation for repeated blood gas analysis, and beat to beat blood pressure monitoring helps in optimal management of these patients.

Patients with GT are at risk of excessive bleeding during surgery or after trauma. Available therapeutic options are rFVIIa therapy and antifibrinolytics. Although rFVIIa is recommended as the first-line therapy for patients with GT

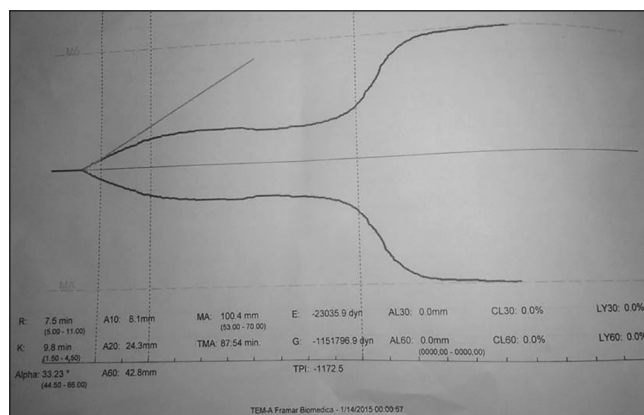


Figure 1: Thromboelastogram of the patient showing decreased α angle and normal maximum amplitude

undergoing surgery, its high cost compels to consider other treatment modalities. Administration of tranexamic acid was found to be a cheap and effective alternative to control bleeding in our patient. We re-emphasize the role of TEG to evaluate intraoperative bleeding risk, specifically in emergency cases.

Financial support and sponsorship

Nil.

Conflicts of interest

There are no conflicts of interest.

Devi Prasad Dash, Abhuday Kumar,

Babita Gupta¹

JPN Apex Trauma Center,
All India Institute of Medical Sciences,
¹Department of Anaesthesiology and Critical Care,
All India Institute of Medical Science,
New Delhi, India

Address for correspondence: Dr. Babita Gupta,
JPN Apex Trauma Center,
All India Institute of Medical Sciences,
New Delhi - 110 029, India.
E-mail: drbabitagupta@hotmail.com

References

1. Uzunlar HI, Eroglu A, Senel AC, Bostan H, Erciyes N. A patient with Glanzmann's thrombasthenia for emergent abdominal surgery. *Anesth Analg* 2004;99:1258-60.
2. Slaughter TF. Coagulation. In: Miller RD, editor. *Miller's Anesthesia*. 7th ed., Ch 56. California: Churchill Livingstone; 2010. p. 1767-80.
3. Monte S, Lyons G. Peripartum management of a patient with Glanzmann's thrombasthenia using Thrombelastograph. *Br J Anaesth* 2002;88:734-8.
4. Topal A, Kilicaslan A, Erol A, Cankaya BB, Otelcioğlu S. Anaesthetic management with thromboelastography in a patient with Glanzmann thrombasthenia. *Turk J Anaesthesiol Reanim* 2014;42:227-9.
5. Ito K, Yoshida H, Hatoyama H, Matsumoto H, Ban C, Mori T, *et al*. Antibody removal therapy used successfully at delivery of a pregnant patient with Glanzmann's thrombasthenia and multiple anti-platelet antibodies. *Vox Sang* 1991;61:40-6.
6. Kozek-Langenecker SA, Afshari A, Albaladejo P, Santullano CA, De Robertis E, Filipescu DC, *et al*. Management of severe perioperative bleeding: Guidelines from the European Society of Anaesthesiology. *Eur J Anaesthesiol* 2013;30: 270-382.

This is an open access article distributed under the terms of the Creative Commons Attribution-NonCommercial-ShareAlike 3.0 License, which allows others to remix, tweak, and build upon the work non-commercially, as long as the author is credited and the new creations are licensed under the identical terms.

Access this article online	
Quick Response Code:	Website: www.joacp.org
	DOI: 10.4103/0970-9185.194763

How to cite this article: Dash DP, Kumar A, Gupta B. Emergency craniotomy in Glanzmann thrombasthenia: Anesthetic management and brief review of literature. *J Anaesthesiol Clin Pharmacol* 2016;32:533-5.